





First report of urethroscrotal fistula in patients under 5 years of age presenting as recurrent scrotal swelling

Shirin Sayyahfar¹ , Mohammad Karbalaee² , Nazanin Sarejloo³ , Majid Karoobi³ 

Cite this article as: Sayyahfar S, Karbalaee M, Sarejloo N, Karoobi M. First report of urethroscrotal fistula in patients under 5 years of age presenting as recurrent scrotal swelling. Turk J Urol 2019; 45(5): 398-400.

ABSTRACT

Urethroscrotal fistula is a very rare pathology and is divided into congenital and acquired types. Herein we report a 4.5-year-old child with recurrent scrotal swelling and final diagnosis of urethroscrotal fistula. Clinicians should be aware and consider this disease in the differential diagnosis of any scrotal swelling, especially recurrent type. As far as we are aware, this is the first report of urethroscrotal fistula in patients under 5 years of age.

Keywords: Orchitis; pediatrics; scrotum; scrotal swelling; urethroscrotal fistula

Introduction

As a very rarely seen pathology, urethroscrotal fistula is an abnormal conduit between the urethra and the scrotum.^[1,2] It may be congenital or acquired secondary to infection, urethral stones, inflammatory diseases such as Crohn's disease, neoplasms, trauma and iatrogenic urogenital procedures.^[1-4]

Since rarely seen, it can be missed until recurrent scrotal swelling, orchitis or a scrotal abscess draw attention and persuade the clinician to perform further evaluations. Herein, we report an urethroscrotal fistula in a 4.5-year-old child who was evaluated after three episodes of scrotal swelling. As far as we are aware, this is the first report of a congenital urethroscrotal fistula in under-5-year-age group.

Case presentation

A 4.5-year-old male with scrotal swelling, erythema and primary diagnosis of acute orchitis was admitted into the pediatric infectious ward of Ali Asghar Children Hospital, Tehran, Iran. He was kept at an orphanage in Tehran from

infancy and the patient had cerebral palsy secondary to perinatal asphyxia. He had a medical history of urinary tract infection 2 years ago, and three episodes of hospitalization in different hospitals later on, with the diagnosis of orchitis without any known cause. At physical examination, the patient was bedridden and spastic and had severe failure to thrive. He was afebrile and the vital signs were within normal range at the time of admission. No abdominal tenderness was detected but the scrotum was red, engorged and tender. He was circumcised. The laboratory results at presentation were as follow: White blood cell (WBC) 19800/mm³ (neutrophil 62%, band 5%, lymphocyte 24%, and monocyte 9%), Hb 9.7 g/dL, mean corpuscular volume (MCV) 87 fL, platelet count 569000/mm³, erythrocyte sedimentation rate 55 mm/h, and C-reactive protein 59 mg/L. Blood culture was negative. Antibiotic therapy with intravenous clindamycin and ceftriaxone was started but 24-hours later the patient became restless and the size of the scrotum increased with exacerbation of tenderness. On palpation, tense and tender suprapubic area was felt. After insertion of a Foley catheter, the size of the scrotum decreased and the suprapubic area be-

ORCID IDs of the authors:

S.S. 0000-0002-7772-8353;
M.K. 0000-0002-6140-1014;
N.S. 0000-0003-2877-430X;
M.K. 0000-0003-0166-2375

¹Research Center of Pediatric Infectious diseases, Institute of Immunology and Infectious Diseases, Iran University of Medical Sciences, Tehran, Iran

²Department of Pediatric surgery, Hormozgan University of Medical Sciences, Bandar Abbas, Iran

³Iran University of Medical Sciences, Tehran, Iran

Submitted:

02.03.2018

Accepted:

23.07.2018

Available Online Date:

04.12.2018

Corresponding Author:

Shirin Sayyahfar

E-mail:

sayyahfar.sh@iums.ac.ir

©Copyright 2019 by Turkish Association of Urology

Available online at
www.turkishjournalofurology.com

came flat. We kept the catheter for 24-hours and the size of the scrotum was normal and the restlessness of the patient disappeared but as soon as the catheter was removed, the relationship scrotum enlarged again. This made us suspicious of a probable relationship between urinary system and scrotum.

Ultrasound of the scrotum revealed scrotal edema and a cystic collection (41×40 mm) containing septa and debris with compressive effect on the right testis. Doppler ultrasound revealed increased flow in the left testis compatible with orchitis. Abdominopelvic ultrasound was normal.

The results of the voiding cystourethrogram (VCUG) recommended by the surgery consult showed contrast material accumulation in the scrotum suggestive for an abnormal communication between lower urinary tract and scrotum (Figure 1). The diameter of the urethra was normal without obvious stricture or abnormality.

Preoperative evaluation of the external genitalia identified a painless scrotal mass extending to the base of the penis. The size of the mass reduced after insertion of an 8F Foley catheter into the urethra. Urethrocystoscopy was carried out under IV sedation to detect the internal orifice of the fistula. The urethral mucosa had a normal appearance during urethroscopy without erythema, inflammation or stricture. The urethral end of the fistula was too small in diameter so that it could not be detected by urethroscopy. Therefore the surgical team decided to perform the operation. Under general anesthesia and in the lithotomy position, the skin was opened through a high scrotal midline raphe incision just over the palpable scrotal cyst. When the skin incised, the aim was to remove the cyst and to identify the fistulous tract inside the cyst. The cyst was opened and a monocular cavity containing clear fluid (urine) without septation became manifest. A very small sized fistula on the floor of the cyst (Figure 2a) draining the urine from the urethra when compressing the suprapubic region was seen (Figure 2b). The fistula was between the penile urethra and scrotal cyst without communication with tunica vaginalis. The peripheral wall of the cyst was excised entirely and the fistula was then doubly closed with an absorbable suture. The scrotal skin was closed and an 8F Foley catheter was inserted into the bladder transurethrally and left in situ for 7 days. After removal of the catheter, the patient remained clinically asymptomatic during postoperative 1-month follow-up.

Discussion

The differential diagnoses of scrotal swelling are diverse, including infections (e.g. orchitis, epididymo-orchitis, and scrotal abscess), trauma, neoplasms and anatomical abnormalities (e.g. epididymal cyst, inguinal hernia, hydrocele and urethroscrotal fistula).^[2]

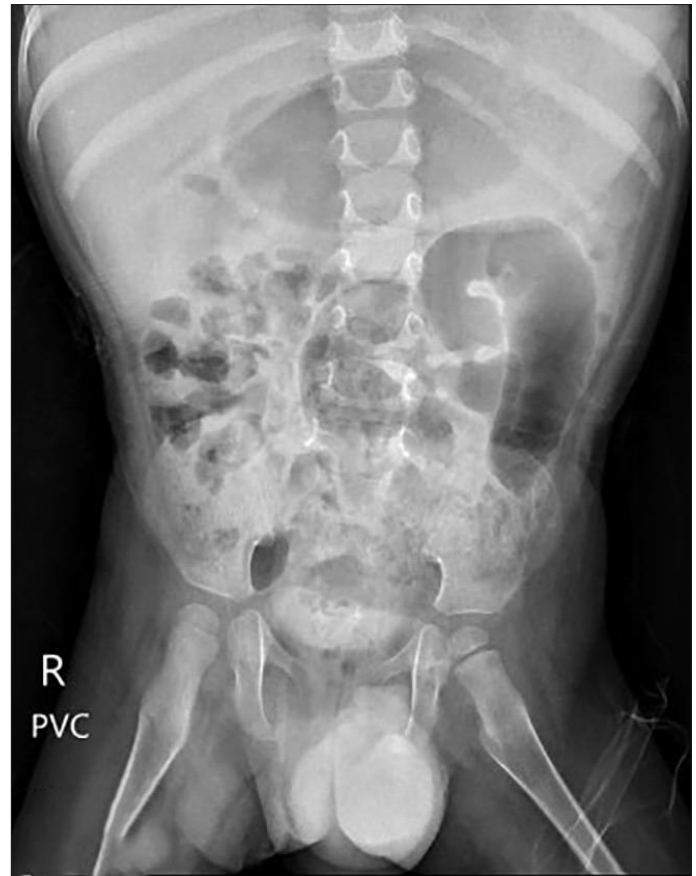

Figure 1. Voiding cystourethrogram showing contrast material accumulation in the scrotum suggestive for an abnormal communication between lower urinary tract and scrotum.

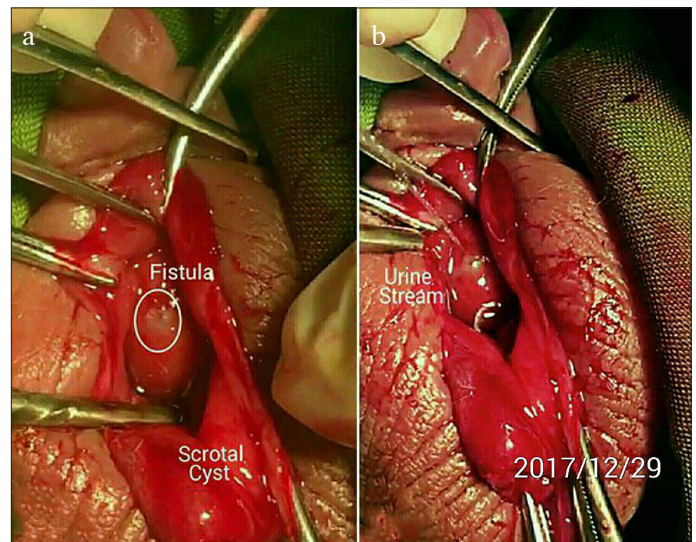


Figure 2. a, b. The opened cyst demonstrating a monocular cavity containing clear fluid (urine) without septation. (a) A very small sized fistula presenting on the floor of the cyst. (b) Draining urine from the urethra when suprapubic region was compressed

Although urethroscrotal fistula is not a common cause for scrotal swelling, it should be considered especially in the differential diagnosis of recurrent scrotal swellings particularly in patients with some risk factors such as urogenital manipulation and urethral stones. However, sometimes there is no risk factor and it is a congenital pathology. The urethra may open into the scrotum, perineal skin, rectum, and vagina causing a fistula with varying signs and symptoms depending on the location of the fistula.^[4] There are very few case reports regarding an iatrogenic urethroscrotal fistula, caused by an inappropriate indwelling catheter insertion.^[5] In adults particularly in Africa, urethral stricture secondary to sexually transmitted diseases may lead to urethroscrotal fistula.^[6] Although extremely rare, urethral tuberculosis might also lead to urethral stricture and urethroscrotal fistula.^[7] Urethral carcinomas mostly secondary to bladder tumors and in <1% of the cases as primary tumors are other causes of urethroscrotal fistulas and scrotal abscess.^[8] Urethrovesical reflux is another rare cause of scrotal fistula causing recurrent epididymitis.^[9]

Our patient had none of the above risk factors such as history of the catheterization and no documented etiology for urethroscrotal fistula was found. So it appeared to be a congenital urethroscrotal fistula causing recurrent episodes of scrotal swelling and abscess.

Importantly pediatric surgeons and urologists should attentively perform intraoperative examination and exploration and preferably use preoperative imaging techniques such as VCUg and retrograde urethrogram instead of a simple incision and drainage of the apparent scrotal cyst or abscess to identify urogenital anomalies or embryologic remnants.^[1]

In conclusion, the pediatricians should be aware and consider urogenital abnormalities especially when approaching recurrent scrotal swellings.

Informed Consent: Written informed consent was obtained from the Welfare Organization of Tehran.

Peer-review: Externally peer-reviewed.

Author Contributions: Concept – S.S., M.K., N.S., M.K.; Design – S.S.; Supervision – S.S., M.K., N.S., M.K.; Data Collection and/or Processing – N.S.; Analysis and/or Interpretation – S.S., M.K., N.S., M.K.; Literature Search – S.S., M.K.; Writing Manuscript – S.S.; Critical Review – S.S., M.K., N.S., M.K.

Conflict of Interest: The authors have no conflicts of interest to declare.

Financial Disclosure: The authors have declared that they did not receive any financial support for this study.

References

1. Redman JF, Rountree GA. Congenital urethral scrotal fistula. *Urology* 1977;9:310-1. [\[CrossRef\]](#)
2. Parlak S, Okay AE. Urethroscrotal fistula: A rare cause of scrotal swelling. *Pol J Radiol* 2016;81:438-40. [\[CrossRef\]](#)
3. Boussourra H, Satáa S, Said Y, Rajhi H, Menif N. Scrotal swelling and penile fistula in a patient with crohn's disease. *Uro Today Int J* 2012;5:25. [\[CrossRef\]](#)
4. Yu NC, Raman SS, Patel M, Barbaric Z. Fistulas of the genitourinary tract: a radiologic review. *Radiographics* 2004;24:1331-52. [\[CrossRef\]](#)
5. Stizzo M, Arcaniolo D, Quattrone C, Balsamo R, Terribile M, Manfredi C, et al. Scrotal abscess drained by iatrogenic urethral fistula in an adult diabetic male. *Case Rep Urol* 2017;9820245. [\[CrossRef\]](#)
6. Sharfi AR, Elarabi YE. The 'watering-can' perineum: presentation and management. *Br J Urol* 1997;80:933-6. [\[CrossRef\]](#)
7. Bouchikhi AA, Amiroune D, Tazi MF, Mellas S, Elammari JE, El Fassi MJ, et al. Isolated urethral tuberculosis in a middle-aged man: a case report. *J Med Case Rep* 2013;7:97. [\[CrossRef\]](#)
8. Moore SJ, Rashidipour O, Moore RB. Primary metastatic squamous cell carcinoma of the male urethra presenting with scrotal abscess and subsequent development of fournier's gangrene. *Clin Med Insights Case Rep* 2016;9:83-6. [\[CrossRef\]](#)
9. Ahn JH, Reiter R, Farcon E, Morales P. Scrotal fistula from urethra-vasal refluxing paraplegia. *Urology* 1989;34:383-4. [\[CrossRef\]](#)