





A comparison between the efficacy and safety of microscopic inguinal and subinguinal varicocelectomy

Şaban Oğuz Demirdöğen¹ , Fatih Özkaya² , Ahmet Emre Cinislioğlu² , Mehmet Sefa Altay² , Şenol Adanur² , Özkan Polat² , İsa Özbey² 

Cite this article as: Demirdöğen ŞO, Özkaya F, Cinislioğlu AE, Altay MS, Adanur Ş, Polat Ö, et al. A comparison between the efficacy and safety of microscopic inguinal and subinguinal varicocelectomy . Turk J Urol 2019; 45(4): 254-60.

ABSTRACT

Objective: To compare microscopic inguinal (MIV) and subinguinal varicocelectomy (MSV) surgeries with respect to efficacy and safety.

Material and methods: Patients who underwent varicocelectomy between January 2002 and January 2018 were evaluated retrospectively and prospectively. The patients who underwent varicocelectomy until December 2015 were analyzed retrospectively and the cases after January 2016 were analyzed prospectively. In our study, the married infertile male cases were compared on the basis of operation duration, number of ligated veins, number of preserved veins, postoperative pain score (visual analogue scale: VAS), patient satisfaction, surgeon satisfaction, changes in sperm parameters, testicular consistency, pregnancy rates, and complications, such as hydrocele, testicular atrophy, and recurrence of varicocele. Surgical success rates were compared by semen analysis between unmarried infertile male cases because pregnancy rates cannot be tested. The patients were recalled for control examinations every 3 months for 1 year and tested the above-mentioned parameters. Statistical Package for the Social Sciences Version 20 Windows Software was used for data analysis and comparison between the two groups.

Results: The study included a total of 136 adult patients. Mean age of the patients was 28.14 (20–41) years. MSV and MIV were performed in 62 (45.6%) and 74 (54.4%) patients, respectively. No statistically significant difference was detected between the two groups in terms of admission duration, semen parameters within the 1-year follow-up process, hormonal changes, and complication rates. Operation duration was significantly longer in the MSV group. It was determined that a fewer number of veins were ligated, and a fewer number of veins needed to be ligated in the MIV group. The analysis of all the patients revealed that pain scores at 4 and 24 hours postoperatively were significantly statistically lower in the MSV group.

Conclusion: MIV and MSV are distinct, efficient, and safe surgical techniques with specific advantages and disadvantages. Their efficacy and safety rates are similar.

Keywords: Microscopic inguinal varicocelectomy; microscopic subinguinal varicocelectomy; microscopic varicocelectomy.

ORCID ID of the author:

Ş.O.D. 0000-0002-8697-8995;
F.Ö. 0000-0002-7776-4231;
A.E.C. 0000-0002-1037-815X;
M.S.A. 0000-0002-5691-0666;
Ş.A. 0000-0002-2508-199X;
Ö.P. 0000-0001-9961-662X;
İ.Ö. 0000-0002-7889-3174.

¹Department of Urology,
Health Science University
Erzurum Regional Training and
Research Hospital, Erzurum,
Turkey

²Department of Urology,
Atatürk University School of
Medicine, Erzurum, Turkey

Submitted:

04.12.2018

Accepted:

31.12.2018

Corresponding Author:

Fatih Özkaya
E-mail: drfatihm@gmail.com

©Copyright 2019 by Turkish
Association of Urology

Available online at
turkishjournalofurology.com

Introduction

Varicocele is the most treatable cause of male infertility.^[1] It may lead to faulty readings of sperm parameters in semen analysis. After varicocelectomy, semen parameters are reportedly improved by approximately 65%–70% and elevated pregnancy rates by 20%–60%. Apart from fertility, additional advantages of

varicocelectomy include preventing testicular hypertrophy in children and adolescents, recovering existing hypertrophy, preserving serum testosterone levels by preventing Leydig cell dysfunction, mediating the production of sperms at a certain amount in the ejaculate of non-obstructive azoospermia cases, and elevating sperm counts after failure of the performed micro testicular sperm extraction (m-TESE).^[1-]

³⁾ Another study has stated that varicocelectomy provided a simpler and cheaper alternative to more complicated and high-cost assisted reproduction techniques (ART).^[4]

Whether or not varicocelectomy was beneficial earlier is debatable. However, varicocelectomy has been proven to be advantageous, and it is important which varicocelectomy technique is more appropriate in the present time since open scrotal interventions have been tried since the beginning of the 1900s. Palomo developed high inguinal varicocelectomy in 1949.^[5] Subsequently, laparoscopic^[6], macroscopic inguinal (Ivanissevich 1960)^[7], radiological embolization^[8], and microscopic inguinal-subinguinal^[9,10] techniques have been developed. All these methods have several advantages and disadvantages; however, there are no as yet studies that compare these techniques. However, the Cochrane database and large reviews have reported that microscopic inguinal and subinguinal techniques are the most advantageous.^[11]

In the present study, we aimed to investigate the most appropriate treatment method for patients by comparing microscopic inguinal and microscopic subinguinal varicocelectomy in terms of postoperative pain, operation duration, number of ligated veins, number of preserved arteries, various complications, such as development of hydrocele, testicular atrophy and recurrence of varicocele, improvement in sperm parameters, and pregnancy rates.

Material and methods

After receipt of approval from Section Executive Committee of Surgical Sciences and Ethics Committee of Ataturk University Medical Faculty (5/171-08.12.2016), a total of 136 patients who underwent inguinal and subinguinal varicocelectomy between January 2002 and January 2018 were evaluated retrospectively and prospectively. The study was carried out in accordance with the Helsinki Declaration, and written informed consent was obtained from each patient prior to the operation.

The patients who underwent varicocelectomy until December 2015 (n=39) were analyzed retrospectively and the cases after January 2016 (n=97) were analyzed prospectively. The cases were assessed by physical examination, semen analysis, and scrotal Doppler ultrasound. The diagnosis of varicocele was established with physical examination for all patients, and radiological imaging was performed in conditions that make diagnosis difficult.

The patients who only had left varicocele and received general anesthesia were included in the study. Those who received epidural and spinal anesthesia were excluded from the study because these types of anesthesia make postoperative pain as-

essment difficult. Surgery was planned for patients with clinical varicocele who were unresponsive to conservative therapy because of extreme pain. The patients who were retrospectively analyzed were excluded from the postoperative pain assessment because pain assessment by VAS was not performed for this group.

Further exclusions included the patients with primary hormonal disorders, hereditary disorders, history of infertility shorter than one year, ongoing use of medication that may affect fertility, subclinical varicocele, history of testicular tumor and chemotherapy-radiotherapy, irregular follow-up examinations, and missing information in the hospital files were excluded from the study.

All the surgeries were performed under a microscope (Figure 1). Microscopic subinguinal varicocelectomy (MSV) was performed at without opening a fascia, whereas in microscopic inguinal varicocelectomy (MIV) the incision was made over the internal inguinal ring at a higher level by exposing the aponeurosis of external oblique muscle distinctly the from subinguinal varicocelectomy.

The married infertile cases were compared in terms of operation duration, number of the ligated veins, number of the preserved arteries, postoperative pain scores (Visual Analogue Scale: VAS), changes in the sperm parameters, testicular consistency, pregnancy rates, and complications, such as hydrocele, testicu-

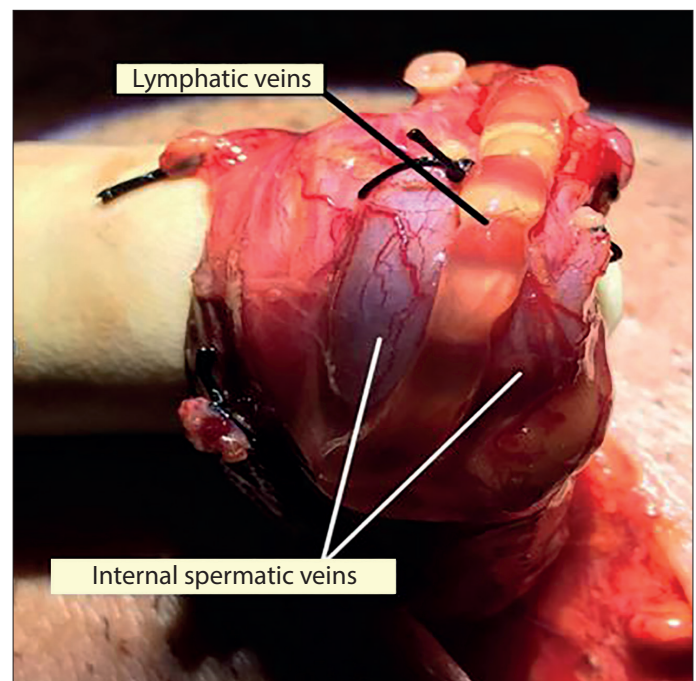


Figure 1. View of the ligated veins and preserved lymphatic vein during microscopic varicocelectomy (archive of The Department of Urology, Ataturk University Medical Faculty)

lar atrophy, and recurrence of varicocele. Surgical success rates between unmarried infertile male cases were compared by semen analysis because pregnancy rates cannot be tested. The cases were recalled for control examinations once every 3 months within a year-long period and assessed in terms of the above-mentioned parameters.

Statistical analysis

Data recording and analysis of the study was performed using IBM Statistical Package for the Social Sciences (IBM SPSS Corp.; Armonk, NY, USA) version 20 for Windows software. The categorical variables were expressed as number and percentage, whereas numerical variables were expressed as a mean±standard deviation. The conformity of the analysis variables to normal distribution was assessed by the Kolmogorov-Smirnov Test. Mann–Whitney U and Wilcoxon tests were used for abnormally distributed quantitative variables in testing hypotheses. Statistically, the significance level was accepted as $p=0.05$.

Results

The present study included a total of 136 adult patients. Mean age of the patients was found to be 28.14 (20–41) years. None of the patients had a systemic disease. No history of previous operations was present in 121 (89%) patients. A history of previous inguinal herniotomy, intra-abdominal surgery, and extra-abdominal surgery was present in 3 (2.2%), 7 (5.1%), and 5 (3.7%) patients, respectively. None of the patients had a history of regular medication use.

Preoperative physical examination revealed Grade 1, Grade 2, and Grade 3 varicocele diagnosed in 8 (5.9%), 28 (20.6%), and 100 (73.5%) patients, respectively. Preoperative examination of the patients also demonstrated normal testicular volume, atrophic left testicle, left testicular softening and concomitant atrophy, and soft testicular consistency in the left testicle in 100 (73.5%), 15 (11%), 11 (7.8%), and 10 (7.6%) patients, respectively.

Of the patients, 121 (89%) were married, whereas 15 (11%) were unmarried. The indications for varicocelectomy were found to be primary infertility, secondary infertility, and pain in 32 (23.5%), 64 (47%), and 25 (18.4%) patients, respectively. Varicocelectomy was indicated due to testicular softening and/or testicular volume loss in 15 (11%) unmarried patients.

Microscopic subinguinal varicocelectomy (MSV) and microscopic inguinal varicocelectomy (MIV) were performed in 62 (45.6%) and 74 (54.4%) patients, respectively. No perioperative or postoperative complication due to general anesthesia was observed in any patient.

Mean surgery duration was 54.23 (35–80) min for all patients. Surgery durations were 65.53 and 47.09 min in the MSV and MIV groups, respectively. The difference between these two groups with respect to surgery duration was statistically significant ($p=0.029$).

The perioperative artery was detected and preserved in 130 (95.6%) patients. Arterial ligation was encountered in only 1 (0.7%) perioperative patient and no development of atrophy was encountered in the follow-up examinations performed every 3 months within 1 year.

The mean number of ligated internal spermatic veins was 4.7 (1–8) in the whole patient group. Mean numbers of the ligated internal spermatic veins in MSV and MIV groups were 5.9 and 2.8, respectively. This difference between the two groups was statistically significant ($p=0.01$). The external spermatic vein was encountered in 130 (95.6%) patients, whereas it could not be evaluated in 6 (4.4%) patients. Two (1.46%) and 4 (2.9%) patients who were encountered without external spermatic veins were in the MSV and MIV groups, respectively. The numbers of the perioperatively preserved arteries, mean numbers of ligated external and internal veins, and preserved lymphatic veins are presented in Table 1.

The evaluation of the postoperative admission durations in the whole patient group showed that 95 (69.9%) patients were extended after 24 hours postoperatively, whereas 41 (30.1%) patients were monitored longer than 24 hours after surgery. None of the patients were monitored longer than 48 hours after surgery. No statistically significant difference was found between the patients regarding admission duration in the hospital according to the separate analysis of each group ($p=0.1$).

Recurrence of varicocele was encountered in no patient at the postoperative 3rd, 6th, 9th, and 12th-month control visits. No complication was observed in 134 (98.5%) patients. At the postoperative 12th-month visit, atrophy and hydrocele were encountered in 1 (0.7%) and 1 (0.7%) patients, respectively. Both of the patients with complications were in the MSV group.

Mean sperm concentration of 21.4×10^6 /mL measured in the preoperative MSV group was found elevated to 25.85×10^6 /mL in the 12th month. Mean sperm concentration of 17.54×10^6 /mL measured in the preoperative MIV group was also found elevated to 20.72×10^6 /mL in the 12th month. No statistically significant difference was found between MSV and MIV groups in terms of changes in the ejaculate sperm concentrations ($p=0.7$).

Mean A+B motility value measured 19.53 in the semen analysis of the preoperative MSV group was found raised to 25.32 at the

postoperative 12th month. A+B motility value measured 18.44 in the semen analysis of the preoperative MIV group was found elevated to 22.88 at the postoperative 12th month. No statistically significant difference was found between MSV and MIV groups regarding changes in the A+B sperm motility ($p=0.1$).

The 12-month follow-up evaluation of the patients in terms of FSH, LH, and testosterone levels demonstrated no statistically significant changes compared with the preoperative period ($p>0.05$). In addition, no statistically significant difference was determined between MSV and MIV groups in terms of hormonal parameters ($p>0.05$).

The rates of the pregnancies that occurred in the postoperative term were analyzed in 96 patients by excluding 25 fertile patients without an expectation of pregnancy who underwent varicocelectomy for pain indication and 15 unmarried patients. The 12-month follow-up demonstrated that spontaneous pregnancy, intrauterine insemination, and in-vitro fertilization assisted pregnancy occurred in 19 (19.79%), 4 (4.16%), and 5 (5.2%)

patients, respectively. No statistically significant difference was encountered between MSV and MIV groups regarding contribution to pregnancy ($p=0.1$).

The evaluation of the pain levels in the patients at the preoperative term (1), postoperative 4th hour (2), postoperative 24th hour (2), postoperative 3rd month (4), postoperative 6th month (5), postoperative 9th month (6), and postoperative 12th month (7) was performed by VAS rating and mean pain scores are shown in Table 2.

Mean pain scores at the postoperative 4th and 24th hours were found to be statistically significantly lower in the MSV group as compared to the MIV group ($p=0.019$ and $p=0.032$ for the postoperative 4th hour and 24th hour, respectively). It was encountered that mean pain scores were higher in MIV than MSV group at each stage after this time point however the differences were not statistically significant ($p>0.05$).

Discussion

Varicocelectomy is the most appropriate technique in the treatment of varicocele and provides the highest contribution to pregnancy rates with the most improved postoperative sperm parameters, and the least complications, such as recurrence, arterial injury, and development of postoperative hydrocele. Microscopic inguinal and subinguinal varicocelectomy appear to be the most ideal surgical techniques in the light of these data.^[11]

Orhan et al.^[11] determined a mean operation duration of 25 min in the patients who underwent microsurgical subinguinal varicocelectomy in their study. Nuhuğlu et al.^[12] detected operation durations of 38 and 24 min in the patient groups and performed subinguinal varicocelectomy using 4X magnification and inguinal varicocelectomy without using a microscope in another study, respectively. Yurdakul et al.^[13] determined mean surgery durations as 43 and 33 min in the patient groups who underwent MSV and high inguinal varicocelectomy without using a microscope, respectively. The operation duration was observed to be shorter in inguinal varicocelectomy with or without a microscope.

In our study, mean operation duration was found to be 54.23 (35–80) min. Mean operation durations were 65.53 and 47.09

Table 1. Microanatomical details of patients who underwent microscopic inguinal and microscopic subinguinal varicocelectomy

Types of blood vessels	Mean
Ligated internal spermatic vein (All patients)	4.7
Ligated internal spermatic vein (MSV)	5.9
Ligated internal spermatic vein (MIV)	2.8
	$p=0.01$
Ligated external spermatic vein (All patients)	1.26
Ligated external spermatic vein (MSV)	1.39
Ligated external spermatic vein (MIV)	1.16
Preserved artery (All patients)	1.26
Preserved artery (MSV)	1.31
Preserved artery (MIV)	1.22
Preserved lymphatic (All patients)	0.79
Preserved lymphatic (MSV)	0.65
Preserved lymphatic (MIV)	0.91

MSV: microscopic subinguinal varicocelectomy; MIV: microscopic inguinal varicocelectomy

Table 2. Mean pain scores of all patients

Pain-1	Preoperative(1)	4 th hour (2)	24 th hour (3)	3 rd month (4)	6 th month (5)	9 th month (6)	12 th month (7)
All groups	1.65	5.89	3.01	1.27	1.06	0.63	0.56
MSV	1.57	5.5	2.67	1.2	1.01	0.55	0.48
MIV	1.7	6.3	3.34	1.32	1.11	0.72	0.64

MSV: microscopic subinguinal varicocelectomy; MIV: microscopic inguinal varicocelectomy

min in MSV and MIV groups, respectively. This difference between these two groups with respect to mean operation duration was statistically significant ($p=0.029$). We conclude that varying operation durations may be originating due to a higher need for artery preservation because of arterial branching at the subinguinal level, as well as the need for a higher number of internal spermatic vein ligations because there are more venous structures in this level.

Although it may be primarily considered that exposing-closing the aponeurosis of the external oblique muscle may prolong the operation duration, this process was not assessed to prolong operation duration significantly. We conclude that these data will guide surgeons who will apply this surgical technique. A series of studies have shown that perioperative complications may increase concordantly with prolonged operation duration.^[14] The significantly shorter operation duration in MIV group may be taken into account as the selection criteria for surgical technique in patients at risk for general anesthesia and in patients with a solitary testicle in whom development of complications may lead to more serious consequences.

A review of the testicular system will show that testicular venous drainage occurs through four distinct systems. The first of these is the internal spermatic (testicular) vein. It is responsible for the main venous drainage of the testicles. It accompanies internal spermatic artery and drains into the renal vein perpendicularly on the left and into the inferior vena cava diagonally on the right. The second system is the deferential (vasal) vein. It accompanies vas deferens and drains into the internal iliac vein through superior and inferior vesical veins. The third system is the external spermatic (cremasteric) vein. It is located on the posterior side of the spermatic cord and drains into the inferior epigastric veins at external inguinal ring region and into the external iliac vein through superficial external veins and deep pudendal veins. The fourth system is the gubernacular system. These veins drain into the external pudendal vein and subsequently to the external iliac vein through the saphenous vein.^[15]

Testicular venous anatomy that varies widely should be known to perfectly elevate treatment success of varicocele and to minimize complication risk. It has been demonstrated that approximately 85-90% of the recurrences after varicocelectomy are due to surgical issues or they originate from the collaterals which "bypass" the percutaneous occlusion area. It has been reported that 60%, 30%, and 0%-10% of internal spermatic vein branches, external spermatic vein, and gubernacular vein are responsible for the recurrences.^[16,17] All the internal and external veins should be ligated during varicocelectomy, whereas ligation of the deferential veins is not recommended because deferential veins are not clearly associated with recurrences and responsible for the venous drainage of the postoperative testicles.^[18]

Lv et al.^[19] reported that they ligated an average of 12.9 internal and 0.9 external spermatic veins in a patient series in whom they have performed MSV. In another study, Hopps et al.^[20] reported that they ligated an average of 11.1 internal and 5.5 external spermatic veins in the patients on whom they performed MSV. Beck et al.^[17] reported that they ligated an average of 8.7 veins in the patients on whom they performed inguinal varicocelectomy, whereas Orhan et al.^[21] reported that they ligated an average of 3.9 and 9.7 veins in the patients in whom they performed high inguinal varicocelectomy and MSV, respectively.^[11]

In our study, mean numbers of the ligated internal spermatic veins were 4.7 (min 1- max 8), 5.9, and 2.8 in the entire patient group, the MSV group, and the MIV group, respectively. The difference between the groups was statistically significant ($p=0.029$). External spermatic veins were encountered in 130 (95.6%) patients. External spermatic veins could not be evaluated in 6 (4.4%) patients. Two (1.46%) and 4 (2.9%) patients in whom the external spermatic veins could not be encountered were in the MSV and MIV groups, respectively. The mean number of ligated external spermatic veins in the whole patient group was 1.26 (0-3). The mean number of ligated spermatic veins was 1.39 and 1.16 in the MSV and MIV groups, respectively. Although we have determined that a greater mean number of veins were ligated in MSV group than in the MIV group in the present study, we also detected that we ligated a fewer number of internal spermatic veins, especially in MSV group compared with literature data. According to our conclusion, this difference might be due to the fact that we performed a dissection above the subinguinal level by placing slight traction on the spermatic cord in the subinguinal approach. Besides that, the results of our study indicated that there was a more complicated venous system in the subinguinal level, and this outcome was parallel with literature data and compatible with our knowledge on vascular anatomy.

There are a limited number of studies that compare the microscopic subinguinal and microscopic inguinal approaches in the intraoperative, perioperative, and postoperative periods. Gontero et al.^[22] compared subinguinal and inguinal varicocelectomy performed under local anesthesia using 3.5X optic magnification in the intraoperative and postoperative periods in their study, and reported that pain scores were significantly higher in the inguinal group in the intraoperative period and that there was no statistically significant difference between the groups in terms of pain scores in the postoperative period. We evaluated the pain statuses in the perioperative and postoperative periods in the present study and encountered that mean pain scores at the postoperative 4th and 24th hours were statistically significantly lower in MSV group as compared to the MIV group ($p=0.019$ and $p=0.032$ for the postoperative 4th and 24th hours, respectively) (Figure 2).

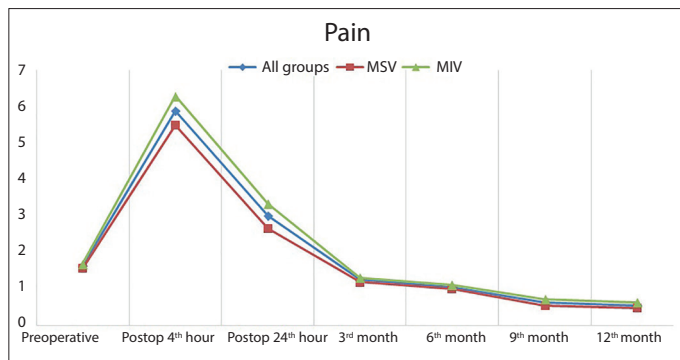


Figure 2. Graphic: Analysis of pain scores of the patients during the follow-up process

MSV: microscopic subinguinal varicocelectomy; MIV: microscopic inguinal varicocelectomy

The mean pain scores were higher in the MIV group at every stage of the follow-up process beginning from this time point; however, the differences between the groups were not statistically significant. The outcomes of our study were compatible with literature. We conclude that varicocelectomy with the microscopic inguinal approach is more painful in the perioperative period due to exposure and closure of external oblique muscle aponeurosis and greater traction on the spermatic cord. However, both techniques may provide similar outcomes after recovery of the wound in the postoperative period.

In conclusion, we conclude that the most accurate decision should be made while selecting the appropriate treatment for a patient with varicocele. The assessment of all venous structures should be microscopically performed by dissection, which may allow preservation of the arterial and lymphatic structures. In this context, microscopic subinguinal and MIV should be preferred owing to their similarly high efficacy and low complication rates.

Microscopic approaches necessitate an adequate level of anatomy knowledge, dissection skills, and high experience. However, surgeons should be aware that they will be faced with a more complicated vasculature at the subinguinal level and a meticulous dissection will be required. Otherwise, arterial structures that may be inadvertently ligated may negatively affect the testicular function and unligated veins may cause recurrence.

The evaluation of the two techniques reveals that;

- MSV may be considered primarily in cases of recurrent varicoceles because venous structures other than internal spermatic veins can be monitored more clearly in this procedure.
- Lack of necessity to expose the aponeurosis of external oblique muscle, ability to perform surgery by placing slight traction on the spermatic cord, and presence of lower perioperative pain in the process of MSV reduces the postoperative pain scores. Therefore, subinguinal approach may

be considered primarily in the patients who undergo varicocelectomy primarily to relieve pain.

- MSV can be considered to eliminate the disadvantages of the operation in patients with obesity and history of previous inguinal surgery because external oblique muscle aponeurosis is not exposed.
- MIV may be advantageous in the evaluation of the small vascular structures more comfortably in children and prepubertal adolescents.
- MIV seems more advantageous in the patients who carry a risk for general anesthesia thanks to shorter operation duration.
- We believe that MIV is more appropriate in patients with solitary testicles because fewer perioperative complications will occur owing to shorter operation durations and a more comfortable and an easier dissection, especially in the arterial structures, as compared to the other technique.
- We consider that surgeons without adequate experience should prefer the inguinal approach until they gain adequate experience in surgery because they will be faced with a more complicated vascular system, for which a more meticulous dissection should be performed in the process of varicocelectomy via subinguinal approach.

Both microscopic inguinal and MSV are distinct, efficient, and safe surgical techniques with specific advantages and disadvantages. They have similar efficacy and safety rates. We believe that further studies on this topic will contribute to literature.

Ethics Committee Approval: Ethics committee approval was received for this study from the ethics committee of Atatürk University School of Medicine (5/171-08.12.2016).

Informed Consent: Written informed consent was obtained from patients who participated in this study.

Peer-review: Externally peer-reviewed.

Author Contributions: Concept – İ.Ö.; Design – Ş.O.D., F.Ö.; Supervision – İ.Ö.; Resources – Ş.O.D., F.Ö.; Materials – A.E.C., M.S.A.; Data Collection and/or Processing – Ş.A., Ö.P.; Analysis and/or Interpretation – Ş.O.D., İ.Ö.; Literature Search – Ş.O.D., F.Ö., İ.Ö.; Writing Manuscript – A.E.C., M.S.A.; Critical Review – Ş.O.D., F.Ö., Ş.A., İ.Ö.; Other – Ş.A., Ö.P.

Conflict of Interest: The authors have no conflicts of interest to declare.

Financial Disclosure: The authors declared that this study has received no financial support.

References

1. Cayan S, Shavakhabov S, Kadioglu A. Treatment of palpable varicocele in infertile men: a meta-analysis to define the best technique. *J Androl* 2009;30:33-40. [CrossRef]

2. Lv JX, Wang LL, Wei XD, Zhang Z, Zheng TL, Huang YH, et al., Comparison of Treatment Outcomes of Different Spermatic Vein Ligation Procedures in Varicocele Treatment. *Am J Ther* 2016;23:1329-34. [\[CrossRef\]](#)
3. Söylemez H, Penbegül N, Atar M, Bozkurt Y, Sancaktutar AA, Altunoluk B. Comparison of laparoscopic and microscopic subinguinal varicocelectomy in terms of postoperative scrotal pain. *JSLs* 2012;16:212-7. [\[CrossRef\]](#)
4. Cayan S, Erdemir F, Ozbey I, Turek PJ, Kadioğlu A, Tellaloğlu S. Can varicocelectomy significantly change the way couples use assisted reproductive technologies? *J Urol* 2002;167:1749-52. [\[CrossRef\]](#)
5. Palomo A. Radical cure of varicocele by a new technique; preliminary report. *J Urol* 1949;61:604-7. [\[CrossRef\]](#)
6. Glassberg KI, Poon SA, Gjertson CK, DeCastro GJ, Misseri R. Laparoscopic lymphatic sparing varicocelectomy in adolescents. *J Urol* 2008;180:326-31. [\[CrossRef\]](#)
7. Ivanissevich O. Left varicocele due to reflux; experience with 4,470 operative cases in forty-two years. *J Int Coll Surg* 1960;34:742-55.
8. Nabi G, Asterlings S, Greene DR, Marsh RL. Percutaneous embolization of varicoceles: outcomes and correlation of semen improvement with pregnancy. *Urology* 2004;63:359-63. [\[CrossRef\]](#)
9. Watanabe M, Nagai A, Kusumi N, Tsuboi H, Nasu Y, Kumon H. Minimal invasiveness and effectivity of subinguinal microscopic varicocelectomy: a comparative study with retroperitoneal high and laparoscopic approaches. *Int J Urol* 2005;12:892-8. [\[CrossRef\]](#)
10. Cayan S, Kadioğlu TC, Tefekli A, Kadioğlu A, Tellaloğlu S. Comparison of results and complications of high ligation surgery and microsurgical high inguinal varicocelectomy in the treatment of varicocele. *Urology* 2000;55:750-4. [\[CrossRef\]](#)
11. Orhan İ, Onur R, Yüzgeç V, Semerciöz A, Fatih F. Subinguinal Varikoselektomide Anatomik Vasküler Varyasyonlar. *Fırat Tıp Dergisi* 2004;9:18-20.
12. Nuhoğlu B, Göçen A, Ersoy E, Ayyıldız A, Fidan V, Germiyanoglu C. Subinguinal mikrocerrahi ve inguinal varikoselektominin semen ve hormon parametrelerine etkilerinin karşılaştırılması, 1 yıllık izlenim. *Turk J Urol* 2004;30:302-7.
13. Yurdakul T, Gökçe G, Kısakol G, Kılınç M. İnfertil erkeklerde yüksek inguinal ve mikrocerrahi ile subinguinal varikoselektominin karşılaştırılması. *Ankara Üniversitesi Tıp Fakültesi Mecmuası* 2003;56. [\[CrossRef\]](#)
14. Cerit N, Gamlı M, Örnek D, Özdoğan L, Erdoğan G, Kalaycı D, ve ark. Genel Anesteziye bağlı perioperatif dönemde gözlenen komplikasyonların ve nedenlerinin retrospektif değerlendirilmesi. *J Anesthesia* 2011;19:106-13.
15. Pettersson S, Söderholm B, Persson JE, Eriksson S, Fritjofsson A. Testicular blood flow in man measured with venous occlusion plethysmography and xenon133. *Scand J Urol Nephrol* 1973;7:115-9. [\[CrossRef\]](#)
16. Coolsaet BL. The varicocele syndrome: venography determining the optimal level for surgical management. *J Urol* 1980;124:833-9. [\[CrossRef\]](#)
17. Beck EM, Schlegel PN, Goldstein M. Intraoperative varicocele anatomy: a macroscopic and microscopic study. *J Urol* 1992;148:1190-4. [\[CrossRef\]](#)
18. Süer E, Yaman Ö. Varikoselelin tedavi endikasyonları, tedavi yöntemleri, prognostik faktörler ve komplikasyonlar. *Erkek üreme sistemi hastalıkları ve tedavisi*, ed. Aşçı R. İstanbul Tıp kitapevi Vol. 1. 2013.
19. Lv KL, Zhuang JT, Zhao L, Wan Z, Zhang YD, Gao Y, et al., Varicocele anatomy during subinguinal microsurgical varicocelectomy in Chinese men. *Andrologia* 2015;47:1190-5. [\[CrossRef\]](#)
20. Hopps CV, Lemer ML, Schlegel PN, Goldstein M. Intraoperative varicocele anatomy: a microscopic study of the inguinal versus subinguinal approach. *J Urol* 2003;170:2366-70. [\[CrossRef\]](#)
21. Orhan İ, Onur R, Yüzgeç V, Semerciöz A, Firdolaş F. Inguinal region testicular artery and vein anatomy. *Fırat Med J* 1999;1:561-4.
22. Gontero P, Pretti G, Fontana F, Zitella A, Marchioro G, Frea B. Inguinal versus subinguinal varicocele vein ligation using magnifying loupe under local anesthesia: which technique is preferable in clinical practice? *Urology* 2005;66:1075-9. [\[CrossRef\]](#)