



Evaluation of the results of dorsolateral buccal mucosal augmentation urethroplasty

Abdulmuttalip Şimşek , Mustafa Gürkan Yenice , Kamil Gökhan Şeker , Yusuf Arıkan , Yunus Çolakoğlu , Emre Şam , Volkan Tuğcu 

Cite this article as: Şimşek A, Yenice MG, Şeker KG, Arıkan Y, Çolakoğlu Y, Şam E, et al. Evaluation of the results of dorsolateral buccal mucosal augmentation urethroplasty. Turk J Urol 2019; 45(3): 223-9.

ABSTRACT

Objective: Evaluation of the results of dorsolateral buccal mucosal augmentation urethroplasty in patients with a long- segment urethral strictures.

Material and methods: Twenty male patients who underwent urethroplasty in our clinic between November 2015 and January 2017 were evaluated. The outcomes of single-stage dorsolateral buccal mucosal augmentation urethroplasty were retrospectively evaluated. Patients were followed-up at 2nd-3rd weeks, 3rd and 6th months after the operation.

Results: Mean age of the patients was 59.45±13.6 years. Mean length of the strictures was 4.59±1.99 cm (3-11 cm) and mean length of buccal mucosal graft was 6.8±1.98 cm (5-13 cm). Mean duration of operation was 149.25±47.39 minutes (95-270 min) and mean blood loss was calculated as 165.5±63.05 mL (75-280 mL). The success rate of dorsolateral buccal mucosal augmentation urethroplasty was calculated as 85% after a mean follow-up of 7.38±2.6 months. There were no perioperative or postoperative complications in the urethroplasty region or the mouth except one patient. Three patients who were found to have a decline in the maximum voiding rate in the postoperative 3rd month were included in the dilation program.

Conclusion: Single-stage dorsolateral buccal mucosal augmentation urethroplasty is a surgical option to be used in the treatment of long segment urethral strictures with high success and low complication rates in experienced hands.

Keywords: Buccal mucosa; dorsolateral onlay; urethral stricture; urethroplasty.

ORCID IDs of the authors:

A.Ş. 0000-0001-8003-4654;
M.G.Y. 0000-0002-5813-3565;
K.G.Ş. 0000-0003-4449-9037;
Y.A. 0000-0003-0823-7400;
Y.Ç. 0000-0001-6432-765X;
E.Ş. 0000-0001-7706-465X;
V.T. 0000-0002-4136-7584.

Clinic of Urology, University of Health Sciences, Bakırköy Dr. Sadi Konuk Training and Research Hospital, İstanbul, Turkey

Submitted:
19.09.2017

Accepted:
15.02.2018

Available Online Date:
21.05.2018

Corresponding Author:
Kamil Gökhan Şeker
E-mail: gkhnseker@hotmail.com

©Copyright 2019 by Turkish Association of Urology

Available online at
turkishjournalofurology.com

Introduction

Male urethral stricture, a problem as old as humanity in urology is a chronic and wide-spread significant urological problem with high patient morbidity and recurrence rates.^[1] The treatment of urethral strictures varies according to location, length, depth and density of spongiofibrous tissue and underlying etiology. Many techniques from urethral dilatation to urethroplasty may be selected based on patient characteristics.^[2] Repeated endoscopic interventions lead to development of challenging scar formations and thus complicate the urethroplasty and cause reduced success and increased complication rates.^[3]

For this reason, urethroplasty has begun to be preferred among urologists in the treatment of urethral strictures.

Many surgical techniques have been developed and described for urethroplasty in urethral reconstructive surgery. These techniques can be classified as excision and primary anastomosis (end-to-end anastomosis) or substitution techniques aimed to expand the urethral lumen.

Excision and urethral anastomosis in short bulbar urethral strictures (end to end anastomosis) is a standard procedure with more than 90% success rate. This approach is usually limited to bulbar urethral strictures of 2 cm

or less. Bulbar urethral strictures longer than 2 cm are successfully treated with augmentation urethroplasty. Today, buccal mucosa is the most common graft material used for substitution urethroplasty.^[4]

Today, there is no consensus concerning the approach of the operation of buccal mucosal urethroplasty including ventral, dorsal, lateral or dorsolateral approaches. Recently, Barbagli and Kulkarni proposed unilateral mobilization of the urethra and placement of the buccal mucosa on the dorsolateral side by preserving the central tendon of the perineum. This placement preserves blood supply to the urethra and neurovascular integrity of the bulbospongiosus muscle.^[5,6]

In this study, we aimed to retrospectively present our experience with single-stage dorsolateral buccal mucosal augmentation urethroplasty in patients diagnosed with urethral stricture.

Materials and methods

Twenty-five male patients who underwent urethroplasty with the diagnosis of long- segment urethral strictures between November 2015 and January 2017 in our clinic were evaluated. Among them data of 20 patients who underwent only single-stage dorsolateral buccal mucosal augmentation urethroplasty were evaluated retrospectively. All operations were performed by a single surgeon (A.S).

Etiology, location and number of urethral strictures and previous surgical procedures were recorded during preoperative evaluation. Urea, creatinine, complete urinalysis, urine culture, coagulometry, uroflowmetry, ultrasound of the urinary system, antegrade and/or retrograde urethrography and flexible urethrocystoscopy were performed preoperatively in all patients. Retrograde urethrography was obtained between postoperative 2nd and 3rd weeks in all patients before removal of the catheter and the status of extravasation was assessed. In the absence of extravasation, urethral catheter was removed and uroflowmetry was performed one day later. If the maximum flow rate (Q_{max}) was observed to be within normal range, the cystostomy catheter was also withdrawn. All patients were followed up after postoperatively at 2nd-3rd weeks, 3rd and 6th months. After removal of the catheter uroflowmetry, postvoid residual urine volume, retrograde urethrography and flexible urethrocystoscopy were performed in all patients. Uroflowmetry, retrograde urethrography and urethrocystoscopy were performed in the postoperative 3rd month.

All patients received intravenous antibiotics for 3 days during the postoperative period, followed by oral antibiotherapy until the catheter was removed. During the postoperative period, the

patients received liquid foods on the first and then a soft and regular diet on the following days.

The success of the urethroplasty was accepted as the primary endpoint of the study. Success was defined as the absence of obstructive symptoms and a need for subsequent procedures such as dilatation, internal urethrotomy and urethroplasty.

All procedures were performed in accordance with the ethical standards of responsible committees on human experimentation (institutional and national) and the Helsinki Declaration of 1975, as revised in 2013. Informed consent was not obtained from all patients due to retrospective design of the study. All data were collected from the hospital record system.

Surgical technique

All patients included in the study underwent dorsolateral onlay buccal mucosal augmentation urethroplasty. All patients were operated in exaggerated lithotomy position. Spinal or general anesthesia were used and nasal intubation was preferred since oral mucosa was to be harvested.

Dorsolateral buccal mucosa augmentation urethroplasty was performed using a midline perineal incision. After division of the bulbospongiosus muscles, the urethra was mobilized from corpora cavernosa only left side (Figure 1). After distal extent of stricture was measured with Foley catheter, dorsal urethral surface was incised along the midline (Figure 2). Once the stricture length was measured, oral mucosa was harvested 2 cm longer than the measured length of the stricture. Oral mucosa was anastomosed to the lateral margin of the urethra using a continuous 5-0 polyglactin suture (Figure 3). After the anastomosis, a 14-16F urethral and a 16-18F cystostomy catheter were placed in all patients. The bulbospongiosus muscle was approximated and the skin and subcutaneous tissue was closed with absorbable sutures.

Statistical analysis

IBM Statistical Package for Social Sciences 22.0 (IBM SPSS Statistics, Armonk, NY, USA) program was used for the analysis of the data. Continuous variables were presented as means±standard deviation. Proportions (percentages) were calculated for discrete variables.

Results

Mean age of the patients was 59.45±13.6 years. The etiologies of the strictures included iatrogenic interventions in 11 (55%), traumatic events in 7 (35%) and previous infections in 2 patients (10%). The strictures were located at bulbar (n=13), bulbomembranous (n= 4) and panurethral regions (n=3). Mean stricture length was 4.59±1.99 cm (3-11 cm). The mean buccal

mucosal graft (BMG) length was 6.8 ± 1.98 cm (5-13 cm). Mean operative time was 149.25 ± 47.39 minutes (95-270 min) and mean blood loss was calculated as 165.5 ± 63.05 mL (75-280 mL). Postoperative wound infection developed in one patient with panurethral stricture and was treated conservatively. No other perioperative and early postoperative complications were observed. Three patients who had stricture recurrence were found to have a decline in the maximum voiding rate at the postoperative 3rd month and included in the urethral dilatation program. Demographic data, perioperative and postoperative findings of the patients are summarized in Table 1. The success rate of dorsolateral buccal mucosal augmentation urethroplasty was calculated as 85% after a mean follow-up of 7.38 ± 2.6 months. Qmax values measured on the last day of the post-

operative follow-up period (16.9 mL/sec) were significantly improved compared to the preoperative Qmax values (5.7 mL/sec) (Table 2).

Discussion

Currently genitourinary reconstructive surgery is performed successfully. On the other hand, the gold standard in urethral reconstructive surgery is urethroplasty in all age groups for long-segment urethral strictures.^[7] Santucci et al.^[8] reported that urethroplasty is a suitable operation in young patients, as well as in patients over the age of 65. In our present study, 11 patients were under the age 65 years and 9 patients were 65 years or older and no morbidity was observed secondary to the operation.

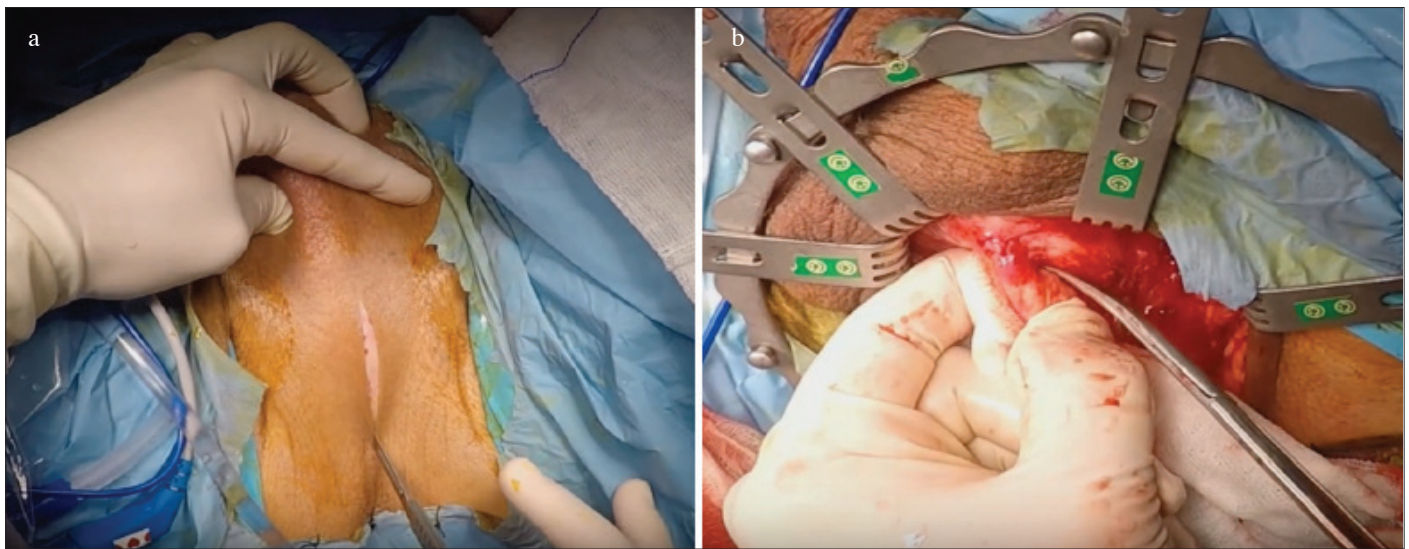


Figure 1. a, b. Perineal incision (a) and unilateral mobilization of the corpus spongiosum (b)

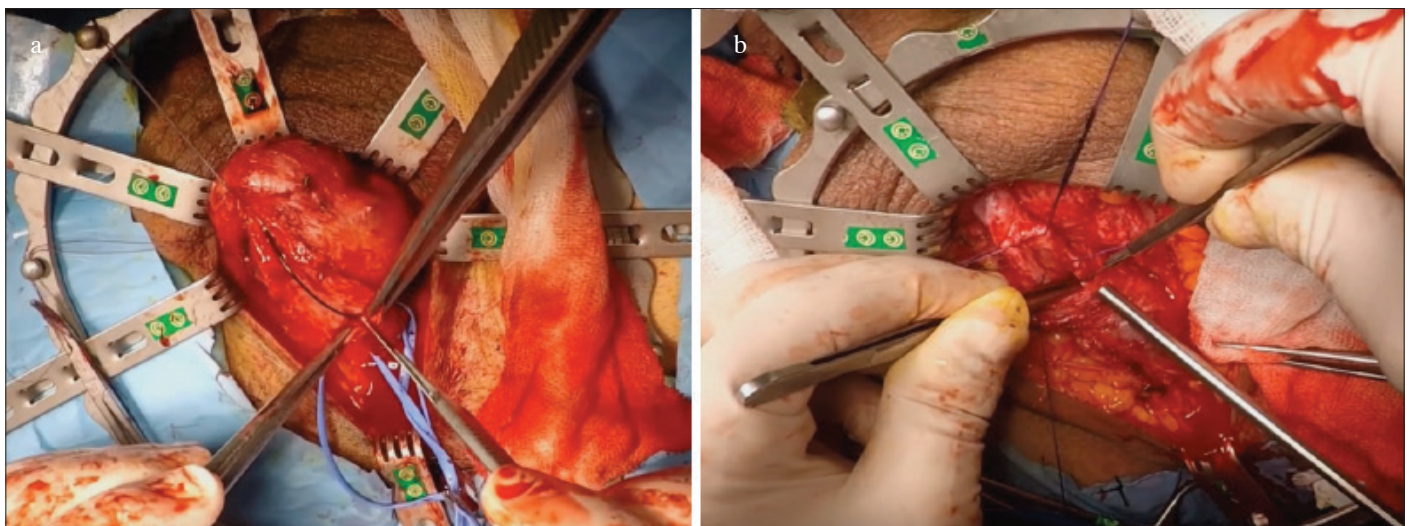


Figure 2. a, b. Incision along the dorsal line of the urethra

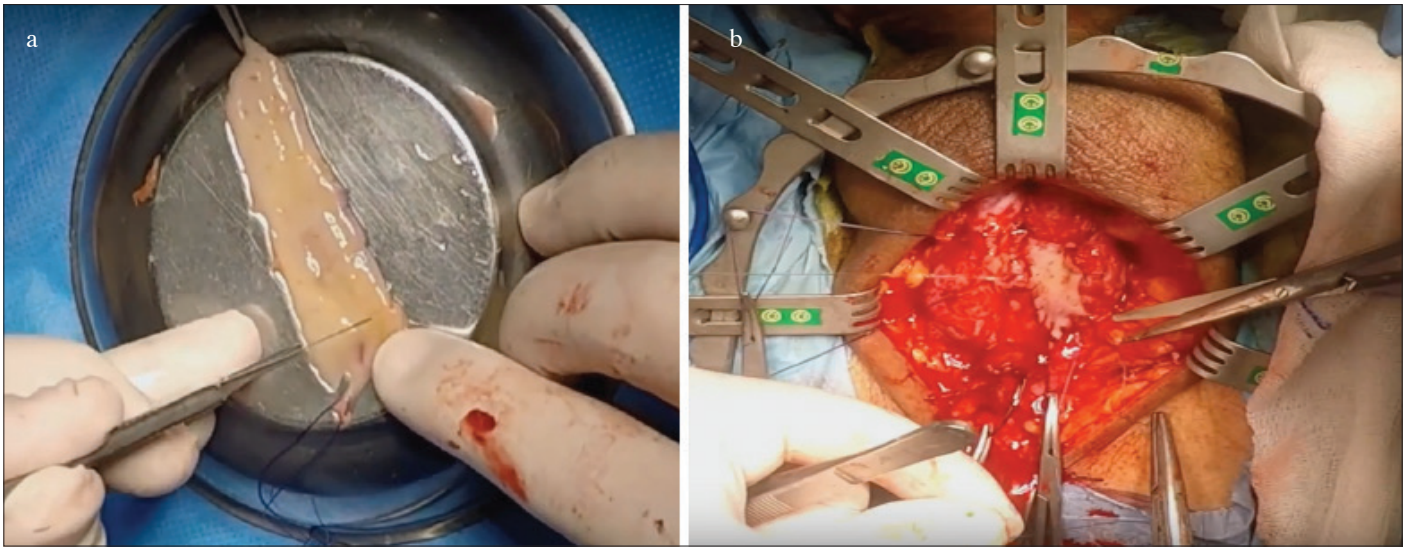


Figure 3. a, b. The prepared buccal mucosa (a) was sutured with 5-0 polyglactin (b)
(Health Sciences University, Bakırköy Dr. Sadi Konuk Training and Research Hospital, Urology Clinic, Reconstructive Urology Unit Archive)

Urethral strictures present with various etiologies. In small series, the main cause of urethral stricture is inflammatory and traumatic in developing countries while idiopathic and iatrogenic in developed countries.^[9] The most common etiological factor in our series was found to be iatrogenic (n=11, 55%).

Surgical technique varies according to the location, length, depth and intensity of the strictures.^[2] In a study in which the effect of length of the strictures on the success of urethroplasty was evaluated, the authors reported an 88% success rate for strictures ≤ 7 cm in length and 40% for strictures longer than 7 cm.^[10] However, there is no consensus in the literature on this subject.

El-Kasaby et al.^[11] were the first who performed BMG urethroplasty in 1993. Currently buccal mucosa is the most preferred graft material in reconstructive urologic surgery due to its easy accessibility and low complication rate and high patient satisfaction.^[12,13] Buccal mucosa heals very quickly and complication rate is quite low.^[14]

We evaluated our results of dorsolateral buccal mucosal augmentation urethroplasty technique defined by Kulkarni.^[6] The approach of placement of the graft, namely dorsal, ventral, lateral or combined technique is still debatable in the buccal mucosal augmentation urethroplasty technique. Dorsal approach can be performed by 2 methods described by Barbagli (dorsal onlay) and Asopa (dorsal inlay), for bulbar augmentation urethroplasty.^[15,16] Dorsal approach is technically more challenging and necessitates a more aggressive surgery. Urethral bed is hard to expose technically. The difference between these two methods

is the technique of mobilization of the dorsal part of the urethra. Dorsal urethra is mobilized using a much wider dissection in the Barbagli method, while urethra is not mobilized dorsally in the Asopa procedure. But Asopa method provides insufficient urethral bed exposure.

When dorsal and ventral placement is compared, some authors suggest that dorsal onlay is superior to ventral technique.^[17,18] A dorsally placed graft gets a better mechanical support from the cavernous bodies and has a more generous vascular bed.^[19,20] On the other hand, perfect results have been reported using ventral onlay buccal mucosal grafts for urethroplasty.^[21] The ventral approach is technically easier compared to the dorsal approach since it provides an easier reach to the urethral lumen and the stenotic segment. Complete mobilization of urethra is not necessary.^[22] Another advantage of the ventral approach is that the shorter anastomosis is easily performed.^[17] In their study, Palminteri et al.^[23] used ventral plus dorsal approach, and emphasized that 2-way grafts would provide adequate urethral width especially in hard and dense strictures. Lateral graft placement defined by Barbagli et al.^[24] is a combination of ventral and dorsal approaches. However, there is extremely limited data to support this approach. Looking at all these techniques and modifications, the unilateral dorsolateral technique that we had used can be suggested as a good alternative for the dorsal onlay technique since it is unnecessary to circumferentially mobilize the urethra and it minimizes vascular and nerve damage.^[25]

In the literature no difference was found in the success rates of dorsal and ventral technique for augmentation urethroplasty using buccal mucosal graft.^[26,27] Similarly, Barbagli et al.^[24] found similar success rates in their study that compared the 3

Table 1. Demographic characteristics of the patients, perioperative and postoperative data

Age	Comorbidity	Etiology of stricture	Length of the stricture (cm)	Length of the Buccal Mucosa graft (cm)	Location of the stricture	Previous urethral/penile procedures	Operative time(min)	Blood loss(ml)	Postoperative 3.month	Postoperative 6.month	Re-operation	Dilatation
71	HT+DM+CAH+CRF	Trauma	8	10	Panurethral	0	270	250	Normal	Normal	-	-
48	None	URS	4	6	Membranous Bulbar	2	165	135	Normal	Normal	-	-
61	None	URS	5	7	Bulbar	1	120	200	Normal	Normal	-	-
73	HT	TUR-P	9	11	Panurethral	1	185	210	Recurrence	Normal	IU	+
60	None	Cystolithotripsy	3	5	Bulbar	4	135	100	Recurrence	Normal	IU	+
38	None	Trauma	3	5	Bulbar	2	120	105	Normal	Normal	-	-
67	BPH	Trauma	3	5	Bulbar	0	110	95	Normal	Normal	-	-
74	HT	Trauma	5	7	Membranous Bulbar	1	165	75	Normal	Normal	-	-
23	None	Trauma	3	5	Bulbar	2	180	130	Normal	Normal	-	-
72	CAH	TUR-P	5	7	Bulbar	2	120	110	Normal	Normal	-	-
57	CAH	By-pass surgery	3	5	Bulbar	2	110	145	Normal	Normal	-	-
74	CRF+HT	RALP	5	7	Bulbar	3	95	120	Normal	Normal	-	-
65	HT	Infection	11	13	Panurethral	3	255	270	Normal	Normal	-	-
58	HT	URS	4	7	Bulbar	2	145	280	Normal	Normal	-	-
49	None	Trauma	4	6	Bulbar	3	130	160	Normal	Normal	-	-
61	HT+DM	URS	5	7	Bulbar	2	135	155	Recurrence	Normal	IU	+
65	HT+CRF+BPH	TUR-P	4	6	Membranous Bulbar	4	160	230	Normal	Normal	-	-
70	HT+CAH+DM	RALP	4	5	Bulbar	3	110	150	Normal	Normal	-	-
41	None	Infection	3	5	Bulbar	3	100	140	Normal	Normal	-	-
62	HT	Trauma	5	7	Membranous Bulbar	1	175	250	Normal	Normal	-	-

HT: hypertension; DM: diabetes mellitus; CAH: coronary artery disease; CRF: chronic renal failure; URS: ureteroscopy; TUR-P: transurethral resection of prostate; RALP: robot-assisted laparoscopic prostatectomy; IU: internal urethrotomy

Table 2. Postoperative success criteria

n=20	Mean
Preoperative Qmax (mL/min)	5.7
Postoperative Qmax (6.month) (mL/min)	16.49
Postoperative RGU normal/ recurrence	20/3
Success/unsucces	17/3

RGU: retrograde urethrography

techniques (dorsal, ventral and lateral approaches). Vasudeva et al.^[25] were the first to prospectively compare the safety and efficacy of ventral and dorsal onlay BMG urethroplasty in patients with long- segment and incomplete bulbar urethral strictures in 2015. The authors found comparable rates of efficacy and complication for both dorsal and ventral onlay buccal mucosal graft urethroplasties. They suggested that the choice between the two techniques should be made according to the surgeon's preference.

In a recent study of the patients with dorsolateral augmentation urethroplasty, mean preoperative and postoperative Qmax values were 4.95 mL/sec and 15.62 mL/sec, respectively.^[27] Kulkarni et al.^[28] reported a perfect result of a single stage procedure using dorsolateral onlay, that is a success rate of 83.7% in a median follow-up of 59 months. We also obtained similar success rates and increased Qmax values in our study.

Similar rates of fistula were found when dorsal and ventral methods were compared in terms of complications.^[24] In the postoperative period of a series of dorsolateral augmentation urethroplasties, scar infection treated with conservative treatment in 3, uretero-cutaneous fistula treated with conservative treatment in 1, and chordee managed with a planned surgical intervention in 1 patient were reported.^[27] In our series no significant complication was observed other than conservatively-treated skin infection of perineal incision area in the postoperative period in one patient with panurethral strictures.

The main limiting factor of this study is its retrospective design. Other limitations of the study included limited number of cases and the short follow-up period.

In conclusion, single stage dorsolateral buccal mucosal augmentation urethroplasty results in high success rates in the treatment of long- segment urethral strictures. Randomized controlled studies with longer durations and larger series are needed in order to evaluate the long- term results of the dorsolateral technique.

Ethics Committee Approval: Authors declared that the research was conducted according to the principles of the World Medical Association Declaration of Helsinki "Ethical Principles for Medical Research Involving Human Subjects", (amended in October 2013).

Informed Consent: Written informed consent was obtained from patients who participated in this study.

Peer-review: Externally peer-reviewed.

Author Contributions: Concept - A.Ş., K.G.Ş.; Design - Y.Ç., A.Ş.; Supervision - A.Ş., V.T., K.G.Ş.; Resources - Y.A., Y.Ç., E.Ş.; Materials - K.G.Ş.; Data Collection and/or Processing - E.Ş., Y.A.; Analysis and/or Interpretation - E.Ş., K.G.Ş., Y.A., Y.Ç., A.Ş.; Literature Search - Y.Ç., Y.A., E.Ş.; Writing Manuscript - K.G.Ş., A.Ş., E.Ş.; Critical Review - A.Ş., V.T., K.G.Ş., E.Ş., Y.Ç.; Other - Y.A., Y.Ç., E.Ş.

Conflict of Interest: No conflict of interest was declared by the authors.

Financial Disclosure: The authors declared that they haven't received any financial support for this study.

References

- Zimmerman WB, Santucci RA. Buccal mucosa urethroplasty for adult urethral strictures. *Indian J Urol* 2011;27:364-70. [\[CrossRef\]](#)
- Peterson AC, Webster GD. Management of urethral stricture disease: developing options for surgical inter-vention. *BJU Int* 2004;94:971-6. [\[CrossRef\]](#)
- Waxman SW, Morey AF. Management of urethral strictures. *Lancet* 2006;367:1379-80. [\[CrossRef\]](#)
- Levy ME, Elliott SP. Graft Use in Bulbar Urethroplasty. *Urol Clin North Am* 2017;44:39-47. [\[CrossRef\]](#)
- Barbagli G, De Stefani S, Annino F, De Carne C, Bianchi G. Muscle- and nerve-sparing bulbar urethroplasty: a new technique. *Eur Urol* 2008;54:335-43. [\[CrossRef\]](#)
- Kulkarni S, Barbagli G, Sansalone S, Lazzeri M. One-sided anterior urethroplasty: a new dorsal onlay graft technique. *BJU Int* 2009;104:1150-5. [\[CrossRef\]](#)
- Morey A. Urethral stricture is now an open surgical disease. *J Urol* 2009;181:953-4. [\[CrossRef\]](#)
- Santucci RA, McAninch JW, Mario LA, Rajpurkar A, Chopra AK, Miller KS, et al. Urethroplasty in patients older than 65 years: indications, results, outcomes and suggested treatment modifications. *J Urol* 2004;172:201-3. [\[CrossRef\]](#)
- Palminteri E, Berdondini E, Verze P, De Nunzio C, Vitarelli A, Carmignani L. Contemporary urethral stricture characteristics in the developed world. *Urology* 2013;81:191-6. [\[CrossRef\]](#)
- Yalcinkaya F, Zengin K, Sertcelik N, Yigitbasi O, Bozkurt H, Sarikaya T, et al. Dorsal Onlay Buccal Mucosal Graft Urethroplasty in the Treatment of Urethral Strictures - Does the Stricture Length Affect Success?. *Adv Clin Exp Med* 2015;24:297-300. [\[CrossRef\]](#)
- El-Kasaby AW, Fath-Alla M, Noweir A, el-Halaby MR, Zaka-ria W, el-Beialy MH. The use of buccal mucosa patch graft in the

- management of anterior urethral strictures. *J Urol* 1993;149:276-78. [\[CrossRef\]](#)
12. Bhargava S, Chapple CR. Buccal mucosal urethroplasty: is it the new gold standard? *BJU Int* 2004;93:1191-3. [\[CrossRef\]](#)
 13. Barbagli G, Vallasciani S, Romano G, Fabbri F, Guazzoni G, Lazzeri M. Morbidity of oral mucosa graft harvesting from a single cheek. *Eur Urol* 2010;58:33-41. [\[CrossRef\]](#)
 14. Dublin N, Stewart LH. Oral complications after buccal mucosal graft harvest for urethroplasty. *BJU Int* 2004;94:867-9. [\[CrossRef\]](#)
 15. Barbagli G, Selli C, di Cello V, Mottola A. A one-stage dorsal free-graft urethroplasty for bulbar urethral strictures. *Br J Urol* 1996;78:929-32. [\[CrossRef\]](#)
 16. Asopa HS, Garg M, Singhal GG, Singh L, Asopa J, Nischal A. Dorsal free graft urethroplasty for urethral stricture by ventral sagittal urethrotomy approach. *Urology* 2001;58:657-9. [\[CrossRef\]](#)
 17. Dubey D, Kumar A, Bansal P. Substitution urethroplasty for anterior urethral strictures: a critical appraisal of various techniques. *BJU Int* 2003;91:215-8. [\[CrossRef\]](#)
 18. Bhandari M, Dubey D, Verma BS. Dorsal or ventral placement of the preputial/penile skin onlay flap for anterior urethral strictures: does it make a difference? *BJU Int* 2001;88:39-43. [\[CrossRef\]](#)
 19. Barbagli G, Palminteri E, Rizzo M. Dorsal onlay graft urethroplasty using penile skin or buccal mucosa in adult bulbourethral strictures. *J Urol* 1998;160:1307-9. [\[CrossRef\]](#)
 20. Liu Y, Zhuang L, Ye W, Ping P, Wu M. One-stage dorsal inlay oral mucosa graft urethroplasty for anterior urethral stricture. *BMC Urol* 2014;14:35. [\[CrossRef\]](#)
 21. Heinke T, Gerharz EW, Bonfig R, Riedmiller H. Ventral onlay urethroplasty using buccal mucosa for complex stricture repair. *Urology* 2003;61:1004-7. [\[CrossRef\]](#)
 22. Wessells H. Ventral onlay graft techniques for urethroplasty. *Urol Clin North Am* 2002; 29:381-7. [\[CrossRef\]](#)
 23. Palminteri E, Berdondini E, Shokeir AA, Iannotta L, Gentile V, Sciarra A. Two-sided bulbar urethroplasty using dorsal plus ventral oral graft: urinary and sexual outcomes of a new technique. *J Urol* 2011;185:1766-71. [\[CrossRef\]](#)
 24. Barbagli G, Palminteri E, Guazzoni G, Turini D, Lazzeri M. Bulbar urethroplasty using buccal mucosa grafts placed on the ventral, dorsal, or lateral surface of the urethra: are results affected by the surgical technique? *J Urol* 2005;174:955-7. [\[CrossRef\]](#)
 25. Vasudeva P, Nanda B, Kumar A, Kumar N, Singh H, Kumar R. Dorsal versus ventral onlay buccal mucosal graft urethroplasty for long-segment bulbar urethral stricture: a prospective randomized study. *Int J Urol* 2015;22:967-71. [\[CrossRef\]](#)
 26. Figler BD, Malaeb BS, Dy GW, Voelzke BB, Wessells H. Impact of graft position on failure of single-stage bulbar urethroplasties with buccal mucosa graft. *Urology* 2013;82:1166-70. [\[CrossRef\]](#)
 27. Habib AK, Alam AK, Amanullah AT, Rahman H, Hossain AK, Salam MA, et al. Dorsolateral onlay urethroplasty for long segment anterior urethral stricture: outcome of a new technique. *Bangladesh Med Res Counc Bull* 2011;37:78-82. [\[CrossRef\]](#)
 28. Kulkarni SB, Joshi PM, Venkatesan K. Management of panurethral stricture disease in Indian *J Urol* 2012;188:824-30.