







Multiparametric MRI fusion-guided prostate biopsy in biopsy naive patients: Preliminary results from 80 patients

Gökhan Sönmez¹ , Şevket Tolga Tombul² , Hakan İmamoğlu³ , Hülya Akgün⁴ , Abdullah Demirtaş² , Atila Tatlışen² 

Cite this article as: Sönmez G, Tombul ŞT, İmamoğlu H, Akgün H, Demirtaş A, Tatlışen A. Multiparametric MRI fusion-guided prostate biopsy in biopsy naive patients: Preliminary results from 80 patients. Turk J Urol 2019; 45(3): 196-201.

ABSTRACT

Objective: The aim of this prospective study was to evaluate the early results of transrectal prostate biopsies performed under the guidance of multiparametric prostate magnetic resonance imaging (mpMRI) in biopsy naive patients.

Material and methods: Biopsy naive patients who had prostate-specific antigen level 4–10 ng/mL and/or abnormal digital rectal examination findings and provided informed consent were examined using mpMRI. The study included 80 patients with an MRI-defined lesion with a Prostate Imaging and Reporting and Data System (PIRADS) score of ≥ 3 . All mpMRIs were reported by the same uro-radiologist according to PIRADS version 2. An MRI-targeted biopsy was performed by an ultrasonography system with rigid fusion registration software. The first two to five core biopsies per MRI-defined lesions were obtained, and then a standard random 12-core biopsy was performed. Transrectal biopsies were performed under local anesthesia or sedoanalgesia.

Results: Of the 80 patients, 29 (36.3%) were found to have cancer using the conventional 12-core biopsy, but only 20 (25%) were found to have prostate cancer using the MRI-targeted prostate biopsy. Combining the two biopsy methods (conventional+MRI-targeted), cancer detection rate increased to 43.8% (35/80 patients). The cancer detection rate using the combined method was statistically higher than that using the conventional biopsy method ($p=0.03$). Using the conventional biopsy method, 960 core biopsies were collected from 80 patients. Of the 960 core biopsies, 111 (11.6%) were found to be cancer. Further, 101 suspected lesions were detected using mpMRI in 80 patients. In addition, 397 core biopsies were obtained from these lesions. Of the 397 core biopsies, 62 (15.6%) were reported as prostate cancer. The core positivity rate of MR-targeted biopsy was statistically higher than that of conventional biopsy ($p=0.04$).

Conclusion: The preliminary results of MRI-targeted prostate biopsy combined with conventional biopsy suggested that the combined biopsy method was crucial in prostate cancer diagnosis especially in patients with prostate cancer suspicion and no biopsy history. However, larger sample prospective studies are needed to validate the effectiveness of MRI-targeted biopsy and combined biopsy methods.

Keywords: Biopsy; cancer; fusion; multiparametric; prostate.

ORCID IDs of the authors:

G.S. 0000-0001-8391-1050;
Ş.T.T. 0000-0002-5398-4088;
H.İ. 0000-0002-2933-662X;
H.A. 0000-0002-9249-4153;
A.D. 0000-0001-9102-5518;
A.T. 0000-0002-4518-139X

¹Clinic of Urology, Kayseri City Hospital, Kayseri, Turkey

²Department of Urology, Erciyes University School of Medicine, Kayseri, Turkey

³Department of Radiology, Erciyes University School of Medicine, Kayseri, Turkey

⁴Department of Pathology, Erciyes University School of Medicine, Kayseri, Turkey

Submitted:
09.05.2018

Accepted:
22.10.2018

Available Online Date:
20.02.2019

Corresponding Author:
Abdullah Demirtaş
E-mail:
mesane@gmail.com

©Copyright 2019 by Turkish Association of Urology

Available online at
turkishjournalofurology.com

Introduction

A histopathological evaluation of transrectal ultrasound-guided biopsy (TRUS-Bx) materials based on suspicious digital rectal examination (DRE) findings and high or increasing serum prostate-specific antigen (PSA) levels is the gold standard in prostate cancer diagnosis. However, the fact that approximately one-third of malignant prostate lesions is isoechoic and cannot be detected using conventional gray-scale TRUS decreases the sensitivity rates of

TRUS-Bx.^[1,2] These restrictions on the use of TRUS have encouraged urologists to use new methods to diagnose prostate cancer. One of these methods is the biopsy of lesions defined using multiparametric prostate magnetic resonance imaging (mpMRI), which has been widely used for the past 10 years. An MRI-targeted biopsy can be performed cognitively under MRI guidance or using ultrasound devices (F-TRUS) with fusion software that can combine MRI images with sonographic images. Multiparametric prostate MRI-targeted biopsies are

recommended in the current clinical practice for re-biopsies of patients who had previous negative biopsy but clinically suspected of cancer, follow-up biopsies of active surveillance, and biopsies of patients who are suspected to have recurrence after local minimally invasive treatment, such as radiotherapy and high-intensity focused ultrasonography.^[3-5]

Recent studies showed that the cancer detection rate of mpMRI-guided prostate biopsy is between 33.7% and 79.5%, which is higher than that of standard 12-core transrectal biopsy.^[6,7] However, the number of studies evaluating the use of MRI-targeted prostate biopsy in biopsy naive patients is limited.^[8,9]

This prospective study aimed to evaluate the results of MRI-targeted transrectal prostate biopsy performed in biopsy naive patients with a high PSA value and/or suspicious DRE findings.

Material and methods

Patient selection and preparation

Patients aged <75 years who had high PSA levels and/or suspicious DRE findings between March 2017 and February 2018 at Erciyes University Urology Clinic were evaluated for fusion biopsy. Inclusion criteria were having clinical suspicion of prostate cancer (a PSA value of 4–10 ng/mL or abnormal DRE findings), being biopsy naive, and having Prostate Imaging and Reporting and Data System (PIRADS) ≥ 3 lesion on mpMRI according to PIRADS version 2 (PIRADS v2).^[10] Patient recruitment for the study is actively continuing. Age, PSA values, DRE findings, body mass index, family history of prostate cancer, and comorbidities of the patients participating in the study were recorded. A clear urine culture was seen for all patients before biopsy. Antiagregant or anticoagulant treatment was stopped 1 week before biopsy after patients consulted to relevant department. Low-molecular-weight heparin (LMWH) was used in comorbidities with high risk of thrombosis, such as atrial fibrillation or carotid artery stenosis. LMWH was terminated a day before biopsy and restarted 3 days after biopsy. Antiagregant or anticoagulant therapy ceased was restarted 1 week after the procedure. Antibiotic prophylaxis was administered as ciprofloxacin 750 mg tablet one night before and at the day of biopsy. After biopsy, antibiotic treatment was stopped. Before biopsy, no bowel preparation, such as enema, was applied.

MpMRI

Before biopsy, all patients underwent a multiparametric prostate MRI without endorectal coils. MRI was performed by Siemens Magnetom 1.5 T (Siemens Medical Solutions, PA, USA) MRI system. The images were reviewed by an experienced uro-radiologist who has no detailed clinical information about the patients. Suspected areas in T2, T1 contrast, and diffusion-weighted images of multiparametric MRI were reported according to PIRADS v2. In

cases of multiple lesions with different PIRADS scores, the lesion with the highest PIRADS score was accepted as dominant lesion.

F-TRUS biopsy

Biopsy procedures were performed under local anesthesia or sedoanalgesia. Local anesthesia was preferred most of the time. However, sedoanalgesia was preferred if the patient could not tolerate pain during the penetration of US probe due to low pain threshold or anal canal stricture due to previous rectal surgeries. The procedure was performed in outpatient clinic conditions. Transrectal ultrasonography was performed by using an ultrasonography system with rigid fusion software (LOGIQ E9; General Electric, MA, USA) when patients lie on the left decubitus position. Rectal lidocaine gel was applied 5 min before rectal US probe was introduced. A sonographic examination of the prostate tissue was performed to check the presence of prominent lesions. Total prostate volumes were measured. Multiparametric prostate MRI images were uploaded to the US system on the day of biopsy. After segmentation (matching) of MRI images with sonographic images, the lesions reported in mpMRI were marked. The periprostatic block was then performed with 2% prilocaine hydrochloride (20 mg/mL) injected into the neurovascular bundle on both sides of the prostate, with 5 mL to the right and 5 mL to the left. Following the block, two to five core biopsies from the MRI-targeted lesions with PIRADS ≥ 3 were obtained. All procedures in fusion biopsy were performed by two urologists experienced and trained in transrectal prostate ultrasonography and biopsy. After the F-TRUS biopsy was completed, a standard 12-core TRUS biopsy was performed on all patients. The fusion biopsy technique and some MR images are described in Figure 1. A histopathological evaluation of biopsy specimens was performed by a uro-pathologist with >10 years of experience. The percentage of cancer within the core, primary, and secondary Gleason score and grade according to the 2014 International Society of Urological Pathology (ISUP) grade^[11] was specified in the final pathology report. Patients reported with high-grade prostatic intraepithelial neoplasm in three or more cores or atypical small acinar proliferation were redirected to rebiopsy, but they were included to the benign group in the evaluation of the present study.

Statistical analysis

Shapiro–Wilk test was used to determine whether data had normal distribution. Parametric data were presented as mean \pm standard deviation, and nonparametric data were presented as median (min–max). Categorical data were expressed as percentage (%) and compared using the chi-square test and McNemar test. A *p* value <0.05 was considered statistically significant.

Ethical issues

The study protocol was approved by the ethics committee of the Medical Faculty of Erciyes University (decision no. 2014/508). Informed consent was obtained from all the patients who agreed to participate in the study.

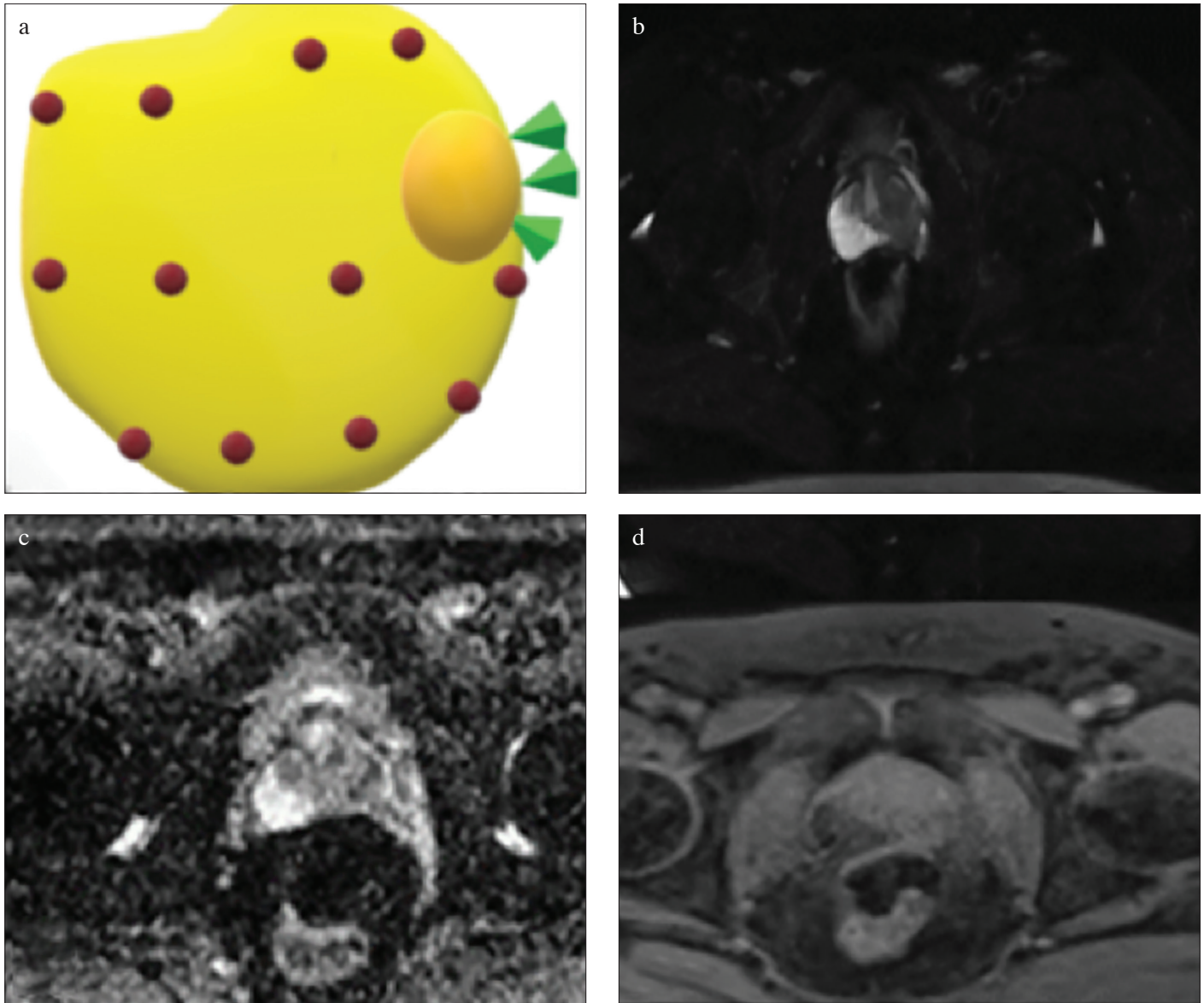


Figure 1. a-d.(a) Schematic view of conventional biopsy and MRI-targeted biopsy. (b) Hypointense lesion extending from the left base posterolateral to the anterior. (c) Hypointense view on apparent diffusion coefficient mapping of the same lesion. (d) Early contrast enhancement of the lesion on T1 dynamic series

Financial support

The present study (project no. TSG-2016-5200) was accomplished with the financial support of Erciyes University Scientific Research Projects Coordination Unit.

Results

A total of 80 patients were included in the study. The mean age of the patients was 61.5 ± 7 years. A biopsy was performed in 58 (72.5%) patients under local anesthesia and in 22 (27.5%) patients under sedoanalgesia. The median PSA level before the bi-

opsy of patients was 5.91 (4.49–8.49) ng/mL. The median prostate volume measured using TRUS was 48.76 (33.25–62.20) mL. Demographic data and mpMRI findings of the patients are summarized in Table 1. PIRADS-3 lesions were found in 36 (45%), PIRADS-4 lesions in 35 (43.75%), and PIRADS-5 lesions in 9 (11.25%) patients with biopsy indications. When evaluating the pathology results with PIRADS score, it was seen that biopsies obtained from PIRADS-4 and PIRADS-5 lesions had the highest cancer detection rate ($p=0.033$). All cancers detected in the biopsies of PIRADS-4 and PIRADS-5 lesions were clinically significant cancers according to the Epstein criteria (Table 2).^[7]

Table 1. Demographic, clinical, and mpMRI data of patients

Data	Value
Age (years)	61.51±7
Body mass index (kg/m ²)	27.7±3.73
PSA (ng/mL)	5.91 (4.49–8.49)
No. of patients with prostate cancer in the family	13 (16.3%)
Total prostate size (mm ³)	48.76 (33.25–62.20)
No. of biopsies under general anesthesia	22 (27.5%)
No. of biopsies under local anesthesia	58 (72.5%)
No. of patients with suspicious findings in the digital examination	28 (35%)
No. of patients with a PIRADS-3 lesion	36 (45%)
No. of patients with a PIRADS-4 lesion	35 (43.75%)
No. of patients with a PIRADS-5 lesion	9 (11.25%)

PIRADS: Prostate Imaging and Reporting and Data System; PSA: prostate-specific antigen

Table 2. Cancer detection rates according to PIRADS values of biopsied lesions

ISUP	Standard biopsy (n=29)	Lesion biopsy (n=20)	Combined biopsy (n=35)
1	15	10	17
2	7	2	8
3	1	3	2
4	5	4	7
5	1	1	1

ISUP: International Society of Urological Pathology; PIRADS: Prostate Imaging and Reporting and Data System

Table 3. ISUP values according to biopsy type of cancer-detected lesions in patients

PIRADS	No. of lesions	Cancer detection rate	P
3	36	30.5% (11/36)	0.033
4 and 5	44	54.5% (19/35)	

ISUP: International Society of Urological Pathology; PIRADS: Prostate Imaging and Reporting and Data System

With standard 12-core biopsy protocol, a total of 960 core biopsies were obtained from 80 patients, and prostate cancer was detected in 111 (11.6%) of them. A total of 101 suspicious lesions were detected in the mpMRI examinations of these patients, and 397 biopsies were collected from these lesions. Of the 397 core biopsies, 62 (15.6%) were reported as prostate cancer. The cancer detection rate difference between fusion biopsy and standard biopsy was statistically significant when compared according to positive core percentage (p=0.041).

Prostate cancer was detected in 29 (36.3%) patients with conventional 12-core biopsy and in 20 (25%) patients with mpMRI-guided fusion biopsy (p=0.004). When conventional and fusion biopsies (conventional+fusion) were taken together, cancer detection rate was increased to 43.8% (35/80 patients). When comparing the cancer detection rates of combined biopsy (conventional+fusion) and conventional 12-core biopsy, the difference was statistically significant (p=0.031).

In 14 patients, cancer was detected in both MR-targeted biopsies and conventional 12-core biopsies. In 5 of them, the ISUP grade of MRI-guided biopsies was higher than that of conventional biopsies. ISUP grades of prostate cancer detected by combined and conventional biopsies are summarized in Table 3. The cancer detection rates for ISUP value ≥3 were 12.5% and 9% for combined biopsy and standard biopsy, respectively (p=0.689).

Discussion

Biopsy naive patients with a PSA value of 4–10 ng/mL were included in the study. The cancer detection rate with conventional 12-core biopsy was 36.3%, whereas it was 43.8% in combined biopsy (conventional 12-core biopsy plus F-TRUS biopsy). According to a recent systematic review^[12], the cancer detection rates ranged 26.3%–56.6% using the conventional method and 33.7%–79.5% using a targeted biopsy. In the present study, although the cancer detection rates with standard biopsy were consistent with the literature findings, the cancer detection rates with fusion biopsy lagged behind. This might be due to the sole inclusion of the first 80 patients' data to the study and not having completed the learning curve of the process.

PIRADS-3 MRI lesions (45%) were detected more in our study. Similarly, Sonn et al.^[3] in their study including 105 cases, showed that 84 of 164 (51.2%) suspected MRI lesions are found to be PIRADS-3 lesions. However, in contrast to our study, patient population was composed of cases with previous negative biopsy, and PIRADS version 1 was used as a scoring system in the study by Sonn et al.^[3] In a similar study with 54 patients, of the 108 lesions, 35 (32.4%) were PIRADS-3 lesions.^[4] The reason for low PIRADS-3 rate may be caused by the inclusion of PIRADS-2 lesions (36.1%) to that study. After excluding PIRADS-2 lesion, the percentage of PIRADS-3 lesions was 50.3%, which is similar to our result.

In a recent study, Del Monte et al.^[13] reported a 63% cancer detection rate in PIRADS-4 and PIRADS-5 lesions. In another prospective study including 39 biopsy naive patients and applying fusion biopsy, it was seen that the PIRADS scores of cancer-detected lesions were significantly higher than those of benign lesions.^[14] Other previous studies in the literature show an increase in cancer detection rates with an increase in PIRADS scores.^[15-17] In the

present study, the prostate cancer detection rates were found to be higher in patients with PIRADS-4 or PIRADS-5 lesions than in those with PIRADS-3 lesions, in accordance with the literature.

Some previous studies compared the number of cores and cancer detection rates. Junker et al.^[16] detected cancer in 52 of 500 standard biopsies received from 50 (10.4%) patients and in 66 of 225 cores obtained by fusion biopsy (29.3%). Another prospective clinical study by Miyagawa et al.^[18] on patients with a previously negative biopsy history showed that the cancer detection rates per core are 32% and 9% for fusion and standard biopsy, respectively. Of the 960 cores collected by conventional biopsy, 111 (11.6%) were reported as cancer. In addition, 62 (15.6%) of the 397 cores obtained by fusion biopsies were reported as cancer, and the difference was found to be statistically significant in favor of fusion biopsy ($p=0.041$). The cancer detection rates per core in the standard biopsy in the present study were similar to those in the aforementioned studies. However, the cancer detection rates using fusion biopsy in the present study were lower than those in the other two studies. This difference might be explained by the lack of our experience in fusion biopsy and the fact that the median PSA values of patients in the present study were lower than those in the other two studies. The mean PSA value of the patients included in the study by Junker et al.^[16] was 7.6 ± 4.2 ng/mL, and the median PSA in the study by Miyagawa et al.^[18] was 9.9 ng/mL (4–34.2).

When the cancer detection rates were examined according to the number of patients in the present study, the rate for conventional biopsy was 36.3% (29/80), and the rate for targeted fusion biopsy was 25% (20/80), and there was a statistically significant difference between the groups ($p=0.004$). When conventional biopsy and fusion biopsy were taken together, cancer detection rate increased to 43.8% (35/80). There was a statistically significant difference between the cancer detection rates for combined biopsy and conventional biopsy ($p=0.031$). A number of studies in the literature have different conclusions on this subject. The reported cancer detection rates in the study by Borkowetz et al.^[19], where 263 patients were compared with regard to targeted fusion biopsy and standard biopsy, were 44% and 35%, respectively ($p=0.002$). However, 68 patients had a history of negative biopsy results. In biopsy naive patients, the cancer detection rates for targeted fusion biopsy and standard biopsy were determined as 46% and 43%, respectively ($p=0.52$). The authors recommended targeted fusion biopsy especially for patients with previous negative biopsy.^[19] The prostate cancer detection rate was reported as 37.8% in a recent prospective study involving 37 patients who had never undergone biopsy.^[20] However, Bosen et al.^[17] determined a 31% detection rate with the MRI/US biopsy and a 36% detection rate with the standard TRUS biopsy in a series of 206 patients with a negative biopsy history, but the difference was not statistically significant ($p=0.15$).

Delongchamps et al.^[21] compared MR/US fusion and systematic biopsy results in a series of 391 patients. They found that fusion biopsies detect additional 17 (25%) patients with high-grade cancer (Gleason score ≥ 7) and only missed 2 (3%) patients (diagnosed with systematic biopsy). Pokorny et al.^[22] reported more patients with prostate cancer with higher Gleason scores using the MR/US fusion biopsy than those using the standard biopsy. In our study, the detection rate of ISUP 3 or higher cancer cases from biopsies obtained from lesions was 10%, whereas this rate was 9% for standard biopsies ($p=0.236$). This rate was 12.5% for combined biopsy, but there was no significant difference between the combined and standard biopsy groups ($p=0.689$). The fact that the results of the present study are incompatible with the literature can be attributed to the lower median PSA levels of our study than those of other studies. The other reasons for that results are the small sample size of our study and the lack of experience.

Our study presented the results of our first 80 patients. We may not complete our learning curve for fusion biopsy. In addition, all steps in fusion biopsy (e.g., segmentation and targeting the lesion according to MRI report) were done by urologists. MpmRI interpretation difference might also have influenced the results. The cancer detection rates may be increased as we experienced with regard to MRI reporting, MRI interpretation, and targeting lesions.

The preliminary results of this prospective, single-center study showed that the combined biopsy method using both techniques is a successful method for biopsy naive patients with suspicious lesions instead of only fusion biopsy or standard biopsy with regard to both cancer diagnosis and clinically significant cancer detection rates. Prospective studies with more patients are needed to evaluate the efficacy of fusion and combined biopsies in biopsy naive patients.

Ethics Committee Approval: Ethics committee approval was received for this study from the ethics committee of Erciyes University School of Medicine (2014/508).

Informed Consent: In this study, the verbal and written consent was obtained from all volunteers.

Peer-review: Externally peer-reviewed.

Author Contributions: Concept – A.D.; Design – A.D.; Supervision – A.T.; Resources – G.S., Ş.T.T.; Materials – G.S., H.A.; Data Collection and/or Processing – G.S., Ş.T.T.; Analysis and/or Interpretation – G.S., A.D.; Literature Search – G.S., H.İ.; Writing Manuscript – G.S., A.D.; Critical Review – A.T., A.D.

Conflict of Interest: The authors have no conflicts of interest to declare.

Financial Disclosure: This study with the project number TSG-2016-5200 was accomplished with the financial support of Erciyes University Scientific Research Projects Coordination Unit.

References

- Ellis WJ, Brawer MK. The significance of isoechoic prostatic carcinoma. *J Urol* 1994;152:2304-7. [\[CrossRef\]](#)
- Shinohara K, Wheeler TM, Scardino PT. The appearance of prostate cancer on transrectal ultrasonography: correlation of imaging and pathological examinations. *J Urol* 1989;142:76-82. [\[CrossRef\]](#)
- Sonn GA, Chang E, Natarajan S, Margolis DJ, Macairan M, Lieu P, et al. Value of targeted prostate biopsy using magnetic resonance-ultrasound fusion in men with prior negative biopsy and elevated prostate-specific antigen. *Eur Urol* 2014;65:809-15. [\[CrossRef\]](#)
- Abd-Alazeez M, Ahmed HU, Arya M, Charman SC, Anastasiadis E, Freeman A, et al. The accuracy of multiparametric MRI in men with negative biopsy and elevated PSA level--Can it rule out clinically significant prostate cancer? *Urol Oncol*. 2014;32:17-22.
- Hu JC, Chang E, Natarajan S, Margolis DJ, Macairan M, Lieu P, et al. Targeted prostate biopsy to select men for active surveillance: Do the Epstein Criteria still apply? *J Urol* 2014;192:385-90.
- Moore CM, Robertson NL, Arsanious N, Middleton T, Villers A, Klotz L. Image-guided prostate biopsy using magnetic resonance imaging-derived targets: a systematic review. *Eur Urol* 2013;63:125-40. [\[CrossRef\]](#)
- Epstein JI, Walsh PC, Carmichael M, Brendler CB. Pathologic and clinical findings to predict tumor extent of nonpalpable (stage T1c) prostate cancer. *JAMA* 1994;271:368-74. [\[CrossRef\]](#)
- Yarlagadda VK, Lai WS, Gordetsky JB, Porter KK, Nix JW, Thomas JV, et al. MRI/US fusion guided prostate biopsy allows for equivalent cancer detection with significantly fewer needle cores in biopsy-naive men. *Diagn Interv Radiol* 2018;24:115-20. [\[CrossRef\]](#)
- Abd-Alazeez M, Kirkham A, Ahmed HU. Performance of multiparametric MRI in men at risk of prostate cancer before the first biopsy: a paired validating cohort study using template prostate mapping biopsies. *Pros Cancer Prostatic Dis* 2014;17:40-6. [\[CrossRef\]](#)
- Barentsz JO, Weinreb JC, Verma S, Thoeny HC, Tempany CM, Shtern F, et al. Synopsis of the PI-RADS v2 guidelines for multiparametric prostate magnetic resonance imaging and recommendations for use. *Eur Urol* 2016;69:41-9. [\[CrossRef\]](#)
- Epstein JI, Egevad L, Amin MB, Delahunt B, Srigley JR, Humphrey PA, et al. The 2014 International Society of Urological Pathology (ISUP) consensus conference on Gleason grading of prostatic carcinoma: definition of grading patterns and proposal for a new grading system. *Am J Surg Pathol* 2016;40:244-52.
- Gayet M, van der Aa A, Beerlage HP, Schrier BP, Mulders PF, Wijkstra H, et al. The value of magnetic resonance imaging and ultrasonography (MRI/US)-fusion biopsy platforms in prostate cancer detection. *BJU Int* 2016;117:392-400. [\[CrossRef\]](#)
- Del Monte M, Leonardo C, Salvo V, Grompone MD, Pecoraro M, Stanzione A, et al. MRI/US fusion-guided biopsy: performing exclusively targeted biopsies for the early detection of prostate cancer. *Radiol Med* 2018;123:227-34. [\[CrossRef\]](#)
- Murphy IG, NiMhurchu E, Gibney RG, McMahon CJ. MRI-directed cognitive fusion-guided biopsy of the anterior prostate tumors. *Diagn Interv Radiol* 2017;23:87-93. [\[CrossRef\]](#)
- Grey AD, Chana MS, Popert R, Wolfe K, Liyanage SH, Acher PL. Diagnostic accuracy of magnetic resonance imaging (MRI) prostate imaging reporting and data system (PI-RADS) scoring in a transperineal prostate biopsy setting. *BJU Int* 2015;115:728-35. [\[CrossRef\]](#)
- Junker D, Schäfer G, Heidegger I, Bektic J, Ladurner M, Jaschke W, et al. Multiparametric magnetic resonance imaging/transrectal ultrasound fusion targeted biopsy of the prostate: preliminary results of a prospective single-centre study. *Urol Int* 2015;94:313-8. [\[CrossRef\]](#)
- Boesen L, Nørgaard N, Løgager V, Balslev I, Thomsen HS. A prospective comparison of selective multiparametric magnetic resonance imaging fusion-targeted and systematic transrectal ultrasound-guided biopsies for detecting prostate cancer in men undergoing repeated biopsies. *Urol Int* 2017;99:384-91. [\[CrossRef\]](#)
- Miyagawa T, Ishikawa S, Kimura T, Suetomi T, Tsutsumi M, Irie T, et al. Real-time Virtual Sonography for navigation during targeted prostate biopsy using magnetic resonance imaging data. *Int J Urol* 2010;17:855-60. [\[CrossRef\]](#)
- Borkowetz A, Platzek I, Toma M, Laniado M, Baretton G, Froehner M, et al. Comparison of systematic transrectal biopsy to transperineal magnetic resonance imaging/ultrasound-fusion biopsy for the diagnosis of prostate cancer. *BJU Int* 2015;116:873-9. [\[CrossRef\]](#)
- Lacetera V, Cervelli B, Cicetti A, Gabrielloni G, Montesi M, Morcellini R, et al. MRI/US fusion prostate biopsy: Our initial experience. *Arch Ital Urol Androl* 2016;88:296-9. [\[CrossRef\]](#)
- Delongchamps NB, Peyromaure M, Schull A, Beuvon F, Bouazza N, Flam T, et al. Prebiopsy magnetic resonance imaging and prostate cancer detection: comparison of random and targeted biopsies. *J Urol* 2013;189:493-9. [\[CrossRef\]](#)
- Pokorny MR, de Rooij M, Duncan E, Schröder FH, Parkinson R, Barentsz JO, et al. Prospective study of diagnostic accuracy comparing prostate cancer detection by transrectal ultrasound-guided biopsy versus magnetic resonance (MR) imaging with subsequent MR-guided biopsy in men without previous prostate biopsies. *Eur Urol* 2014;66:22-9. [\[CrossRef\]](#)