



# Biparametric MRI and 41 sector map for MRI/Transrectal ultrasound fusion biopsy to increase diagnostic accuracy of prostate cancer

Michele Scialpi<sup>1</sup> , Pietro Scialpi<sup>2</sup> , Teresa Pusiol<sup>3</sup> , Alfredo D'Andrea<sup>4</sup>

**Cite this article as:** Scialpi M, Scialpi P, Pusiol T, D'Andrea A. Biparametric MRI and 41 sector map for MRI/Transrectal ultrasound fusion biopsy to increase diagnostic accuracy of prostate cancer. Turk J Urol 2018; 44(6): 453-4

## ABSTRACT

Optimizing the number of prostate biopsy (PB) cores in the initial diagnosis of prostate cancer is still an open question. Increasing the number of cores can expectedly lead to a higher cancer detection rate but more frequent, and greater number of adverse effects should be considered. It is necessary to limit the number of PBs, obtained from tumor areas and areas with a high suspect of malignancy. Simplified Prostate Imaging Reporting and Data System (PIRADS) using biparametric MR imaging (bpMRI) protocol identifies 4 categories indicating the management for each one. We suggest targeted biopsy for category 3b [lesion with a volume  $\geq 0.5$  cc, homogeneous or inhomogeneous, mild/moderately or markedly hypointense on T2-weighted, hyperintense on high b value diffusion-weighted (DW) imaging and moderately hypointense on apparent diffusion coefficient (ADC) map] and category 4 (homogeneous or heterogeneous lesion intra- or extraglandular, mild/moderately or markedly hypointense on T2-weighted, hyperintense on high b value DW imaging and markedly hypointense on ADC map). For a precise localization of the suspected prostate lesions we used a model of 41 sectors/regions map. BpMRI/Transrectal ultrasound fusion-targeted biopsy and the 41 sectors map represent a valid alternative model to the core biopsy of 10-12 systematic transrectal or transperineal peripheral zone biopsies.

**Keywords:** Biparametric MRI; magnetic resonance imaging; prostate cancer; simplified PIRADS; targeted biopsy.

### ORCID IDs of the authors:

M.S. 0000-0002-4842-2304;  
P.S. 0000-0002-3995-1108;  
T.P. 0000-0001-8431-9702;  
A.D.A. 0000-0001-7131-1277.

<sup>1</sup>Section of Diagnostic Imaging, Department of Surgical and Biomedical Sciences, S. Maria della Misericordia Hospital, Perugia University, Perugia, Italy

<sup>2</sup>Division of Urology, Portogruaro Hospital, Venezia, Italy

<sup>3</sup>Provincial Health Care, Institute of Anatomic Pathology, Rovereto Hospital, Verona, Italy

<sup>4</sup>Department of Sperimental Medicine, Magrassi Lanzara, Luigi Vanvitelli, Second University of Naples, Italy

**Submitted:**  
14.07.2018

**Accepted:**  
16.08.2018

**Corresponding Author:**  
Michele Scialpi  
E-mail:  
michelescialpi1@gmail.com

©Copyright 2018 by Turkish Association of Urology

Available online at  
www.turkishjournalofurology.com

In the initial diagnosis of prostate cancer (PCa), 10-12 systematic transrectal or transperineal peripheral zone core biopsies under ultrasound-guidance is recommended.<sup>[1]</sup>

Although in the literature it is widely demonstrated that major complications might occur more frequently in the transrectal biopsy in comparison to transperineal biopsy<sup>[2]</sup>, the optimal number of prostate biopsy (PB) cores is still an open question. An increase in the number of cores can expectedly lead to a higher cancer detection rate, but the adverse effects (e.g. hematuria, rectal bleeding, hematospermia, urinary tract infection, acute urinary retention) are more frequent<sup>[3]</sup> and should be considered. As a consequence, it is necessary to limit the number of PBs taken from certain tumor areas or from areas with a high suspect of malignancy.

Tanaka et al.<sup>[4]</sup> performed PBs in 936 patients with suspect PCa. The Authors revealed that the cancer detection rate using the Nara Urological Research and Treatment Group (NURTG) nomogram allocating a number of 6-12 biopsy cores, based on age and prostate volume could lead to similar efficacy compared with previous studies performed with a greater number of biopsy cores. In older patients, the number of biopsy cores could be reduced and the incidence of adverse events  $\geq$  grade 2 after PB were within acceptable levels.

In our experience to reduce the number of PB cores and complications in patients suspected of PCa, prior to biopsy, we perform biparametric MR imaging (bpMRI) protocol [including the T2-weighted and diffusion-weighted (DW) sequences with Apparent Diffusion Coefficient (ADC) maps reconstruction] at 3T without

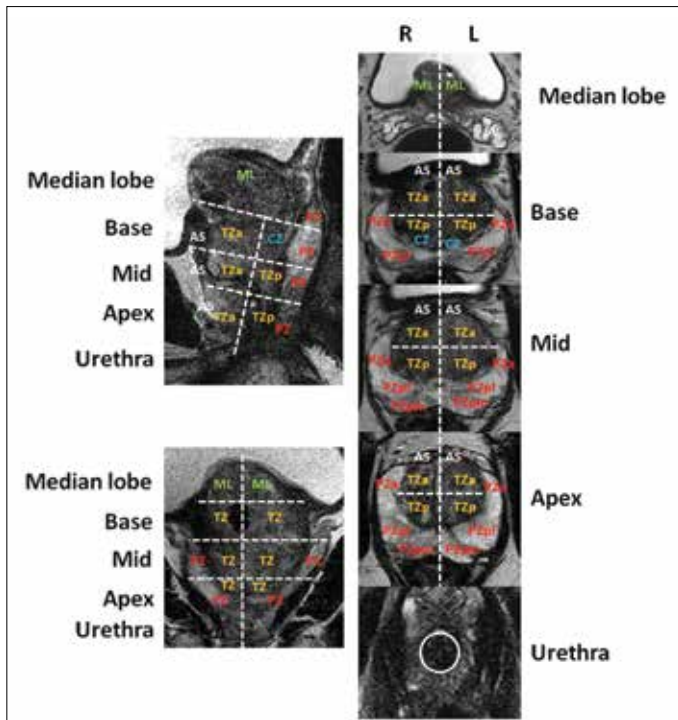


Figure 1. The 41 segmentation model employs forty-one sectors/regions: thirty-eight for the prostate, two for the seminal vesicles and one for the external urethral sphincter. To 39 segmentation model proposed by PIRADS v2, the 41 sector map adds two segment for the right and left segments of the median lobe (ML).

TZ: transitional zone; CZ: central zone; PZ: peripheral zone; AS: anterior stroma; SV: seminal vesicle.

endorectal coil. For a precise localization of the prostate lesion as an alternative to 39 sector-biopsy model for normal prostate proposed by Prostate Imaging Reporting and Data System version 2 (PIRADS v2)<sup>[5]</sup>, we introduced a model of 41 sectors/regions map, adding a left and right segment of the median lobe into assessments (Figure 1).<sup>[6]</sup>

Simplified PIRADS with bpMRI protocol identifies 4 categories indicating the management for each one.<sup>[7,8]</sup> Based on our simplified PIRADS<sup>[7,8]</sup> for bpMRI, targeted biopsy is indicated for category 3b (lesion with a volume  $\geq 0.5$  cc, homogeneous or inhomogeneous, mild/moderately or markedly hypointense on T2-weighted, hyperintense on high b value DW imaging and moderately hypointense on ADC map) and category 4 (homogeneous or heterogeneous lesion intra- or extraglandular, mild/moderately or markedly hypointense on T2-weighted, hyperintense on high b value DW imaging and markedly hypointense on ADC map). We indicate no more than four lesions for each prostate and suggest obtaining four PB cores under transperineal route using bpMRI/Transrectal ultrasound fusion-targeted biopsy protocol.

In clinical practice, we suggest the use of bpMRI/Transrectal ultrasound fusion-targeted biopsy protocol and the 41 sectors map. It is a valid and alternative model to 10-12 systematic transrectal or transperineal core biopsies of the peripheral zone obtained under ultrasound imaging guidance that can reinforce the results of MRI/Transrectal ultrasound fusion-targeted biopsy while reducing its adverse effects.

**Informed consent:** Our institutional review board waived the requirement for written informed consent.

**Peer-review:** Externally peer-reviewed.

**Author Contributions:** Concept - M.S., A.DA., P.S., T.P.; Design - M.S., P.S., A.DA.; Supervision - M.S., A.DA., T.P.; Data Collection and/or Processing - M.S., A.DA.; Analysis and/or Interpretation - M.S.; Literature Search - M.S., P.S., T.P.; Writing Manuscript - M.S.; Critical Review - M.S., P.S., A.DA., T.P.

**Conflict of Interest:** The authors have no conflicts of interest to declare.

**Financial Disclosure:** The authors declared that they haven't received any financial support for this study.

## References

- EAU Guidelines. Available from: <http://www.uroweb.org/guidelines/>. (Accessed 12 Nov 2015).
- Efesoy O, Bozlu M, Çayan S, Akbay E. Complications of transrectal ultrasound-guided 12-core prostate biopsy: a single center experience with 2049 patients. *Turk J Urol* 2013;39:6-11. [\[CrossRef\]](#)
- Loeb S, Vellekoop A, Ahmed HU, Catto J, Emberton M, Nam R, et al. Systematic review of complications prostate biopsy. *Eur Urol* 2013;64:876-92. [\[CrossRef\]](#)
- Tanaka N, Shimada K, Nakagawa Y, Hirao S, Watanabe S, Miyake M, et al. The optimal number of initial prostate biopsy cores in daily practice a prospective study using the NARA Urological Research and Treatment Group nomogram. *BMC Res Notes* 2015;8:689. [\[CrossRef\]](#)
- Available from: <http://www.acr.org/~media/ACR/Documents/PDF/QualitySafety/Resources/PIRADS/PIRADS%20V2.pdf> (Accessed on 2/26/2015).
- Scialpi M, D'Andrea A, Martorana E, Malaspina CM, Aisa MC, Napoletano M, et al. Biparametric MRI of the prostate. *Turk J Urol* 2017;43:401-9. [\[CrossRef\]](#)
- Scialpi M, Martorana E, Aisa MC, Rondoni V, D'Andrea A, Bianchi G. Score 3 prostate lesions: a gray zone for PI-RADS v2. *Turk J Urol* 2017;43:237-40. [\[CrossRef\]](#)
- Scialpi M, Aisa MC, D'Andrea A, Martorana E. Simplified Prostate Imaging Reporting and Data System for Biparametric Prostate MRI: A Proposal. *AJR Am J Roentgenol* 2018;211:379-82. [\[CrossRef\]](#)