







Cystic nephroma: A case report in adult patients

İdris Kıvanç Cavıldak , Mehmet Çağlar Çakıcı , Nihat Karakoyunlu , Hamit Ersoy 

Cite this article as: Cavıldak İD, Çakıcı MÇ, Karakoyunlu N, Ersoy H. Cystic nephroma: A case report in adult patients. Turk J Urol 2018; 44: 373-6.

ABSTRACT

Cystic nephroma is an unusual, cystic neoplasm of the kidney and is usually benign. There are two peaks in the incidence of the tumor, with a bimodal distribution presenting in children younger than two years old and in adults. These benign lesions are usually seen in childhood, whose clinical presentation is nonspecific with symptoms such as flank pain, hematuria and urinary tract infection. We aim to report treatment, and follow-up of a 48-year-old female patient with cystic nephroma for whom we performed open partial nephrectomy. As a surgical treatment radical or partial nephrectomy is applied according to the size and position of the masses. Long-term follow-up is recommended to rule out local recurrence or metastasis.

Keywords: Adult; cystic; kidney; nephroma; neoplasia.

Introduction

Cystic nephroma (CN) is a rarely seen non-hereditary benign cystic lesion of the kidney. It has been termed with various terminologies mainly multilocular CN. Firstly in the year 1893 it was defined by Edmunds^[1], and it was termed as cystic adenoma. This neoplasia which displays bimodal age distribution generally is seen during the first 2 years of life, and it is observed 2 times more frequently in men. It constitutes 2-3% of all primary renal tumors seen during childhood.^[2] However it is rarely seen in adults, especially after the 4. decade, and in women its incidence increases. The main complaint in children is abdominal mass, while in symptomatic adults predominant complaints are abdominal distension, and pain, recurrent urinary system infection, and hematuria.^[3] Mostly asymptomatic neoplasias are detected incidentally during imaging studies. In this case report, a patient with a CN operated because of an incidental renal mass in the light of radiological, and histopathological findings is presented.

Case presentation

Our case was a 48-year-old female patient whose magnetic resonance imaging (MRI) performed 4 months ago with the indication of lumbal disc hernia revealed the presence of a 46x38x45 mm thick-walled cystic lesion with lobulated contours, and multiple thin septae which is localized in the middle part of the lower pole of the left kidney (Figures 1, and 2). Physical examination of the patient who was referred to our clinic was not remarkable, and his routine blood, and urinalyses did not disclose any pathology. The patient underwent open partial nephrectomy because of the presence of a renal mass. His postoperative follow-ups were uneventful, so he was discharged on the 4. postoperative day. During topathological analysis, a multilobular, capsulated cystic neoplasm with smooth surface attracted our attention. On microscopic examination a neoplastic mass consisting of multiple cysts lined with cubic epithelium separated by thick septae was detected (Figure 3). With these histopathological examination the lesion was reported

ORCID IDs of the authors:

İ.K.C. 0000-0003-0149-7146;
M.Ç.Ç. 0000-0002-0176-5887;
N.K. 0000-0002-6680-9860;
H.E. 0000-0001-5113-6731

Department of Urology,
Dışkapı Yıldırım Beyazıt
Training and Research
Hospital, Ankara, Turkey

Submitted:

28.07.2016

Accepted:

25.01.2017

Available Online Date:

19.12.2017

Correspondence:

Mehmet Çağlar Çakıcı
E-mail:
mcaglarcakici@hotmail.com

©Copyright 2017 by Turkish
Association of Urology

Available online at
www.turkishjournalofurology.com

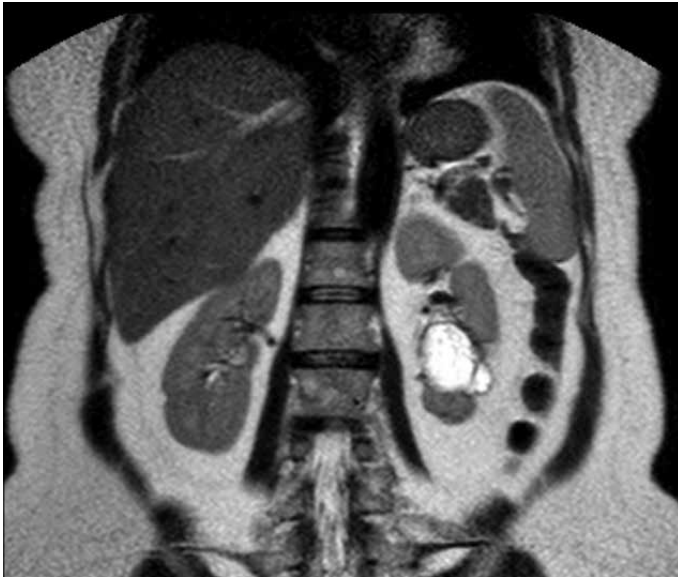

Figure 1. The thick-walled cystic lesion localized in the lower pole of the left kidney in magnetic resonance imaging

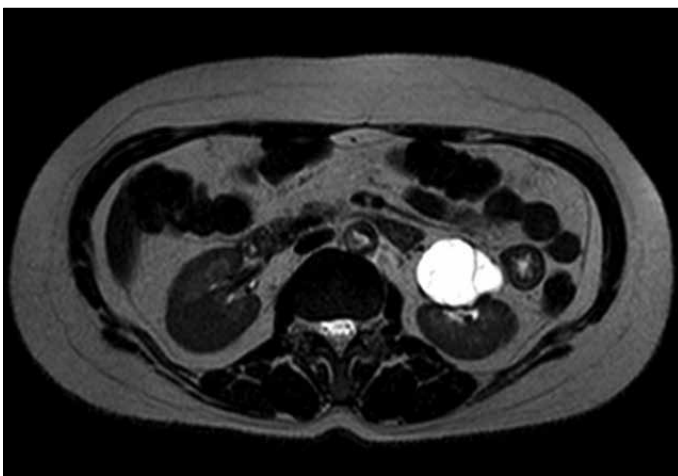


Figure 2. Cystic lesion with contrast-enhanced septae, and cystic walls in magnetic resonance imaging

as pathologic CN. The patient did not receive additional treatment, and any local recurrence or metastasis was not observed during his 3 years of follow-up. The patient was informed about the case presentation, and his written approval was obtained for the publication of the case, and use of imaging modalities.

Discussion

Cystic nephroma is a benign, cystic, multilocular renal mass consisting of epithelial, and stromal elements. It is described by using many terms as cystadenoma, solitary multilocular cyst, benign multilocular cyst, benign CN,

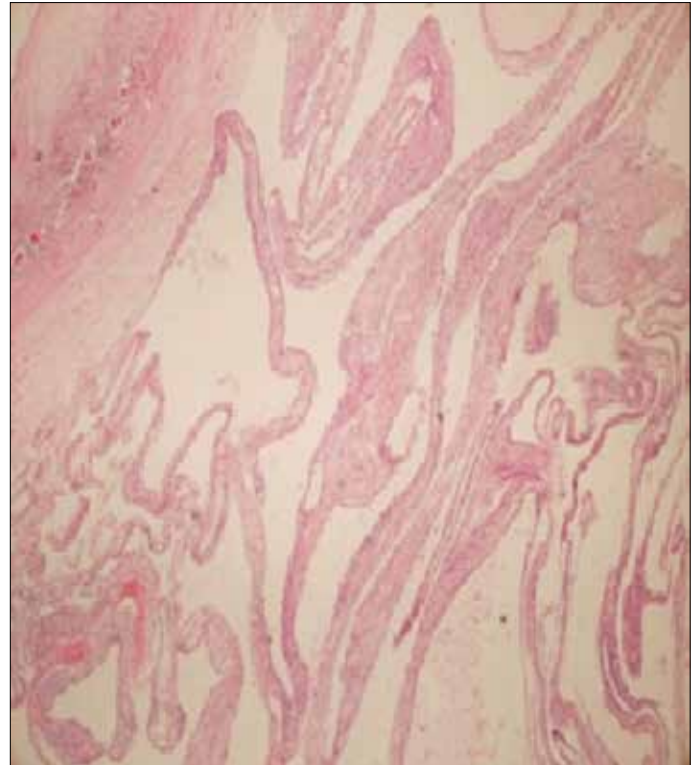


Figure 3. On microscopic examination neoplasm consisting of multiple cysts lined with cuboidal epithelium separated with thick septae is seen

cystic hamartoma, multilocular renal cyst, multilocular CN, and multi-CN.^[4] Though pathology of CN is not known for sure, multiple number of theories where developmental defects become predominant have asserted that they derive from ureteric buds.^[5] In international literature, since 1892 more than 200 cases have been reported.^[6] Histological criteria of the multicystic nephroma were established in 1989 by Joshi and Beckwith.^[7] Accordingly, diagnostic criteria of CN were redefined as follows: a) CN consists of multiple number of cysts, and their septae; b) lesion is a well-circumscribed mass markedly distinct from renal parenchyma; c) it does not contain any solid component, only septae may contain solid parts; d) cyst epithelium contains depressed, cuboidal or "hobnail" cells; e) septae are formed with well-differentiated renal tubular or fibrous tissues. It tends to be unilateral, though very rarely bilateral case reports have been also presented.^[8] They are clinically silent lesions, and as other mass or cystic lesion of the kidneys they are incidentally encountered during radiological examinations. In the differential diagnosis, cystic partial differentiated nephroblastoma, multicystic dysplastic kidney, malignant necrotic and hemorrhagic mass lesions (renal cell carcinoma), and cystic mesoblastic nephroma should be considered.^[9] Though ultrasound,

and computed tomography aid in differential diagnosis, it is generally very difficult to differentiate between Bosniak type 2, and 3 cysts.

Since definitive discrimination is not possible via radiological means, histopathological diagnosis is required for differential diagnosis. Histologically, CNs contain cysts lined with squamous cuboidal or hobnail epithelium firmly encapsulated with a thick, fibrous pseudocapsule. Stromal content changes from dense paucicellular collagen to distinct cellular bundles of spindle cells very closely resembling ovarian stroma.^[15] Immunohistochemical studies have revealed that stromal contents stain mostly with CD10, calretinin, inhibin, estrogen, and progesteron receptors, while epithelial component has an increased affinity to cytokeratin.^[10]

The most recent evidence demonstrate that in adult population, tumors with initial diagnosis of CN essentially represent mixed epithelial, and stromal tumors from genetic, and histological perspectives.^[17] However some authors think that CN, mixed epithelial, and stromal tumors are different spectrums of the same entity.^[11] Besides in genetic studies conducted by Doros et al.^[12] DICER1 mutations have been suggested to have important roles in the development of CN. In the treatment of CN, total or partial nephrectomy is performed. When relevant literature was reviewed, though nephrectomy is seen as a classical treatment modality, we think that under appropriate conditions, nephron-sparing surgery may be the optimal treatment modality.^[4]

No consensus is available on the postoperative follow-up of the patient. Development of cystic renal cell carcinoma originating from CN has been also reported, and postoperative follow-up is recommended. Local recurrence or metastasis is limited to a few cases, and it has been reported that local recurrence especially in patients who underwent partial nephrectomy is a possibility which might be related with incomplete resection.^[3,10] Contrarily, Castillo et al.^[4] presented a series of 29 cases, and couldn't encounter any postoperative local recurrence or metastasis. Also in our case we didn't observe any local recurrence or metastasis.

In conclusion, CN is a rarely observed mostly benign lesion which progresses with a silent course, and demonstrates a bimodal age distribution, and in its differential diagnosis especially malignant cystic renal tumor should be considered. If partial resection of the mass is not contraindicated, then partial nephrectomy is an appropriate treatment approach. If based on clinical, and radiological findings raise

the clinical suspicion of this diagnosis, definitive diagnosis is made through histopathological analysis. Besides, this lesion should be followed up as for malignant transformation, local recurrence or metastasis.

Informed Consent: Written informed consent was obtained patient who participated in this case.

Peer-review: Externally peer-reviewed.

Author Contributions: Concept – İ.K.C., M.Ç.Ç., N.K.; Design – M.Ç.Ç., N.K.; Supervision – N.K., H.E.; Resources – İ.K.C.; Materials – M.Ç.Ç., İ.K.C.; Data Collection and/or Processing – M.Ç.Ç., İ.K.C.; Analysis and/or Interpretation – M.Ç.Ç., H.E.; Literature Search – İ.K.C., M.Ç.Ç.; Writing Manuscript – M.Ç.Ç., İ.K.C., N.K.; Critical Review – N.K., H.E.

Acknowledgements: We would like to thank Dilek Koyuncu for the documentation of the histopathological appearance of the surgical material of our case while preparing the writing.

Conflict of Interest: Authors have no conflicts of interest to declare.

Financial Disclosure: The authors declared that this study has received no financial support.

References

1. Edmunds W. Cystic adenoma of kidney. *Trans Pathol Soc* 1892;43:89-90.
2. Duda-Szymanska J, Kaczmarek J, Papierz W. Cystic nephroma in adults. A report of two cases and review of the literature. *Pol J Pathol* 2005;56:93-6.
3. Dell'Atti L. An Unusual Presentation of Cystic Nephroma in an Adult Man. *Rare Tumors* 2015;7:5860.
4. Castillo OA, Boyle ET Jr, Kramer SA. Multilocular cysts of kidney. A study of 29 patients and review of literature. *Urology* 1991;37:156-62.
5. Sacher P, Willi UV, Niggli F, Stallmach T. Cystic nephroma: a rare benign renal tumor. *Pediatr Surg Int* 1998;13:197-9.
6. Wilkinson C, Palit V, Bardapure M, Thomas J, Browning AJ, Gill K, et al. Adult multilocular cystic nephroma: Report of six cases with clinical, radio-pathologic correlation and review of literature. *Urol Annal* 2013;5:13-7.
7. Joshi VV, Beckwith JB. Multilocular cyst of the kidney (cystic nephroma) and cystic, partially differentiated nephroblastoma. Terminology and criteria for diagnosis. *Cancer* 1989;64:466-79.
8. Sodhi KS, Suri S, Samujh R, Rao KL, Vaiphei K, Saxena AK. Case report: bilateral multilocular cystic nephromas: a rare occurrence. *Br J Radiol* 2005;78:450-2.

9. Mehra BR, Thawait AP, Akther MJ, Narang RR. Multicystic nephroma masquerading as Wilms' tumor: A clinical diagnostic challenge. *Saudi J Kidney Dis Transpl* 2011;22:774-8.
10. Sun BL, Abern M, Garzon S, Setty S. Cystic nephroma/mixed epithelial stromal tumor: a benign neoplasm with potential for recurrence. *Int J Surg Pathol* 2015;23:238-42.
11. Antic T, Perry KT, Harrison K, Zaytsev P, Pins M, Campbell SC, et al. Mixed epithelial and stromal tumors of the kidney and cystic nephroma share overlapping features: reappraisal of 15 lesions. *Arch Pathol Lab Med* 2006;130:80-5.
12. Doros LA, Rossi CT, Yang J, Field A, Williams GM, Messenger Y, et al. DICER1 mutations in childhood cystic nephroma and its relationship to DICER1-renal sarcoma. *Mod Pathol* 2014;27:1267-80.