



Testis-sparing surgery of unilateral testicular large-cell calcifying Sertoli cell tumor: a sporadic case

Eyyüp Sabri Pelit¹ , Bülent Erol¹ , Tülay Zenginkinet² , Turhan Çaşkurulu¹ 

Cite this article as: Pelit ES, Erol B, Zenginkinet T, Çaşkurulu T. Testis-sparing surgery of unilateral testicular large cell calcifying sertoli cell tumor in a sporadic case. Turk J Urol 2018; 44: 370-2.

ABSTRACT

Testicular sex cord-stromal tumors constitute a small portion of all types of testicular tumors. Only 1% of these tumors are pure Sertoli cell tumors. Sertoli cell tumors have three identified subgroups: large-cell calcifying (LCCSCT), sclerosing Sertoli cell and general type. Up to 40% of LCCSCT are associated with the genetic syndromes like Carney complex, Peutz-Jeghers syndrome. These lesions are usually benign, only 17% of the cases show malignant behaviour. Herein, we report a case of unilateral LCCSCT in a 37 year-old man without any hormonal symptoms or inherited diseases which was successfully treated with testis-sparing surgery.

Keywords: Large cell calcifying sertoli cell tumor; partial orchiectomy; testicular cancer.

Introduction

Testicular sex-cord stromal tumors constitute a small portion of all types of testicular tumors. Large-cell calcifying Sertoli cell tumor (LCCSCT) is an exceedingly rare lesion of the testicle.^[1] It is commonly seen with Carney complex (CNC) or Peutz-Jeghers syndrome (PJS).^[2] We now report a case of unilateral LCCSCT in a 37 year-old man with no other conditions or a genetic syndrome, such as PJS or CNC who was successfully treated with testis-sparing orchiectomy.

Case presentation

Thirty-seven-year-old patient was admitted to hospital with a right scrotal pain and right leg pain. On physical examination there was no palpable testicular mass. Doppler ultrasound examination revealed 9x7x8 mm cystic mass containing 2 mm calcified foci and solid areas with increased blood flow. Preoperative tumor markers as lactate

dehydrogenase (LDH), alpha-fetoprotein (AFP), beta-human chorionic gonadotropin (β -hCG) levels were within normal range. Chest and abdominal computed tomography (CT) showed no metastasis or any other abnormality. Patient was also evaluated with cardiac echocardiography for Carney's complex. We decided to perform inguinal exploration. Consequently, right partial orchiectomy was attempted with the peroperative color doppler ultrasound guidance (Figure 1). Intraoperative frozen section examination revealed the lesion as LCCSCT. Microscopically there was a well defined tumoral nodule within testis (Figure 2a). Tumor was composed of neoplastic cells arranged in nests, cords, trabeculae or diffuse sheets in a hyalinized myxoid stroma. Calcification was prominent in the stroma (Figure 2b). Tumor cells were stained strongly positive with Inhibin, S-100, SMA, beta-catenin and weakly positive with calretinin which supported a stromal origin (Figure 2c). They stained negatively with SALL 4, OCT4 and pancytokeratin which excluded

ORCID IDs of the authors:

E.S.P. 0000-0001-8550-5072;

B.E. 0000-0003-2402-3373;

T.Z. 0000-0003-3056-2074;

T.Ç. 0000-0002-4471-2670

¹Department of Urology, Medeniyet University Göztepe Training and Research Hospital, İstanbul, Turkey

²Department of Pathology, Medeniyet University Göztepe Training and Research Hospital, İstanbul, Turkey

Submitted:

07.09.2016

Accepted:

25.01.2017

Available Online Date:

21.12.2017

Correspondence:

Bülent Erol

E-mail:

erolbulent@yahoo.com

©Copyright 2018 by Turkish Association of Urology

Available online at
www.turkishjournalofurology.com

a germ cell tumor or a tumor with epithelial origin, and the final histopathological report was LCCSCT.

There was no tumor recurrence or metastasis during a follow-up of 12-months. Testosterone level and sperm parameters remained within normal level. Informed consent of the patient was obtained.

Discussion

Large-cell calcifying Sertoli cell tumor is a very rare subtype of Sertoli cell tumor. It was first described in 1980 by Proppe and Scully^[3] and up to now more than 70 cases have been reported in the literature. LCCSCTs are divided into two subgroups as early-onset LCCSCT and late-onset LCCSCT. Early-onset LCCSCT is generally bilateral, hereditary and usually seen before the age of 17 and associated with dysplastic syndromes. As seen in our case, late-onset LCCSCT is usually a unilateral, solitary lesion and it onsets at an average age of 39 years.^[4,5] In contrast to other types of testicular tumors, LCCSCT affects both testicles in 20% of sporadic cases.^[2] LCCSCT is associated with the genetic syndromes

such as Carney complex (skin pigmentation, cardiac myxoma, endocrine overactivity) and Peutz –Jegher syndrome (gastrointestinal polyposis, mucocutaneous pigmentation). In PJS, disease generally starts at an early age between 6-7 years and tumors are bilateral and multifocal.^[6] In CC, more than 50% of the male patients have testicular tumours. Almost all testicular tumors seen in CC show benign characteristics except 1 patient.^[7] In sporadic cases like our patient there is no skin pigmentation and cardiac abnormality in echocardiographic examination. If the final pathological report of the testis tumor is LCCSCT, patient and family members should be re-evaluated from the point of genetic syndromes. These tumors are usually benign, however 17% of the cases show malignant features. Malignant types are usually found in an older population and tend to be larger, unilateral and monofocal. Kratzer et al.^[8] have defined the criteria to be malignant when they fulfil 2 or more of the following criteria: extra testicular involvement, testicular size more than 4 cm, mitoses more than 3 per 10 high power fields, extensive nuclear atypia, necrosis, or lymphoreticular invasion. As we know that these tumors are usually benign, we can perform testis-sparing orchiectomy instead of radical orchidectomy. However, testis-sparing surgery is a rational approach only if certain criteria are fulfilled. Firstly, intraoperative frozen section analysis must be performed to prove the benign character of the tumor. Secondly, the tumor has to be smaller than 20-25 mm. Finally, preoperative testicular function has to be normal as documented by testosterone level.^[9] All of these criterias have been fulfilled for the present case.

Large-cell calcifying Sertoli cell tumor should be evaluated for the genetic dysplastic syndromes. Due to benign behavior of this tumor, partial orchiectomy should be the treatment of choice if the tumor is eligible for the organ-sparing surgery.

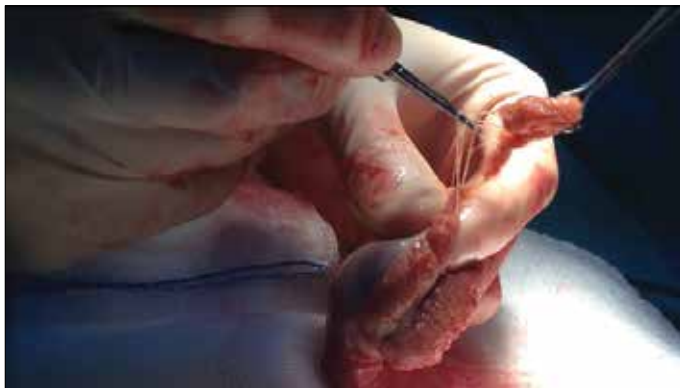

Figure 1. Intraoperative image of partial orchiectomy

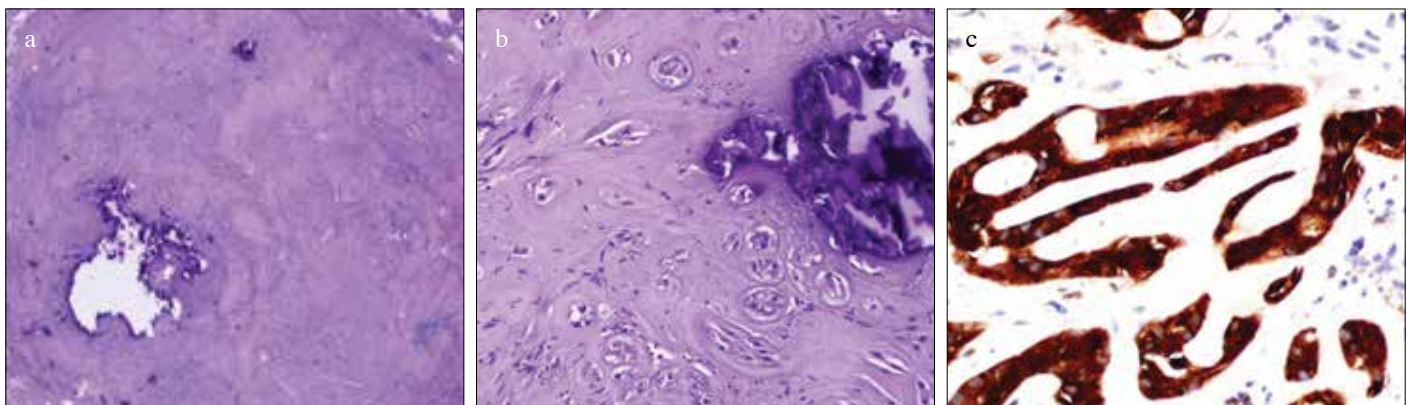


Figure 2. a-c. (a) (H&E 4X): Well defined tumoral nodule within testis. (b) (H&E 20x): Large eosinophilic tumoral cells forming small nests and cords within hyalinized stroma containing prominent calcification. (c) Strong and diffuse inhibin staining in tumor cells

Informed Consent: Written informed consent was obtained from patient who participated in this case.

Peer-review: Externally peer-reviewed.

Author Contributions: Concept – B.E.; Design – B.E.; Supervision – T.Ç.; Data Collection and/or Processing – T.Z.; Analysis and/or Interpretation – E.S.P.; Literature Search – E.S.P.; Writing Manuscript – E.S.P.; Critical Review – T.Ç.

Conflict of Interest: Authors have no conflicts of interest to declare.

Financial Disclosure: The authors declared that this study has received no financial support.

References

1. Zukerberg LR, Young RH, Scully RE. Sclerosing Sertoli cell tumor of the testis. A report of 10 cases. *Am J Surg Pathol* 1991;15:829-34.
2. Halat SK, Ponsky LE, MacLennan GT. Large cell calcifying Sertoli cell tumor of testis. *J Urol* 2007;177:2338.
3. Proppe KH, Scully RE. Large-cell calcifying Sertoli cell tumor of the testis. *Am J Clin Pathol* 1980;74:607-19.
4. Oldenburg WA, Lau LL, Rodenberg TJ, Edmonds HJ, Burger CD. Acute mesenteric ischemia: a clinical review. *Arch Intern Med* 2004;164:1054-62.
5. Arthurs ZM, Titus J, Bannazadeh M, Eagleton MJ, Srivastava S, Sarac TP, et al. A comparison of endovascular revascularization with traditional therapy for the treatment Page 4 of 10 Revised September 2014 Page 5 of 6 of acute mesenteric ischemia. *J Vasc Surg* 2011;53:698-704.
6. Ulbright TM, Amin MB, Young RH. Intratubular large cell hyalinizing sertoli cell neoplasia of the testis: a report of 8 cases of a distinctive lesion of the Peutz-Jeghers syndrome. *Am J Surg Pathol* 2007;31:827-35.
7. Carney JA, Gordon H, Carpenter PC, Shenoy BV, Go VL. The complex of myxomas, spotty pigmentation, and endocrine overactivity. *Medicine (Baltimore)* 1985;64:270-83.
8. Kratzer SS, Ulbright TM, Talerma A, Srigley JR, Roth LM, Wahle GR, et al. Large cell calcifying Sertoli cell tumor of the testis: contrasting features of six malignant and six benign tumors and a review of the literature. *Am J Surg Pathol* 1997;21:1271-80.
9. Steiner H, Hörtl L, Maneschg C, Berger AP, Rogatsch H, Bartsch G, et al. Frozen section analysis-guided organ-sparing approach in testicular tumors: technique, feasibility and longterm results. *Urology* 2003;62:508-13.