



Giant renal metastasis from prostate cancer mimicking renal cell carcinoma

Neslihan Kurtul¹ , Sefa Resim² , Sezen Koçarlan³ 

Cite this article as: Kurtul N, Resim S, Koçarlan S. Giant renal metastasis from prostate cancer mimicking renal cell carcinoma. Turk J Urol 2018; 44: 367-9.

ABSTRACT

The most common sites for prostate cancer metastasis include bone, distant lymph nodes, liver and lungs. Renal metastasis of prostate cancer is a rarely seen pattern of invasion. In the current study, we described an 83-year-old male with a history of prostate cancer. He was admitted because of edema, hyperemia, warm and pain at left leg and inguinal region. In the further evaluation, a mass lesion at prostate region and conglomerate lymphadenopathy at left iliac vascular trajectory and a mass lesion at left kidney with heterogeneous contrast-enhancement were observed on contrast-enhanced magnetic resonance imaging and computerized tomography scan. Fine-needle aspiration biopsy was performed in the lesion with radiologically suspect renal cell carcinoma. By evaluating histopathological features and immunohistochemical staining of the tumor, we decided that the lesion was metastasis from prostate cancer.

Keywords: Prostate cancer; renal metastasis; survival.

ORCID IDs of the authors:
N.K. 0000-0001-9173-6280;
S.R. 0000-0003-1652-4792;
S.K. 0000-0002-3512-1588.

¹Department of Radiation Oncology, Kahramanmaraş Sütçü İmam University School of Medicine, Kahramanmaraş, Turkey

²Department of Urology, Kahramanmaraş Sütçü İmam University School of Medicine, Kahramanmaraş, Turkey

³Department of Pathology, Kahramanmaraş Sütçü İmam University School of Medicine, Kahramanmaraş, Turkey

Submitted:
05.01.2017

Accepted:
20.02.2017

Available Online Date:
11.12.2017

Correspondence:
Neslihan Kurtul
E-mail:
drneslihankurtul@gmail.com

©Copyright 2018 by Turkish Association of Urology

Available online at
www.turkishjournalofurology.com

Introduction

Prostate cancer (PCa) is one of the most commonly diagnosed solid organ malignancies. Depending on age at diagnosis, metastatic disease can be observed up to 17% in patients with PCa, and cancer-specific mortality is increased in patients with metastatic disease.^[1] The most common sites for metastasis include bone (84%), distant lymph nodes (10.6%) liver (10.2%) and thorax (9.1%).^[2] In the literature, renal metastasis from PCa are very rarely. In this case report, we have presented a giant renal metastatic lesion originating from prostate adenocarcinoma.

Case presentation

An 83-year-old man presented to our hospital with edema, hyperemia, warm and pain at left leg and inguinal region. In the history, it was found out that the patient had undergone transurethral resection for prostate two years ago and the prostate-specific antigen (PSA) level was 114 ng/mL at the time of diagnosis. Gleason

grade was 4+4 and he had metastasis to thoracic vertebrae as detected on bone scintigraphy. There was no solid organ metastasis at the time of the diagnosis. Anti-androgen therapy (bicalutamide 50 mg PO, daily and goserelin acetate 10.8 mg SC, every 12 weeks) were initiated after surgery in another facility. PSA and testosterone were found as 0.4 ng/mL and 11.55 ng/mL, respectively. In digital rectal examination, prostate was hard, fixed with irregular contours. A mass lesion at prostate region and conglomerate lymphadenopathy at left iliac vascular trajectory which had a broad contingence with bladder were observed on contrast-enhanced magnetic resonance imaging and computerized tomography scan. In addition, a mass lesion (9x7.5x11 cm in size) with heterogeneous contrast-enhancement at the left kidney was observed (Figure 1). Tumor invasion was seen at perirenal and retroperitoneal space adjacent to mass lesion. Left renal artery and vein were enveloped by mass lesion, indicating likelihood of renal cell carcinoma. The patient was considered to be PCa with metastases at pelvic lymph node and bone; so 3000 cGy palliative radiotherapy

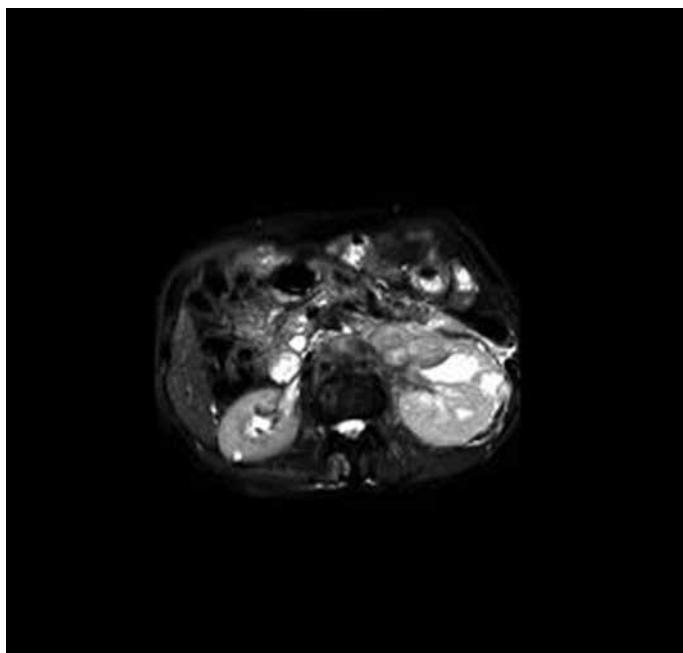


Figure 1. Axial magnetic resonance images with contrast infusion

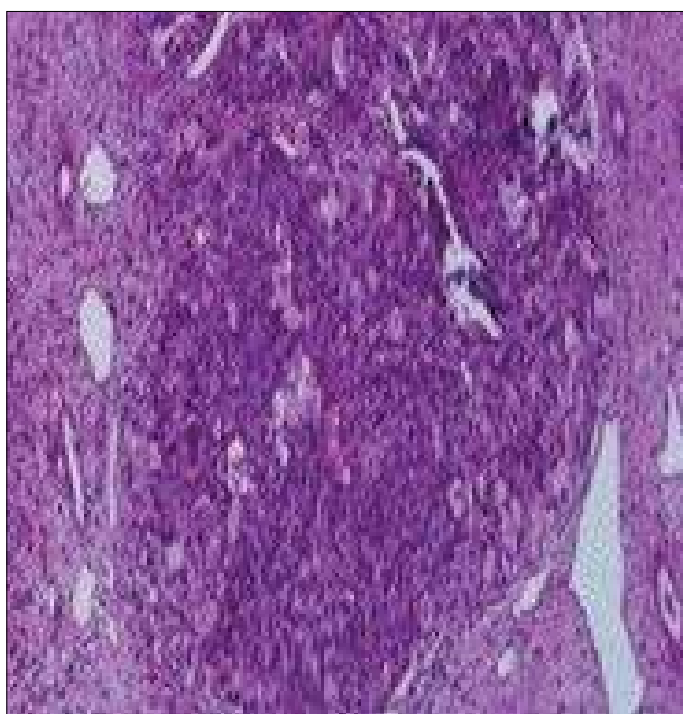


Figure 2. Malignant epithelial tumor infiltration forming vague glandular pattern in the histopathological examination of renal biopsy specimen

was given to lesion at left iliac region and symptomatic metastatic lesion of the bone. A marked regression was achieved in swelling and pain in the left lower extremity. Fine-needle aspiration biopsy

was performed for the mass lesion with suspect renal cell carcinoma. In the histopathological examination, malignant epithelial tumor infiltration with vague glandular pattern was observed (Figure 2). In immunohistochemistry, tumor tissue showed negative staining with cytokeratin 7, cytokeratin 20, cytokeratin 5/6, vimentin, inhibin and calretinin while positive staining with PSA. Weak positive staining with cluster of differentiation 10 (CD10) was observed. By evaluating histopathological features and immunohistochemical staining of the tumor, we decided that the lesion was metastasized from PCa.

Discussion

Lung cancers, breast cancers, melanoma, esophagus and colon cancers are the most common neoplasms that metastasize to kidney, resulting in large, solitary mass lesions.^[3] In the literature, there is limited number of case reports on renal tumor metastasized from prostate. The first premortem case of renal metastasis was presented by Kutcher et al.^[4] in 1986, in which diagnosis was made by fine-needle aspiration biopsy. Subsequently, Denti et al.^[3] reported a renal mass lesion located at left side which was detected by radiological evaluation. Authors performed biopsy from the mass lesion and histopathological examination and immunostaining study revealed prostate adenocarcinoma. In our case, we scheduled a biopsy from giant renal mass localized at the left side since fine-needle biopsy is a well-established diagnostic tool known to be safe and quick method.

In the report by Khan et al.^[5], prostate adenocarcinoma and left-sided renal mass (5.5 cm in size) compatible to renal cell carcinoma with extra-renal extension was described in a 66-year-old male patient. Authors considered primary and metastatic renal cell carcinoma, lymphoma and benign lesions including angio-myolipoma or oncocytoma in the initial differential diagnosis but biopsy revealed prostatic origin of the mass lesion. Higher grade of tumor differentiation and PSA value may be useful in predicting atypical metastases. In a study by Ibinaiye et al.^[6], a case which initially treated as having infected renal cyst was reported; however, later on the course of management, PSA value was found to be 150 ng/mL. The patient was diagnosed as renal metastatic lesion from prostatic adenocarcinoma by fine-needle biopsy.^[6] Similarly, Chen et al.^[7], presented a patient with Gleason score of 5+4 and PSA value of 36.801 μ g/L. The patient had not any abnormal finding on bone scan. In further evaluation, the lesion was incidentally detected in the left kidney which displayed diffusion invasion of retroperitoneal space, presumably leading to the misdiagnosis of lymphoma.^[7] However, biopsy revealed a metastatic renal tumor from PCa. Our case had PSA value of 114 ng/mL and Gleason score of 4+4 with bone metastasis alone at the time of diagnosis. We incidentally detected an invasive, retroperitoneal giant metastatic lesion (9x8.5x11 cm in size) and paraaortic lymph nodes 2 years after diagnosis. To the

best of our knowledge, this is the largest metastatic renal lesion which has been reported so far.

It is well-known that distant metastasis occurs via hematogenous or lymphogenous spread. It has been assumed that metastatic infiltration presumably results from arterial tumor embolization since kidney has a highly vascular structure.^[5] Interestingly, as far as we know in the literature renal metastasis from PCa always occurs at the left side. The underlying hematogenous or lymphogenous spread mechanisms are unknown therefore; further studies are needed in this issue.

Interventional angiography and embolization or radical surgery can be used in the management of patients with severe clinical symptoms. Survival rates reported in the literature range from 6 weeks to 18 months in patients with PCa and renal metastasis.^[5,8] Our patient was followed up by monthly intervals. Our case is still alive 5 months after diagnosis of renal metastasis.

In conclusion, atypical sites of metastases can be experienced in a small proportion of patients with advanced PCa; thus, it is essential to conduct metastasis work-up to rule out extra-skeleton metastasis. In patients with PCa, metastasis of primary tumor should be considered in case of renal mass lesion, particularly in those localized at the left side, and biopsy should be kept in mind for definitive diagnosis.

Informed Consent: Written informed consent was obtained from patient who participated in this case.

Peer-review: Externally peer-reviewed.

Author Contributions: Concept – N.K., S.R.; Design – N.K., S.R., S.K.; Supervision – N.K., S.R., S.K.; Resources – N.K., S.R.; Mate-

rials – N.K., S.R., S.K.; Data Collection and/or Processing – N.K., S.R., S.K.; Analysis and/or Interpretation – N.K., S.R., S.K.; Literature Search – N.K., S.R., S.K.; Writing Manuscript – N.K., S.K.; Critical Review – N.K., S.R., S.K.; Other – N.K., S.R., S.K.

Authors have no conflicts of interest to declare.

Financial Disclosure: The authors declared that this study has received no financial support.

References

1. Siegel RL, Miller KD, Jemal A. Cancer Statistics, 2017. *CA Cancer J Clin* 2017;67:7-30. [\[CrossRef\]](#)
2. Gandaglia G, Abdollah F, Schiffmann J, Trudeau V, Shariat SF, Kim SP, et al. Distribution of metastatic sites in patients with prostate cancer: A population-based analysis. *Prostate* 2014;74:210-6. [\[CrossRef\]](#)
3. Denti F, Wisard M, Guillou L, Francke ML, Leisinger HJ. Renal metastasis from prostatic adenocarcinoma: a potential diagnostic pitfall. *Urol Int* 1999;62:171-3. [\[CrossRef\]](#)
4. Kutcher R, Greenebaum E, Rosenblatt R, Moussouris HF. Prostatic carcinoma metastasis to the kidney: Diagnosis by thin needle aspiration biopsy. *Urol Radiol* 1986;8:98-100. [\[CrossRef\]](#)
5. Khan F, Mahmalji W, Sriprasad S, Madaan S. Prostate cancer with metastases to the kidney: a rare manifestation of a common disease. *BMJ Case Rep* 2013;2013:pii:bcr2012008388.
6. Ibinaiye PO, Mbibu H, Shehu SM, David SO, Samaila MO. Renal metastasis from prostate adenocarcinoma: a potential diagnostic pitfall. *Ann Afr Med* 2012;11:230-3. [\[CrossRef\]](#)
7. Chen C, He H, Yu Z, Qiu Y, Wang X. Renal and retroperitoneal metastasis from prostate adenocarcinoma: a case report. *World J Surg Oncol* 2016;14:74. [\[CrossRef\]](#)
8. Sakata R, Iwasaki A, Kobayashi M, Osaka K, Fujikawa A, Tsuchiya F, et al. Renal metastasis from prostate adenocarcinoma: a case report. *Hinyokika Kyo* 2011;57:683-7.