



Total tubeless ultra-mini supine percutaneous nephrolithotomy: A feasibility study

Sandeep Gupta , Susanta Kumar Das , Dilip Kumar Pal 

Cite this article as: Gupta S, Das SK, Pal DK. Total tubeless ultra-mini supine percutaneous nephrolithotomy: A feasibility study. Turk J Urol 2018; 44: 323-8.

ABSTRACT

Objective: The ultra-mini percutaneous nephrolithotomy (PCNL) for treating low-volume renal nephrolithiasis is being used as an alternative modality to the conventional PCNL. However its use in the supine position has been scarcely reported.

Material and methods: Patients who underwent ultra-mini PCNL in the supine position within the time frame of January 2017 to July 2017 were studied. All these patients had this as their first-line treatment. The patients had calculus limited to either a single calyx or just extending to the pelvis and the stone size was less than 2 cm in its maximal dimension. An 8.5 Fr operating nephroscope was used. The patients were positioned in the Galdakao modified Valdivia supine position. The stones were fragmented using Holmium-YAG laser. Various surgical outcomes including duration of the surgery, stone-free rate and any subsequent complications-if any-were analyzed.

Results: The study includes a series of 14 patients with 15 renal units (one patient treated with bilateral renal stone disease). The mean age of the patients was 39.07 years and body mass index was 25.5 kg/m². Intrarenal stone location was as follows: lower calyx, n=8; middle calyx, n=3, upper calyx, n=1, and pelvis, n=3. Median operative time was 52.66 min (range: 40-70) and the stone-free rate was 93.3%. Only one patient had residual fragments and needed subsequent extracorporeal shock wave lithotripsy.

Conclusion: Ultra-mini PCNL in supine position with a complete tubeless approach for renal stone disease is a safe method for treating low-volume disease. Studies with a larger cohort may be required to finally validate this technique.

Keywords: Galdakao modified Valdivia supine position; ultra-mini; percutaneous nephrolithotomy; total tubeless.

ORCID IDs of the authors:

S.G. 0000-0002-7647-3950;
S.K.D. 0000-0003-3293-154X;
D.K.P. 0000-0002-9356-642X.

Department of Urology,
Institute of Post Graduate
Medical Education and
Research, Kolkata, India

Submitted:
11.11.2017

Accepted:
05.03.2018

Correspondence:
Dilip Kumar Pal
E-mail:
urologyipgmer@gmail.com

©Copyright 2018 by Turkish
Association of Urology

Available online at
www.turkishjournalofurology.com

Introduction

Minimally invasive methods of treating renal calculi have been ever evolving with a balance between stone removal and procedural morbidity. Extracorporeal shock wave lithotripsy (ESWL), percutaneous nephrolithotomy (PCNL) and the retrograde intra-renal surgery (RIRS) have almost certainly replaced the age old modality of open surgical procedure for renal stones each one with its own pros and cons.

Percutaneous nephrolithotomy has a high stone-free rate and the procedure can be safely

performed by well-trained urologists with a shorter treatment time.^[1,2] Initially, mini-PERC technique was first developed for children and reported by Helal et al.^[3] With growing evidence of decrease in morbidity from PCNL with reduction in tract size^[4,5] the recent developments in PCNL is aimed towards creating a reduced tract size. This has led to the evolving of various minimally invasive PCNL (MIP) techniques.^[6,7] like the mini-PERC, the ultra-mini-PERC and the micro-PERC.

The ultra-mini-PCNL (UMP) is the latest inclusion in the MIP incorporating a 3.5 Fr telescope within a strategically devised 7.5 Fr nephro-

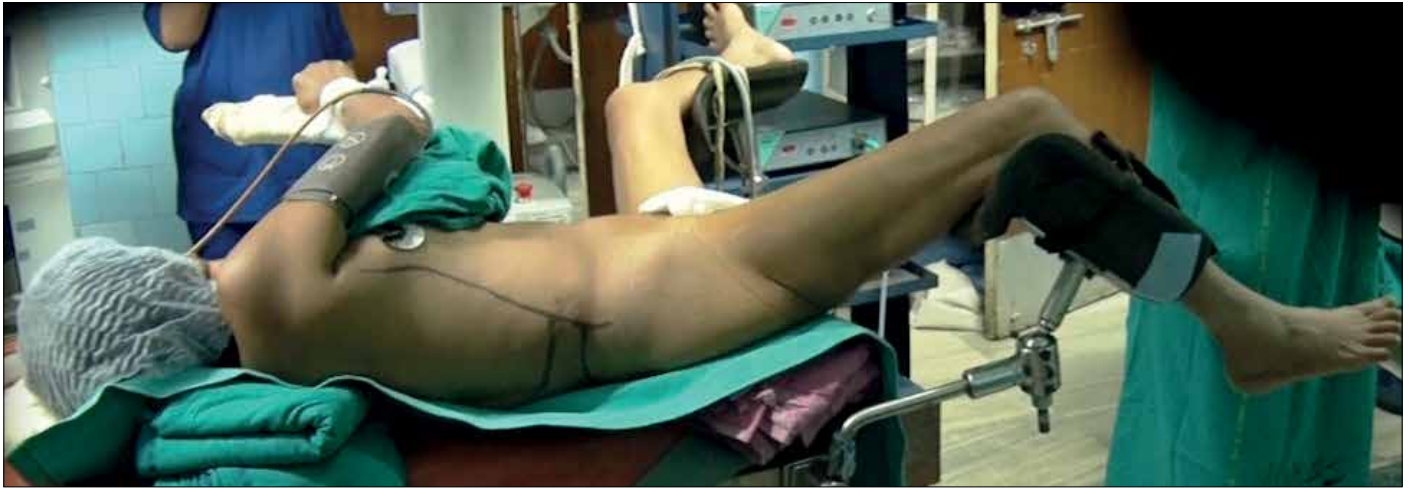

Figure 1. Galdakao modified Valdivia position

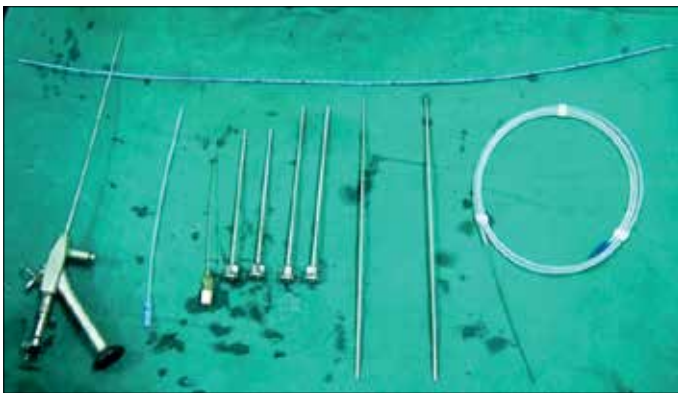


Figure 2. The ultra-mini nephroscope armamentarium

scope being introduced via the 11-13Fr sheath^[8] thus enabling a reduction in the invasiveness and subsequent complications of bleeding and trauma to the kidney.

Prone PCNL, although a standard, has its anesthetic concerns because of increased abdominal pressures thus making it unsuitable for morbidly obese patients and those with respiratory comorbidities.^[9]

The modified supine position provides an alternative approach with lower effect on the respiratory and circulatory physiology of the patient and better monitoring of the patient by the anesthesiologists with better option of changing to endotracheal intubation whenever required during the procedure.^[10,11]

In this study we aim to combine the beneficial effects of the MIP in the form of ultra-mini-PCNL along with advantages of supine position. To the best of our knowledge this is the first reported series of ultra-mini total tubeless PCNL being performed with the patient in the supine position.

Material and methods

This is a prospective interventional study among patients with nephrolithiasis with low-stone burden and undergoing supine total tubeless UMP as their first modality of treatment within the time frame of January 2017 and July 2017. The patients' inclusion criteria included: (1) stone size <20 mm; (2) body mass index (BMI) <30 kg/m²; (3) stone occupying a single calyx or extending into the pelvis; (4) favorable calyceal anatomy.

Initial detailed evaluation of the patients included a careful medical history and physical examination along with routine laboratory investigations (hemogram, renal function tests, serum electrolytes, sterile urine culture) and radiological investigations (digital intravenous pyelography and non-contrast computed tomography).

Ultra-mini-PCNL technique

The patients under general anesthesia were placed in the Galdakao modified Valdivia position (Figure 1).^[12,13] A 5 Fr ureteric catheter was passed into the ipsilateral ureteropelvic junction. The pelvicalyceal system (PCS) was opacified and the desired calyx (for best stone clearance) was selected for the initial puncture. An 18 G initial puncture needle was used for the percutaneous puncture of the desired calyx and a 0.035 hydrophilic guide wire was introduced into the PCS and gradually negotiated into the ureter. Tract dilatation was done up to 10 Fr and then an 11 Fr outer sheath of the 8.5 Fr ultra-mini nephroscope was introduced (Figure 2). Subsequently after withdrawing the guide wire, the nephroscope was introduced into the PCS up to the desired calculus. A 365 micron laser fiber was used for stone fragmentation and dusting (high frequency and low dose energy (0.6-0.8 Joule). The large fragments were expelled by the Bernoulli phenomenon with intermittent removals of the nephroscope out of the outer sheath.

Table 1. Details of patients along with perioperative outcomes

Sr. no	Age (yrs)	Sex	BMI (kg/m ²)	Laterality (R/L)	Size of stone (mm)	Stone location	Puncture time (min)	Dilation time (min)	Fragmentation time (mins)	Total procedural time (mins)	Hb drop (g/dL)
1	21	M	22	R	15	L	3	5	30	50	0.7
2	21	M	22	L	14	L	4	5	25	45	0.3
3	11	M	21	L	12	L	3	7	20	40	1.1
4	51	F	28	R	15	M	5	4	35	55	0.2
5	36	M	27	R	17	U	8	10	30	65	1.3
6	45	F	25	L	15	L	6	8	25	55	0.4
7	23	M	24	L	19	M	4	5	40	65	1
8	50	F	29	L	14	L	3	7	20	45	0.2
9	42	M	28	R	15	L	5	7	25	50	0.3
10	55	F	27	R	10	L	6	7	15	40	0.1
11	45	M	25	R	13	P	5	6	20	40	0.4
12	52	F	28	R	17	P	7	12	40	70	0.5
13	32	M	24	L	12	L	5	13	15	45	0.3
14	38	F	26	R	18	P	8	5	35	65	0.9
15	46	F	29	L	15	M	10	9	25	60	0.6

BMI: Body mass index; Hb: Hemoglobin; R: right; L: left

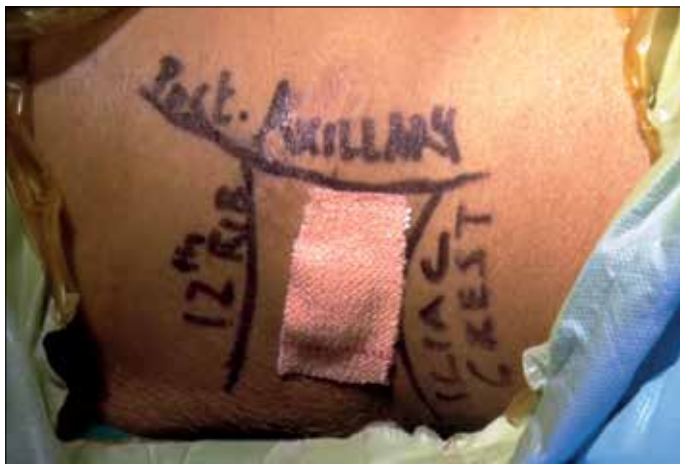

Figure 3. Post operative photo with the minimal compressive dressing over the puncture site.

After complete clearance of the stones, assessed by fluoroscopy, the nephroscope along with the outer sheath was removed and compressive dressing was applied. Neither nephrostomy tube nor any skin suture was required in any of the cases. Only compressive dressing was applied at the surgical site (Figure 3).

Postoperatively the patients were allowed to eat normal diet after twelve hours. For the first 48 hours the patient received intravenous antibiotics and a pain reliever (paracetamol).

Subsequently the patients were switched to oral medications. Postoperative urine cultures of all patients were obtained. Ureteral catheter was removed within 18-24 hours as a protocol for total tubeless procedure. A bedside ultrasonographic evaluation was done for all patients to look for any peri-renal collection.

Postoperative follow up

The patients were followed up with a digital X-ray KUB (kidney, ureter and bladder) and urine culture at 1 and 3 months. Stone clearance was defined by absence of residual radio-opaque shadow in the renal region or fragments which were asymptomatic and less than 4 mm in diameter (clinically insignificant residual fragments). The perioperative procedure related complications were classified according to the modified Clavien grading system.^[14]

Results

There were fourteen patients and fifteen kidney units that underwent supine ultra-mini-PCNL (one patient had bilateral PCNL) (Table 1). Two patients (13.3%) underwent the procedure under spinal anesthesia and general anesthesia was given to the rest of the patients. Among the fifteen units there were seven patients who were females (46%). The mean age of the patients was 39.07 years (range, 11-55). The mean BMI was 25.7kg/m². The right side was involved in eight cases and the rest had their left kidneys

with stones. Majority of the patients belonged to ASA Grade 1 except for four who belonged to ASA Grade 2. Eleven patients had symptoms attributable to their renal calculi and the rest had vague abdominal discomfort and their renal stones were detected during radiological examinations. All patients had UMP as their initial modality of therapy for renal calculi without any other previous therapeutic interventions. Among fifteen pelvicalyceal systems, eight (53.3%) had the stones were located in the lower calyx (n=8: 53.3%), the middle calyx (n=3: 20%), pelvis (n=3: 20%) and the upper calyx (n=1). The mean stone size was 14.7 mm (range, 12-19).

On an average, 1.7 (range 1-3) attempts were made to achieve initial puncture which took 5.4 minutes (range, 3-10) time. Median time periods required for dilatation, and laser fragmentation of the stones were 7.3 minutes (range, 4-13) and 26.6 minutes (range, 25-45), respectively. The total mean time of the procedure was 52.66 minutes (range, 40-70). There was a significant positive correlation between the higher stone burden and the increased duration of the procedure. However the number of puncture attempts and the total time taken for initial puncture of the desired calyx were not affected by the stone burden.

Postoperatively there was an average drop in hemoglobin of 0.55 mg/dL (range, 0.1-1.1) and this correlated positively with the increasing size of the stones. The median pain scores as assessed using the VAS were 3.06 (range, 2-5) at 1st hour and 2.56 (range, 1-4). At postoperative 12 hours of surgery. The average postoperative hospital stay was 2.8 days (range, 2-4).

Only one patient had urinary leakage after removal of the ureteral catheter that subsided within 24 hours with compressive dressing. None of the patients had any perirenal collections noted in bedside ultrasonographic evaluation at 24 hours after surgery. One patient had residual fragments detected during postoperative radiological investigation and the rest (93.3%) had complete stone clearance. The same patient had Clavein class I urosepsis that was treated with appropriate antibiotics. Subsequently, after controlling the infection, the patient had undergone shockwave lithotripsy for the removal of residual fragments.

Discussion

The high prevalence and increased frequency of recurrence has made urolithiasis a major worldwide problem among general population.^[15] Renal calculi form a major bulk among these patients. With time major advancements have been achieved in the minimally invasive management of renal stones.

Presently ESWL, PCNL, RIRS form the pillars of minimally invasive treatments of renal calculi certainly replacing the age old

modality of open surgical procedure. Each of these modalities has their own advantages and disadvantages. Principally, any surgical method for the treatment of renal calculi should offer high stone-free rate, minimal risk of hemorrhage and decrease procedural time for stone management.

Extracorporeal shock wave lithotripsy requires minimal anesthesia and is a relatively noninvasive method and hence, is well accepted method among patients. However a higher retreatment rate and higher incidence of residual fragments requiring additional procedures makes it an unpopular option among the urologists.^[16,17] Although RIRS has its advantage of minimal blood loss without visceral injury, yet its higher cost and maintenance of the flexible ureterorenoscopes are points of concern.^[18,19]

Percutaneous nephrolithotomy with its excellent stone clearance rates is a brilliant option for the treatment of renal stones especially staghorn calculi within a short time.^[20-23] The main concern, however, with PCNL is bleeding which can be seen in up to 23% of cases.^[24] Reducing the caliber of the access sheath decreases the damage to the renal parenchyma and hence reduces risk of bleeding. The question remains as to what is the adequate small size tract that is best suited for the PCNL procedure. On one side of the spectrum is the standard size 24Fr nephroscopes and on the other end microperc-PCNL performed through a 4.85 Fr tract size without using a working sheath as described by Desai et al.^[25] Mini PCNL lies somewhere in between these where a 12-14 Fr nephroscope is used in a 15-18 Fr amplatz sheath for addressing the renal calculi.

The recent modification by Desai et al.^[8] is the UMP. This uses a 3 Fr telescope in a 7.5 nephroscope which is introduced into the PCS via the 11-13 Fr size amplatz sheath. This decrease in the size of the tract has reduced the renal tissue trauma and the hemorrhagic complications associated with PCNL. UMP seems to be a safe and efficient option for small volume renal stones with good stone-free rates and decreased procedural complications. UMP is best suited for small to medium sized stones (usually <20 mm in diameter) and especially the lower pole stones and the diverticular stones which are difficult to gain access with the RIRS and those stones which are refractory to ESWL.^[26]

The other alternative approaches are the ESWL and RIRS. These have their own disadvantages. ESWL had a higher retreatment rate. Cho et al.^[27] had shown that the learning curve of RIRS requires about 100 cases. Also the sustainability of RIRS in many basic level hospitals is of question because of the associated cost factor and the durability of the flexible ureterorenoscopes along with the Holmium lasers.^[28,29]

Of course, the higher stone free rates along with miniaturization of the tract size in case of UMP makes it a plausible option for the treatment of renal stones especially stones which are less than 2 cm in size. The risk of bleeding is reduced together with the chances of urinary tract infections. When this is combined with the beneficial factors associated with supine position, it becomes a good option to treat renal calculi especially in patients with compromised cardiologic and respiratory status and in obese patients.

In all the cases total tubeless procedure was applicable wherein only the ureteric catheter was retained for less than 18-24 hours after the surgery and none of the patients required any skin sutures. This increases the satisfaction level of the patients since no additional procedures were required. The Holmium laser is an essential armamentarium in this technique. This technique utilizes the pulverization and the vaporization functions of the Holmium laser.^[30]

Desai et al.^[8] had reported a hematocrit drop of 1.4 mg/dL, a hospital stay of 1.2 days and a stone-free rate of 82% with UMP. In our series of supine UMP the average drop in hemoglobin was 0.55 mg/dL and the average hospital stay was 2.8 days. The average drop of hematocrit was minimal thus making it a safer option. The satisfaction among the patients as reflected indirectly from their lower post-procedural VAS scores is worth documenting. As a complication only a single event of urinary leak was documented in our case series which took about 24 hours to settle.

In conclusion, hence, total tubeless supine ultra-mini-PCNL is a feasible option to treat renal calculi especially those less than 2 cm in their longest dimension. We believe that this is a unique and good technique that can be undertaken safely. Studies with a larger cohort may be required to finally validate this technique.

Ethics Committee Approval: Ethics committee approval was received for this study from the ethics committee of IPGME&R, Kolkata (18.11.2017).

Informed Consent: Written informed consent was obtained from patients who participated in this study.

Peer-review: Externally peer-reviewed.

Author Contributions: Concept – S.G., S.K.D.; Design – S.K.D., D.K.P.; Supervision – S.G., S.K.D.; Resources – D.K.P.; Materials – S.G.; Data Collection and/or Processing – S.K.D.; Analysis and/or Interpretation – S.G., S.K.D.; Literature Search – S.K.D.; Writing Manuscript – S.K.D.; Critical Review – S.K.D., D.K.P.

Conflict of Interest: Authors have no conflicts of interest to declare.

Financial Disclosure: The authors have declared that they did not receive any financial support for this study.

References

1. Feng MI, Tamaddon K, Mikhail A, Kaptein JS, Bellman GC Prospective randomized study of various techniques of percutaneous nephrolithotomy. *Urology* 2001;58:345-50. [\[Crossref\]](#)
2. Kumar R, Anand A, Saxena V, Seth A, Dogra PN, Gupta NP Safety and efficacy of PCNL for management of staghorn calculi in pediatric patients. *J Pediatr Urol* 2011;7:248-51. [\[Crossref\]](#)
3. Helal M, Black T, Lockhart J, Figueroa TE. The Hickman peel-away sheath: alternative for pediatric percutaneous nephrolithotomy. *J Endourol* 1997;11:171-2. [\[Crossref\]](#)
4. Kukreja R, Desai M, Patel S, Bapat S, Desai M. Factors affecting blood loss during percutaneous nephrolithotomy: Prospective study. *J Endourol* 2004;18:715-22. [\[Crossref\]](#)
5. Ferakis N, Stavropoulos M. Mini percutaneous nephrolithotomy in the treatment of renal and upper ureteral stones: Lessons learned from a review of the literature. *Urol Ann* 2015;7:141-8. [\[Crossref\]](#)
6. Cheng F, Yu W, Zhang X, Yang S, Xia Y, Ruan Y. Minimally invasive tract in percutaneous nephrolithotomy for renal stones. *J Endourol* 2010;24:1579-82. [\[Crossref\]](#)
7. Mishra S, Sharma R, Garg C, Kurien A, Sabnis R, Desai M. Prospective comparative study of miniperc and standard PNL for treatment of 1 to 2 cm size renal stone. *BJU Int* 2011;108:896-9. [\[Crossref\]](#)
8. Desai J, Solanki R. Ultra-mini percutaneous nephrolithotomy (UMP): one more armamentarium. *BJU Int* 2013;112:1046-9. [\[Crossref\]](#)
9. de la Rosette JJ, Tsakiris P, Ferrandino MN, Elsakka AM, Rioja J, Preminger GM. Beyond prone position in percutaneous nephrolithotomy: A comprehensive review. *Eur Urol* 2008;54:1262-9. [\[Crossref\]](#)
10. Manohar T, Jain P, Desai M. Supine percutaneous nephrolithotomy: Effective approach to high-risk and morbidly obese patients. *J Endourol* 2007;21:44-9. [\[Crossref\]](#)
11. Liu L, Zheng S, Xu Y, Wei Q. Systematic review and meta-analysis of percutaneous nephrolithotomy for patients in the supine versus prone position. *J Endourol* 2010;24:1941-6. [\[Crossref\]](#)
12. Valdivia Uría JG, Valle Gerhold J, López López JA, Villarroya Rodríguez S, Ambroj Navarro C, Ramirez Fabián M, et al. Technique and complications of percutaneous nephroscopy: experience with 557 patients in the supine position. *J Urol* 1998;160:1975-8. [\[Crossref\]](#)
13. Ibarluzea G, Scoffone CM, Cracco CM, Poggio M, Porpiglia F, Terrone C, et al. Supine Valdivia and modified lithotomy position for simultaneous antegrade and retrograde endourological access. *BJU Int* 2007;100:233-6. [\[Crossref\]](#)
14. Dindo D, Demartines N, Clavien PA. Classification of surgical complications: a new proposal with evaluation in a cohort of 6336 patients and results of a survey. *Ann Surg* 2004;240:205-13. [\[Crossref\]](#)
15. Scales CD Jr., Smith AC, Hanley JM, Saigal CS and Urologic Diseases in America Project. Prevalence of kidney stones in the United States. *Eur Urol* 2012;62:160-5. [\[Crossref\]](#)
16. Albala DM, Assimos DG, Clayman RV, Denstedt JD, Grasso M, Gutierrez-Aceves J, et al. Lower pole I: A prospective randomized trial of extracorporeal shock wave lithotripsy and percutaneous

- nephrostolithotomy for lower pole nephrolithiasis-initial results. *J Urol* 2001;166:2072-80. [\[Crossref\]](#)
17. Srisubat A, Potisat S, Lojanapiwat B, Setthawong V, Laopaiboon M. Extracorporeal shock wave lithotripsy (ESWL) versus percutaneous nephrolithotomy (PCNL) or retrograde intrarenal surgery (RIRS) for kidney stones. *Cochrane Database Syst Rev* 2009; 11.
 18. Akman T, Binbay M, Ugurlu M, Kaba M, Akcay M, Yazici O, et al. Outcomes of retrograde intrarenal surgery compared with percutaneous nephrolithotomy in elderly patients with moderate-size kidney stones: A matched-pair analysis. *J Endourol* 2012;26:625-9. [\[Crossref\]](#)
 19. Bozkurt OF, Resorlu B, Yildiz Y, Can CE, Unsal A. Retrograde intrarenal surgery versus percutaneous nephrolithotomy in the management of lower-pole renal stones with a diameter of 15 to 20 mm. *J Endourol* 2011;25:1131-35. [\[Crossref\]](#)
 20. Srisubat A, Potisat S, Lojanapiwat B, Setthawong V and Laopaiboon M. Extracorporeal shock wave lithotripsy (ESWL) versus percutaneous nephrolithotomy (PCNL) or retrograde intrarenal surgery (RIRS) for kidney stones. *Cochrane Database of Systematic Reviews* 2009; CD007044.
 21. Sabnis RB, Jagtap J, Mishra S, Desai M. Treating renal calculi 1-2 cm in diameter with minipercutaneous or retrograde intrarenal surgery: A prospective comparative study. *BJU Int* 2012;110:346-9. [\[Crossref\]](#)
 22. Michel MS, Trojan L, Rassweiler JJ. Complications in percutaneous nephrolithotomy. *Eur Urol* 2007;51:899-906. [\[Crossref\]](#)
 23. Tefekli A, Karadag MA, Tepeler K, Sari E, Berberoglu Y, Baykal M, et al. Classification of percutaneous nephrolithotomy complications using the modified Clavien grading system: looking for a standard. *Eur Urol* 2008; 53:184-90. [\[Crossref\]](#)
 24. De la Rosette J, Assimos D, Desai M, Gutierrez J, Lingeman J, Scarpa R, et al. The clinical Research Office of the Endourological Society Percutaneous Nephrolithotomy Global study: Indications, complications, and outcomes in 5803 patients. *J Endourol* 2011; 25:11-7. [\[Crossref\]](#)
 25. Bader MJ, Gratzke C, Seitz M, Sharma R, Stief CG, Desai M. The "all-seeing needle": initial results of an optical puncture system confirming access in percutaneous nephrolithotomy. *Eur Urol* 2011;59:1054-9. [\[Crossref\]](#)
 26. Desai J, Zeng G, Zhao Z, Zhong W, Chen W, Wu W. A novel technique of ultra-mini-percutaneous nephrolithotomy: Introduction and an initial experience for treatment of upper urinary calculi less than 2 cm. *Biomed Res Int* 2013;2013:490793. [\[Crossref\]](#)
 27. Cho SY, Choo MS, Jung JH, Jeong CW, Oh S, Lee SB, et al. Cumulative sum analysis for experiences of a single-session retrograde intrarenal stone surgery and analysis of predictors for stone free status. *PLoS One* 2014;9:e84878.
 28. Preminger GM. Management of lower pole renal calculi: shock wave lithotripsy versus percutaneous nephrolithotomy versus flexible ureteroscopy. *Urol Res* 2006;34:108-11. [\[Crossref\]](#)
 29. Monga M, Best S, Venkatesh R, Ames C, Lee C, Kuskowski M, et al. Durability of flexible ureteroscopes: a randomized, prospective study. *J Urol* 2006;176:137-41. [\[Crossref\]](#)
 30. Campos-Salcedo J, Hernández-Martínez G, Terrazas-Ríos JL, Sedano-Lozano A, Castro-Marin M, López-Silvestre JC, et al. Usos y aplicaciones del láser holmium en endourología. *RevMex Urol* 2012;72:41-6.