



Response to duloxetine and gabapentin combination of a patient who has chronic orchialgia with bilateral tubular ectasia of rete testis and multiple epididymal cysts

Mahmut Taha Ölçücü¹ , Nazlı Ölçücü² , Erkan Ölçücüoğlu³ , Esin Ata Ölçücüoğlu⁴ , Yaşar Özgök⁵

Cite this article as: Ölçücü MT, Ölçücü N, Ölçücüoğlu E, Ata Ölçücüoğlu E, Özgök Y. Response to duloxetine and gabapentin combination of a patient who has chronic orchialgia with bilateral tubular ectasia of rete testis and multiple epididymal cysts. Turk J Urol 2018; 44(3): 274-7.

ABSTRACT

Tubular ectasia of rete testis (TERT) is a rarely seen benign condition of testis which can cause chronic orchialgia. TERT appears as an anechoic lesion in ultrasonography. However magnetic resonance imaging is a more sophisticated diagnostic tool. TERT is commonly associated with epididymal cysts. Generally a conservative treatment approach is preferred. In some cases surgery is required. In our case, 54-year-old male patient had bilateral TERT associated with bilateral multiple epididymal cysts. He had chronic testicular pain which did not respond to first-line conservative treatments. After use of duloxetine (60 mg PO) plus gabapentine (400 mg PO) combination as a second-line conservative treatment, the patient dramatically responded to this treatment. The patients who have chronic testicular pain caused by bilateral TERT and multiple epididymal cysts may be treated with combination of duloxetine (60 mg PO) plus gabapentine (400 mg PO) combination.

Keywords: Duloxetine plus gabapentin; epididymal cyst; rete testis; testicular pain; tubular ectasia

Introduction

Tubular ectasia of rete testis (TERT) was identified in 1992. TERT is a benign cystic condition of testis and observed generally in men over 55 years of age.^[1,2] An intratesticular area containing plenty of tight and anechoic (cystic) lesions is observed on ultrasonograms (USG). Lesions stemming from the testicular hilum, may be bilateral but they are generally asymmetrical.^[1,3] Commonly, TERT is associated with epididymal abnormalities (e.g. spermatocele, epididymal cysts or epididymitis), and cystic dysplasia of the testis and testicular cysts share a common location (within the mediastinum testis) with TERT.^[4] For further clarification of suspect lesions, magnetic resonance imaging (MRI) which has a higher diagnostic value than sonography may be used.^[5] There is no requirement

for a specific therapy for TERT, and especially surgery is not required for the treatment of TERT, so generally conservative approach is used.^[3,6] For the relief of chronic testicular pain spermatic cord blockage or microsurgical denervation of the spermatic cord may be performed.^[6] If all these attempts fail, orchiectomy may be considered.

Case presentation

Fifty-four-year-old male patient with previously treated episodes of epididymo-orchitis had bilateral testicular pain persisting for two years very rarely with painless intervals. Conservative treatment modalities like various pain killers, ice packs, suspensory underpants have been used without significant pain relief. Within the last 2 months his testicular pain persisted deteriorating his quality of life (QoL).

ORCID IDs of the authors:

M.T.Ö. 0000-0002-4721-2807;
N.Ö. 0000-0002-7285-510X;
E.Ö. 0000-0002-9101-5253;
E.A.Ö. 0000-0002-7883-6524;
Y.Ö. 0000-0003-3673-9643.

¹Department of Urology, Ağrı State Hospital, Ağrı, Turkey

²Department of Physical Therapy and Rehabilitation, Ağrı State Hospital, Ağrı, Turkey

³Department of Urology, Türkiye Yüksek İhtisas Training and Research Hospital, Ankara, Turkey

⁴Department of Radyology, Türkiye Yüksek İhtisas Training and Research Hospital, Ankara, Turkey

⁵Department of Urology, Çankaya Hospital, Ankara, Turkey

Submitted:
25.09.2017

Accepted:
08.11.2017

Available Online Date:
07.03.2017

Correspondence:
Mahmut Taha Ölçücü
E-mail:
matah_ol@hotmail.com

©Copyright 2018 by Turkish Association of Urology

Available online at
www.turkishjournalofurology.com

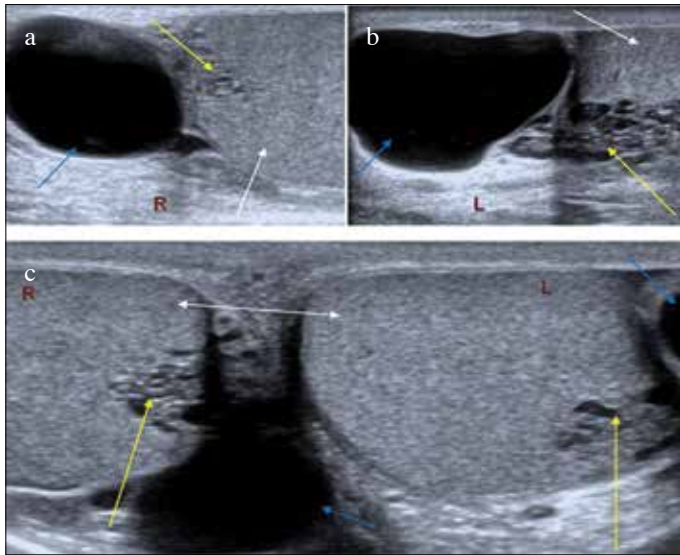


Figure 1. a-c. On scrotal ultrasonogram, normal testicular tissues (white arrows), epididymal cysts (blue arrows) and cystic dilations of rete testis (yellow arrows) are seen

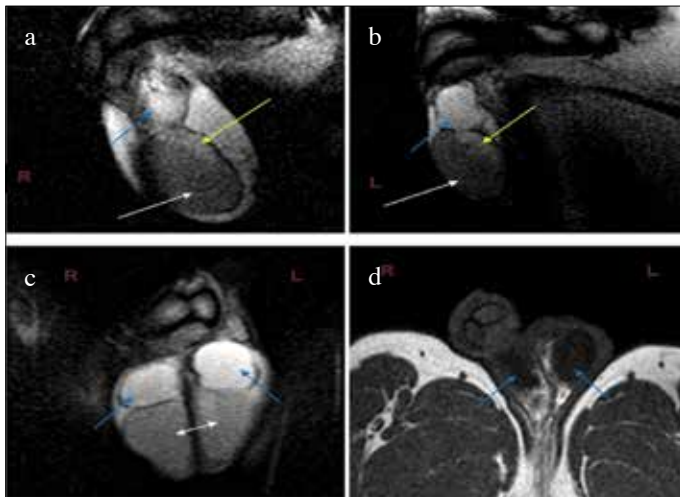


Figure 2. a-d. Scrotal MRI: normal testicular tissue (white arrows), epididymal cysts indicating peripheral hypointense, and hyperintense areas in T1AG, and T2AG (blue arrows) are observed, respectively. Besides at the level of testicular mediastinum, cystic dilations of rete testis indicating hypointense areas at T2AG (yellow arrows) are noticed

On physical examination (PE) palpation, and elevation of testicles did not elicit pain in both testis. Besides findings of epididymo-orchitis as swelling, erythema, and varicocele were not detected. Vas deferenses, and bilateral epididymal cysts could be palpated.

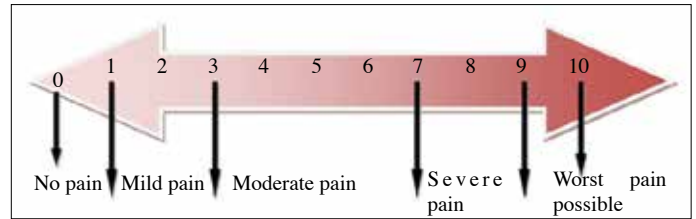


Figure 3. Visual analog scale

Drugs and Doses Used	VAS ^a before treatment	Period of drug therapy	VAS scores after treatment
Duloxetine 30 mg 1x1	7	4 weeks	6
Duloxetine 60 mg 1x1	7	4 weeks	6
Gabapentin 400 mg 1 x1	7	4 weeks	5
Duloxetine 60 mg + Gabapentin 400 mg 1x1	7	4 weeks	1

VAS: visual analogue scale

Figure 4. Assessment of patient's response to treatments based on VAS scores

Biochemical parameters as WBC, sedimentation rate, CRP, brucella tests, tumor markers, were within normal ranges. His spermogram did not reveal any abnormality. In USG (Figure 1) testes with regular contours containing echogenic areas formed by millimetric parenchymal cystic expansions compatible with TERT were observed. Anechoic areas compatible with multiple number of epididymal cysts with diameters varying between 27 and 30 mm were also noticed. Pathological reflux flow was not seen during US examination of bilateral pampiniform plexuses. Abdominal US findings were unremarkable.

Scrotal MR scanning provided more detailed delineation of bilateral multiple epididymal cysts and surrounding tissues. T2-weighted scrotal MR images obtained at the level of testicular mediastinum bilaterally demonstrated a slight signal increase at T2WI (Figure 2) which was compatible with TERT. Both epididymides were of normal size with multiple epididymal cysts demonstrating peripheral hypointense areas in T1AG, and hyperintense areas in T2AG.

We offered the patient conservative treatment alternatives for his testicular pain not given before including duloxetine and/or gabapentin which have been used frequently in the fields of neurology and/or physical therapy and rehabilitation (PTR) for the treatment of peripheral pain. The patient was informed about side effects of this long-lasting drug treatment which might not relieve his pain. Surgical options were also suggested to the patient. The patient was explicitly informed that

epididymal cysts could be excised but afterwards risk of testalgia may still persists. In addition the patient was informed about spermatic cord blockage or microsurgical denervation of the spermatic cord to be performed at an experienced center. The patient did not accept invasive interventions and requested conservative treatment.

Patient was evaluated by physical therapist, and a neurologist, and requested to define his severity of pain between 0, and 10 indicated on Visual Analog Scale (VAS) (Figure 3). His baseline VAS score was 7 points. Then maintenance of the treatment with duloxetine and gabapentin singly or in combination for 4 weeks was offered to the patient (Figure 4). Testicular pain of the patient decreased dramatically, and finally disappeared (final VAS score=1) with duloxetine (60 mg PO)-gabapentin (400 mg PO) combination treatment after 4 weeks. Occasionally, he felt slight, and short-lasting (only 1 min) pain which did not affect his QoL (Figure 4). We advised him to continue this treatment for 6 months, then taper and finally discontinue under the control of PTR and neurology. The patient stated that he had no pain at one, and 3 months after withdrawal of this drug treatment.

Discussion

Urologists rarely encounter chronic testicular pain which currently presents itself as a diagnostic and therapeutic challenge.^[7,8] Primarily chronic *epididymo-orchitis*, tumors, hydrocele, spermatocele, varicocele, indirect inguinal hernia may cause testicular pain or testalgia which may manifest itself as referred pain stemming from ureteral stone, chronic prostatitis or degenerative lesions of lumbar spines.

Ultrasonography is a very important modality for the definitive diagnosis of TERT. Testicular neoplasms and intratesticular varicocele must be considered in differential diagnosis. Cystic testicular tumors are generally painless and detected when levels of tumor-specific markers increase.

Hot pat applications, nerve blocks, tricyclic antidepressants, anticonvulsants such as gabapentin, phytotherapy, anxiolytics, narcotics, acupuncture, steroid injection therapy, analgesics, scrotal elevation, bed rest, and nonsteroidal anti-inflammatory drugs may be used for nonspecific conservative therapy for men with idiopathic chronic testicular pain.^[6,7] Chronic testicular pain refractory to most of the conservative approaches in our patient, who also declined surgery could be only explained by bilateral epididymal cysts associated with TERT.

Some patients with chronic testicular pain respond to duloxetine or gabapentin monotherapies. Currently, their combination have been found to be more effective in relieving chronic testicular pain as is the case with some peripheral neuropathies.^[9,10] Thus we prescribed duloxetine-gabapentin combination for our patient to be used for 6 months. After discontinuation of this drug treatment, complaints of the patient disappeared completely.

To the best of our knowledge this is the first case report of a patient whose chronic testicular pain caused by bilateral TERT associated with bilateral multiple epididymal cysts has been completely taken under control with gabapentin and duloxetine combination.

Informed Consent: Written informed consent was obtained from the patient.

Peer-review: Externally peer-reviewed.

Author Contributions: Concept – M.T.Ö., Y.Ö.; Design – M.T.Ö., E.A.Ö.; Supervision – M.T.Ö., Y.Ö., E.Ö.; Resources – M.T.Ö., N.Ö.; Materials – M.T.Ö., E.Ö.; Data Collection and/or Processing – M.T.Ö., N.Ö.; Analysis and/or Interpretation – M.T.Ö., N.Ö., E.Ö., E.A.Ö., Y.Ö.; Literature Search – M.T.Ö., N.Ö.; Writing Manuscript – M.T.Ö.; Critical Review – E.Ö., Y.Ö.; Other – N.Ö., E.A.Ö.

Conflict of Interest: No conflict of interest was declared by the authors.

Financial Disclosure: The authors declared that this study has received no financial support.

References

1. Dogra VS, Gottlieb RH, Rubens DJ, Liao L. Benign intratesticular cystic lesions: US features. *Radiographics* 2001;21:S273-81.
2. Nair R, Abbaraju J, Rajbabu K, Anjum F, Sriprasad S. Tubular ectasia of the rete testis: a diagnostic dilemma. *Ann R Coll Surg Engl* 2008;90:W1-3.
3. Mahlkecht A, Mahlkecht P, Fallaha M, Wieser A. Tubular ectasia of the rete testis (TERT). Differential diagnosis of cystic testicular disorders. *Arch Ital Urol Androl* 2015;87:5-7.
4. Fawzy MA, Kelly BE, Johnston SR. Cystic dilatation of the rete testis. *Ulster Med J* 2001;70:59-60.
5. Nagler-Reus M, Guhl L, Volz C, Wuerstlin S, Arlart IP. Magnetic resonance tomography of the scrotum. Experiences with 129 patients. *Radiologe* 1995;35:494-503.
6. Kavoussi PK, Costabile RA. Orchialgia and the chronic pelvic pain syndrome. *World J Urol* 2013;31:773-8.
7. Levine L. Chronic orchialgia: evaluation and discussion of treatment options. *Ther Adv Urol* 2010;2:209-14.

8. Singh V, Sinha RJ. Idiopathic chronic orchialgia - a frustrating issue for the clinician and the patient. *Indian J Surg* 2008;70:107-10.
9. Tanenberg RJ, Irving GA, Risser RC, Ahl J, Robinson MJ, Skljarevski V, et al. Duloxetine, pregabalin, and duloxetine plus gabapentin for diabetic peripheral neuropathic pain management in patients with inadequate pain response to gabapentin: an open-label, randomized, noninferiority comparison. *Mayo Clin Proc* 2011;86:615-26.
10. Tanenberg RJ, Clemow DB, Giaconia JM, Risser RC. Duloxetine Compared with Pregabalin for Diabetic Peripheral Neuropathic Pain Management in Patients with Suboptimal Pain Response to Gabapentin and Treated with or without Antidepressants: A Post Hoc Analysis. *Pain Pract* 2014;14:640-8.