



# Long term follow up of proximal hypospadias repair-urethral stricture should be excluded in adults who present with epididymo-orchitis

Kailas P. Bhandarkar , Dinesh H. Kittur , Santosh V. Patil , Sudhakar S. Jadhav 

**Cite this article as:** Bhandarkar KP, Kittur DH, Patil SV, Jadhav SS. Long term follow up of proximal hypospadias repair-urethral stricture should be excluded in adults who present with epididymo-orchitis. Turk J Urol 2018; 44(2): 162-5.

## ABSTRACT

**Objective:** Epididymo-orchitis (EO) is a well-known complication of urinary tract infections (UTI) in children. This is commonly seen in children who had hypospadias repair or in those who had surgery for ano-rectal malformation especially when it results in urethral stricture. However EO occurring as a complication of urethral stricture in adults operated for hypospadias in childhood is not well documented in the literature.

**Material and methods:** This is a retrospective review of four adults who had proximal hypospadias repair in childhood. All four men presented to us with EO. They were thoroughly investigated to rule out presence of urethral stricture.

**Results:** Three patients had urethral stricture of which two responded well to dilatation and one required cystoscopy and visual internal urethrotomy. The fourth patient did not have urethral stricture. EO in this patient is thought to be due to excessive straining during micturition causing reflux into seminal vesicles.

**Conclusion:** Urethral stricture should be excluded in any adult who had a hypospadias repair and presents with EO. Urethral strictures after hypospadias surgery respond well to dilatation and to endoscopic urethrotomy.

**Keywords:** Anorectal malformation; epididymo-orchitis; hypospadias; urethral stricture; urinary tract infection.

Department of Urology, Ege University School of Medicine, Izmir, Turkey

**Submitted:**  
27.05.2017

**Accepted:**  
13.11.2017

**Available Online Date:**  
05.01.2018

**Correspondence:**  
Kailas P. Bhandarkar  
E-mail:  
drbhandarkar@hotmail.com

©Copyright 2018 by Turkish Association of Urology

Available online at  
www.turkishjournalofurology.com

## Introduction

Patients with urinary tract infections (UTI) are known to have reflux into the seminal vesicles. They may present with epididymo-orchitis (EO) and scrotal abscess. Paediatric surgeons commonly face this problem in clinical practice whenever there is a voiding disturbance along with UTI. This is commonly encountered in patients with Anorectal malformation<sup>[1,2]</sup> or patients after hypospadias repair<sup>[2,3]</sup> both of whom can present with urethral stricture. EO after hypospadias repair has to be looked into seriously, since this may be a subtle sign of

urinary outflow obstruction and therefore point to an underlying urethral stricture. This obstruction is most likely at the meatus or at the junction of the native urethra and neo-urethra.

## Material and methods

Four adult patients who presented with EO and who had repair of proximal hypospadias in early childhood were studied. Informed Consent was taken from all patients. Institutional Ethics committee approval was taken for the purpose of the study and was granted. Individual patient characteristics are

outlined in Table 1. All of them complained of a weak stream with no improvement on straining. All four reported attacks of UTI and EO and were treated medically. They underwent urinary profile studies which included routine urine examination, blood urea and creatinine. During clinical examination, the condition of the meatus and the dilatation of the repaired urethra and any scarring were noted. The patient's voiding pattern was studied. They were given a laxative for evacuation of the bowel, and asked to void without straining. When a continuous urinary flow was noticed, they were asked to strain and any change in caliber and force of urinary flow was noted. All the four patients had voiding cystourethrography (VCUG) and two patients (patient number 1 and 3) had retrograde urethrography as well which was done elsewhere. All patients were administered a laxative and simple enema prior to the examination to empty the rectum. VCUG was done by direct bladder puncture under local anesthesia. This was done to avoid any spasm in the urethra which could vitiate our findings. Clinical findings, urinary flow study and the results of radiological examination were correlated. Retrograde urethrogram in patient number one and three showed the urethral stricture at the junction of native and neourethra with dilatation of the native urethra and reflux of contrast into the seminal vesicles (Figure 1). VCUG of patients one, two and three showed stricture between the native and neourethra. VCUG of Patient four showed dilatation of distal neo-urethra and normal proximal native urethra and absence of urethral stricture (Figure 2).

## Results

Out of four patients, three were diagnosed with urethral stricture which was present at the junction of the native and neo-urethra. Two patients responded well to urethral dilatation. The third patient needed cystoscopy which revealed a tight stricture. Endoscopic Internal urethrotomy was done and a catheter was left in place as a stent for seven days. Patient number four had no evidence of urethral stricture. We counseled him against undue straining while passing urine. We decided to observe him closely without any intervention. All patients are doing well and are regularly being followed up. Follow up has ranged from six months to four years (a median follow up of one year).

## Discussion

Urinary tract infections and EO can occur in children with proximal hypospadias as well as in children operated on for hypospadias.<sup>[2,3]</sup> This should alert the clinician about a possible underlying cause of obstruction to the flow of urine and retrograde infection. The patient needs to be investigated for the same after about 6 weeks following an acute attack of UTI or EO. An acute scrotum may need scrotal exploration to rule out testicular torsion<sup>[3]</sup> as happened in our patient number three. EO can be diagnosed by clinical examination and also by scrotal ultrasound.<sup>[4]</sup> EO can lead to scrotal abscess formation and testicular loss as well.<sup>[3,5]</sup> Recurrent UTI may

**Table 1. Showing individual patient characteristics**

Sl	Age	Symptoms	Retrograde urethrogram	Voiding cystourethrogram	Diagnosis	Surgical treatment and result	Follow up
1	18 years	Poor stream. UTI,EO	Stricture at Junction of native and neourethra Reflux into the seminal vesicles	Dilated native urethra. Stricture at Junction of native and neourethra	Urethral stricture	Urethral dilatation twice with improvement in stream.	1 yr.
2	22 years	Weak stream. UTI, EO. had urethral dilation done thrice.	Not done	Dilated native urethra. Stricture at Junction of native and neourethra	Urethral stricture	Urethral dilatation Stream improved	1 yr.
3	20 years	UTI, EO	Scrotal exploration Stricture at Junction of native and neourethra Reflux into the seminal vesicles	Native urethral dilatation. Urethral stricture.	Urethral stricture	Dilatation done on four occasions-no relief. Visual internal urethrotomy. Stream improved.	4 yrs.
4	18 years	Weak stream. UTI, EO Meatotomy done in past.	Not done	Normal native urethra. Neourethra dilated.	No stricture	Assurance. Asked not to strain during micturition.	6 mo.

UTI: urinary tract infections; EO: epididymo-orchitis; yr: years

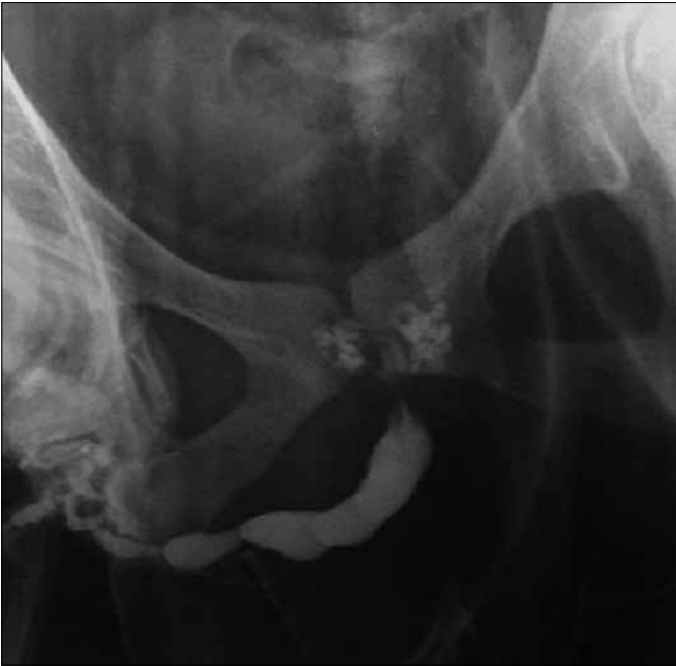

Figure 1. Retrograde urethrogram in patient number one and three showed the urethral stricture at the junction of native and neourethra with dilatation of the native urethra and reflux of contrast into the seminal vesicles

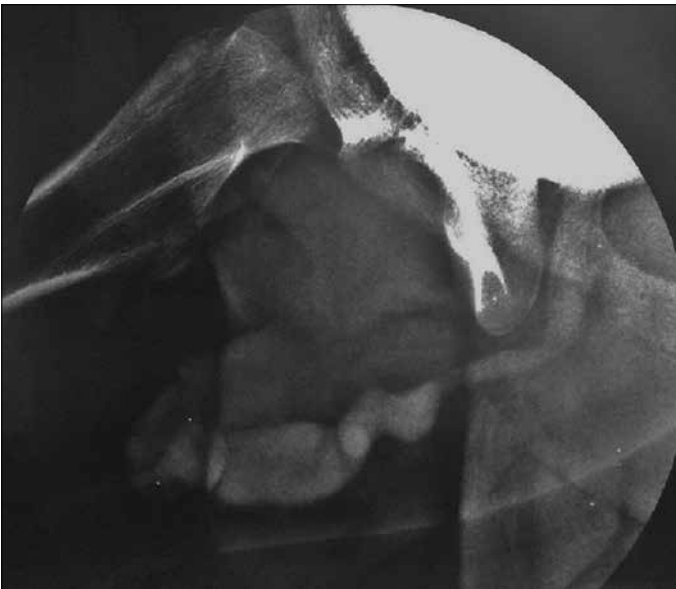


Figure 2. VCUG of Patient four shows dilatation of distal neourethra and normal proximal native urethra and absence of urethral stricture

be due to presence of a prostatic utricle<sup>[6]</sup> which is commonly associated with proximal hypospadias. Urethral strictures after hypospadias repair can be effectively treated by endoscopic urethrotomy.<sup>[7]</sup>

We believe that the most important aspect to be noted in the follow-up of patients with hypospadias repair is the nature and caliber of urinary stream. Though older boys usually complain about weak stream or straining, this is difficult to assess in younger children unless noticed by parents. Whenever there is doubt about undue straining during urination, the clinician must convince himself by watching the urinary stream and note any change in caliber on straining. It is easy to diagnose meatal stenosis, since most patients report a powerful but narrow jet which goes for an undue long distance, along with a bulge on the ventral side of the penis. But a narrowing of the repaired urethra or stenosis at the junction of the native and neo-urethra is not easy to diagnose clinically. This is suspected when a weak stream is not affected on straining. Before doing a VCUG, we always confirm that the rectum is empty. Most adult patients are co-operative, so we prefer to puncture the full bladder under local anesthesia for the VCU. We believe that the urethra may go into spasm if catheter is introduced per urethrally. It may also be injured during catheterization especially if there is an underlying stricture.

The clinical impression during the act of micturition and the VCU have to be interpreted keeping Laplace law of fluid mechanics in mind.<sup>[8]</sup> If there is a stricture at the junction of the native urethra and the neo-urethra, the proximal urethra will dilate and straining may increase the caliber of urinary stream. In hypospadias, there is lack of spongiosum. Post repair, the neourethra could dilate because of this lack of spongiosal support. This would result in increase flow velocity in the neo-urethra during micturition with the resultant drop in pressure giving an impression of a poor stream.

In our first three patients, dilatation of the proximal urethra with narrowing at the junction of proximal and neourethra was diagnostic of urethral stricture. The first two patients responded well to urethral dilatation and reported a good stream while passing urine with a full bladder. The third patient had repeated dilatation elsewhere, without much relief. Cystoscopy revealed a urethral stricture. So he was treated with endoscopic urethrotomy. VCUG study in patient four revealed a normal caliber proximal urethra but dilated neourethra, with a wide stream without any narrowing. There was no meatal stenosis. On straining the stream showed no change in caliber. It was concluded that he did not have urethral stricture. He has been counselled to avoid undue straining which will hopefully prevent reflux into the seminal vesicles, thereby decreasing the chances of UTI and EO. All patients are kept on close follow up and are symptom free.

There are several studies which address the short term complications of hypospadias. These studies have concentrated on

complications like urethral fistula, meatal stenosis, dehiscence of repairs and redo hypospadias.<sup>[9,10]</sup> Spinoit et al.<sup>[11]</sup> agree that long term follow up is mandatory in hypospadias patients. Our study is not only a long term follow up study of children with proximal hypospadias repair but also probes into complications of urethral stricture in adult life namely, UTI and EO. To our knowledge this is the first study reporting EO as a complication of urethral stricture in adults who had proximal hypospadias repair in childhood.

In conclusion, a regular follow up for patients operated for proximal hypospadias is necessary to evaluate the caliber of urinary stream. An attack of EO should alert the clinician to investigate the patient to rule out a treatable underlying cause like urethral stricture or meatal stenosis. We feel that it is important to witness the act of micturition and effect of straining on urinary stream. Clinical findings along with a VCUG and a retrograde urethrogram when necessary, will help in deciding the line of treatment. This can avoid surgical intervention in a few who do not have an underlying urethral stricture. We believe that all children who had their proximal hypospadias repair should have long term follow up as adults. An attack of EO and UTI should direct the investigations to rule out possible urethral stricture as an underlying cause.

**Ethics Committee Approval:** Ethics committee approval was received for this study from the ethics committee of Sushrut Jadhav Kinderchirurgie Charitable Trust's Paediatric Surgery Centre and PG Institute (October 2016).

**Informed Consent:** Written informed consent was obtained from all patients who participated in this study.

**Peer-review:** Externally peer-reviewed.

**Author Contributions:** Concept – K.P.B., S.V.P., D.H.K.; Design – K.P.B., D.H.K.; Supervision – S.V.P., S.S.J.; Resources – D.H.K., S.S.J.; Materials – K.P.B., D.H.K.; Data Collection and/or Processing – K.P.B., D.H.K., S.V.P.; Analysis and/or Interpretation - K.P.B., S.V.P., D.H.K., S.S.J.; Literature Search – K.P.B., D.H.K.; Writing Manuscript – K.P.B., D.H.K.; Critical Review – S.V.P., S.S.J.; Other – K.P.B., D.H.K., S.V.P., S.S.J.

**Acknowledgements:** The authors would like to thank Dr Yogesh Tiwari and Dr Aamir Iqbal (residents) and Mr Mohsin Mujawar for technical assistance in preparing the manuscript.

**Conflict of Interest:** No conflict of interest was declared by the authors.

**Financial Disclosure:** The authors declared that this study has received no financial support.

## References

1. Zaccara A, Ragozzino S, Iacobelli BD, Rivosecchi F, Capitanucci ML, Mosiello G, et al. Epididymo-orchitis and anorectal malformations: when and in whom? *Pediatr Surg Int* 2015;31:305-9. [\[CrossRef\]](#)
2. Ramareddy RS, Alladi A. Scrotal abscess: Varied etiology, associations, and management. *J Indian Assoc Pediatr Surg* 2016;21:164-8. [\[CrossRef\]](#)
3. Muraoka I, Ohno Y, Kanematsu T, Hayashi T, Satomi A. Acute scrotum caused by vasitis with abscess formation in children with lower urological anomalies. *Urology* 2010;76:49-52. [\[CrossRef\]](#)
4. Fehily SR, Trubiano JA, McLean C, Teoh BW, Grummet JP, Cherry CL, et al. Testicular loss following bacterial epididymo-orchitis: Case report and literature review. *Can Urol Assoc J* 2015;9:3-4. [\[CrossRef\]](#)
5. Redshaw JD, Tran TL, Wallis MC, deVries CR Epididymitis: a 21-year retrospective review of presentations to an outpatient urology clinic. *J Urol* 2014;192:1203-7. [\[CrossRef\]](#)
6. Jiwanee A, Soundappan SV, Pitkin J, Cass DT. Successful treatment of recurrent epididymo-orchitis: Laparoscopic excision of the prostatic utricle. *J Indian Assoc Pediatr Surg* 2009;14:29-30. [\[CrossRef\]](#)
7. Ballanger P, Midy D, Vely JF, Ballanger R. Results of endoscopic urethrotomy in the treatment of urethral stricture. Apropos of 72 cases. *J Urol* 1983;89:95-9.
8. Douglas J, Gaiorek J, Swalfeld J. Laplace law. In: Douglas et al, editors. *Fluid Mechanics*. 5th Ed London: Pearson Education; 2009. p. 368-9.
9. Ziada AM, Morsi H, Aref A, Elsaied W. Tubularized incised plate (TIP) in previously operated (redo) hypospadias. *Journ Pediatr Urol* 2006;2:409-14. [\[CrossRef\]](#)
10. Bar-Yosef Y, Binyamini J, Matzkin H, Ben-Chaim J. Salvage Mathieu urethroplasty: reuse of local tissue in failed hypospadias repair. *Urology* 2005;65:1212-5. [\[CrossRef\]](#)
11. Spinoit AF, Poelaert F, Groen LA, Van Laecke E, Hoebeke P. Hypospadias repair at a tertiary care center: long-term follow up is mandatory to determine the real complication rate. *J Urol* 2013;189:2276-81. [\[CrossRef\]](#)