










Efficacy of antegrade and retrograde warm saline pyeloperfusion during renal cryoablation for ureteral preservation

Renal kriyoablasyon sırasında yapılan antegrad ve retrograd sıcak salinle piyeloperfüzyonun üreterin korunmasına etkisi

Benjamin West¹ , Mohamed Keheila¹ , Jason C. Smith² , Alexander Erskine¹ , Samuel R. Abourbih¹ , Nazih Khater¹ , D. Duane Baldwin¹ 

Cite this article as: West B, Keheila M, Smith JC, Erskine A, Abourbih SR, Khater N, Baldwin DD. Efficacy of antegrade and retrograde warm saline pyeloperfusion during renal cryoablation for ureteral preservation. Turk J Urol 2018; 44(2): 142-7.

ABSTRACT

Objective: Cryoablation of renal tumors adjacent to the ureter or pelvicalyceal system carries risks for thermal injury of the collecting system. Although cold antegrade perfusion has been described for radiofrequency ablation, warm saline perfusion for renal cryoablation has not been well-characterized. The purpose of this study was to determine the safety and feasibility of antegrade and retrograde warm saline perfusions during percutaneous renal cryoablation.

Material and methods: A retrospective review was performed on 136 patients treated with percutaneous renal cryoablation at a single academic institution between 2009 and 2015. Six patients undergoing antegrade (n=3) or retrograde (n=3) warm saline perfusion for protection of the collecting system were identified. Warm saline was perfused through a 4 French nephrostomy tube in the antegrade technique and through a 6 French end-hole catheter in the retrograde technique. Outcome measures were tumor recurrence rates, success of urothelial preservation, hospital stay, blood loss and procedural time.

Results: Four tumors were in the lower pole and two tumors in the middle pole. The mean distance from tumor to ureter was 6.8 mm (0.8-11.5 mm) and no patient developed ureteral stricture. There was no tumor recurrence at a median follow-up of 37.3 months (7-65). The median procedural time was 3 hours and 13 minutes. One patient in each group developed minor complications (Clavien I and II) and there were no major complications.

Conclusion: This study demonstrates the feasibility of antegrade and retrograde warm saline perfusion for ureteral preservation during cryoablation, without compromising oncologic outcomes.

Keywords: Cryoablation; perfusion; renal cell carcinoma; stricture; ureter.

ÖZ

Amaç: Üreter veya pelvikalisial sisteme yakın böbrek tümörlerinin kriyoablasyonu topluyucu sisteme termal hasar riski taşır. Radyofrekans ablasyonu için soğuk antegrad perfüzyon tanımlanmışsa da renal kriyoablasyon için sıcak salin perfüzyonu tanımlanmamıştır. Bu çalışmanın amacı perkütan renal kriyoablasyon sırasında antegrad ve retrograd sıcak salin perfüzyonunun güvenlik ve uygulanabilirliğini belirlemektir.

Gereç ve yöntemler: Tek bir akademik kurumda 2009 ile 2015 yılları arasında perkütan renal kriyoablasyonla tedavi edilmiş 136 hastada retrospektif bir inceleme yapılmıştır. Toplayıcı sistemin korunması amacıyla 3 hasta antegrad ve 3 hasta da retrograd sıcak salin perfüzyonu uygulanmıştır. Antegrad teknikte sıcak salin 4 Fr nefrostomi tübü, retrograd teknikte ise 6 Fr terminal ucu delikli kateter içinden verilmiştir. Tümörün rekürens hızı, ürotelyal dokunun korunmasındaki başarı, hastanede yatış, kan kaybı ve işlem süresine ilişkin sonuçlar elde edilmiştir.

Bulgular: Dört tümör alt ve iki tümör orta poldaydı. Tümörden üretere ortalama mesafe 6,8 mm (0,8-11,5 mm) idi. Hiçbir hastada üreter darlığı gelişmedi. Ortalama 37,3 (7-65 ay) aylık takipte tümör rekürensisi yoktu. Ortalama işlem süresi 3 saat 13 dakika idi. Her bir gruptan bir hastada minör komplikasyonlar gelişmişti (Clavien I ve II) ve önemli bir komplikasyon yoktu.

Sonuç: Bu çalışma onkolojik sonuçları riske atmaksızın kriyoablasyon sırasında üreterin korunması için antegrad ve retrograd ılık salin perfüzyonunun uygulanabilir olduğunu göstermektedir.

Anahtar sözcükler: Kriyoablasyon; perfüzyon; renal hücreli karsinoma; darlık; üreter.

¹Department of Urology, Loma Linda University School of Medicine, California, USA

²Department of Radiology, Loma Linda University School of Medicine, California, USA

Submitted:
31.05.2017

Accepted:
23.08.2017

Available Online Date:
21.12.2017

Correspondence:
D. Duane Baldwin
E-mail:
Dbaldwin@llu.edu

©Copyright 2018 by Turkish Association of Urology

Available online at
www.turkishjournalofurology.com

Introduction

In patients who are surgical candidates, partial nephrectomy is becoming the gold standard for the treatment of small renal masses (<4 cm).^[1,2] With the current trend toward minimally-invasive surgery, these partial nephrectomies are now commonly performed through either laparoscopic or robotic approaches.^[3,4] However, in an aging population with increasing comorbidities, some patients are not surgical candidates and thermal ablation has been offered as an acceptable alternative.^[5]

Radiofrequency ablation (RFA) and cryoablation create sharply delineated areas of high or low temperature respectively, to induce tumor cell necrosis. Although thermal ablation has the advantage of being both a minimally-invasive and nephron-sparing approach, one complication of these techniques is thermal injury to the ureter or renal pelvis which may occur during the ablation of an adjacent tumor.^[6] Ureteral stricture may occur in up to 25% of the cases during ablation of tumors within 1 cm of the ureter.^[7]

Previous studies have shown the efficacy of using either cold saline or 5% dextrose to perfuse the pelvicalyceal system during RFA to prevent thermal injuries.^[8,9] While there is only one study that reported the efficacy of retrograde warm pyeloperfusion during cryoablation,^[10] no study has examined an antegrade approach. The objective of this study is to report the safety and efficacy of a clinical series of both antegrade and retrograde warm pyeloperfusion during cryoablation.

Material and methods

After institutional review board (ethics committee) approval, the medical records of 136 patients undergoing percutaneous renal cryoablation at a single tertiary center between 2009 and 2015 were retrospectively reviewed. Informed consent was waived due to the retrospective nature of the study. From this series, six patients underwent warm saline pyeloperfusion (3 antegrade, and 3 retrograde) for the protection of the collecting system during percutaneous cryoablation. In our institution cryoablation is used in patients that are not surgical candidates due to limiting comorbidities, tumor location, or in rare cases, patient preference. The indication for warming pyeloperfusion was an intraprocedural renal mass less than 15 mm away from the ureter/ureteropelvic junction (UPJ).

Patient demographics, tumor size and tumor location were reported according to pre-procedural computed tomography (CT) imaging. Procedure time and estimated blood loss were recorded and serum creatinine changes were determined the day after the procedure. Complications were graded according to the Clavien-Dindo classification system and were further divided into minor (Clavien I and II) and major (Clavien III-V) complications.^[11]

Failure of urothelial preservation was defined as the appearance of ureteral stricture or hydronephrosis during follow-up cross sectional imaging. Residual or recurrent tumor presence was defined as any enhancing renal mass on follow-up imaging. The protocol for follow-up included an initial CT scan or magnetic resonance imaging with and without contrast at 3 months to evaluate for complete ablation of the tumor. If the imaging showed complete ablation without hydronephrosis, and the pathology revealed a grade 1 or 2 tumor, repeat imaging was performed at postprocedural 6 months. If this second imaging study was normal further follow-up was performed at yearly intervals. If cross-sectional imaging revealed questionable enhancement or other abnormality, or if the tumor was of high grade, more frequent imaging procedures were performed.

Percutaneous cryoablation was performed in standard fashion under IV moderate sedation by a team consisting of a fellowship-trained interventional radiologist (JCS) and an endourologist (DDB), using the Endocare™ system under CT guidance (Endocare™ Inc., Irvine, CA, USA).^[12] Two 10-minute freeze cycles were applied separated by an 8 minute passive thaw cycle. Imaging was taken at 5-minute intervals to monitor the ice-ball formation with the goal of ensuring that lethal ice covered the tumor while preserving the ureter.

Antegrade pyeloperfusion was performed under intermittent CT guidance by placement of either a 20- or 21-gauge Chiba needle (Cook Medical Inc., Bloomington, IN, USA) into a suitable posterior calyx or the renal pelvis. Upon aspiration of urine, the Chiba needle was then exchanged with an inner 4 Fr sheath of a non-vascular introducer set over a Cope Mandril wire (Cook Medical Inc., Bloomington, IN, USA). Next, the tip was placed in the pelvicalyceal system and the external portion of the catheter was secured to the flank.

One liter normal saline IV bags were heated in a microwave until they were warm to touch and could be held without discomfort (approximately 38-40 degrees C). The warmed saline was then hung 1.5 meters above the patient and perfused by continuous gravity drainage into the renal collecting system while the cryoablation probes were in use (Figure 1a). One case of antegrade pyeloperfusion required manual injection of warm saline after it was noted at the end of the first freeze cycle that the catheter had frozen shut. The catheter was recanalized during the thaw cycle, the gravity drip was discontinued and warm saline was subsequently injected manually.

Retrograde pyeloperfusion was conducted using a 6 Fr open-ended catheter placed inside the ureter to instill warm saline to the proximal collecting system (Figures 1b and c). The stent was placed cystoscopically in the CT suite in one patient, and using fluoroscopy prior to entering the CT suite in 2 patients. Warm

saline was injected continuously before and during the use of the cryoablation probes and a Foley catheter was placed in both patient groups. Since the urinary collecting system was entered

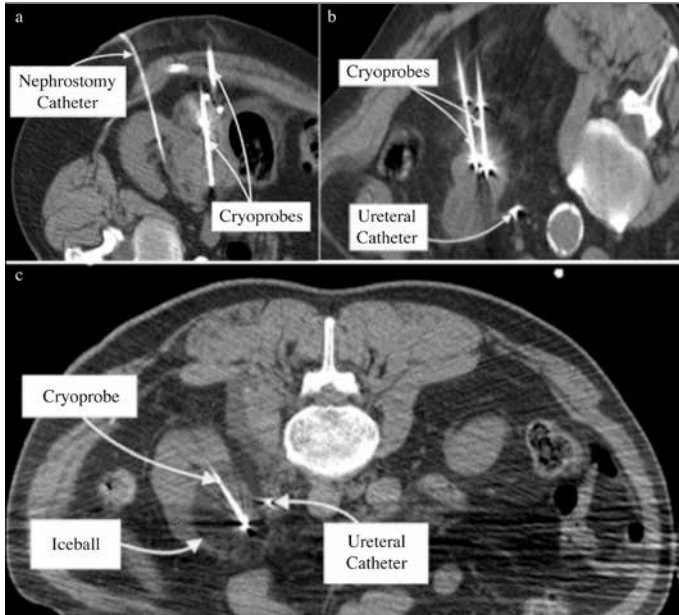


Figure 1. a-c. Antegrade nephrostomy catheter infusing the renal pelvis, with cryoprobe also visible (a). Retrograde perfusion method with catheter in ureter visible beside the renal mass (b, c), with ice ball formation (c)

during pyeloperfusion, empiric broad-spectrum prophylactic antibiotics were routinely administered.

Statistical analysis

The patients were divided into two groups according to the technique of pyeloperfusion (antegrade vs. retrograde). Statistical analysis was performed using the Student's t-test for continuous variables and Fisher's exact test for categorical variables. Statistical Package for the Social Sciences Statistics (IBM SPSS, Armonk, NY, USA) was used for statistical analysis with $p < 0.05$ considered statistically significant.

Results

Six patients underwent pyeloperfusion during percutaneous cryoablation. Four patients were male and 2 were female. Patient demographics and tumor characteristics are reported in Table 1. Intra-procedurally the median tumor size was 3.1 cm (2.1-3.9 cm) and median distance from the tumor to the ureter/ureteropelvic junction (UPJ) region was 6.8 mm (0.8-11.5 mm). Three patients underwent antegrade and three patients retrograde pyeloperfusions. Median procedural time for all patients was 3 hours and 13 minutes. Comparison of the mean procedural times between the retrograde and antegrade groups revealed no significant difference ($p=0.98$). Serum creatinine increased by a mean of 13% on the day following the procedure, but returned to baseline levels by 4 months follow-up. There were

Table 1. Patient demographics and tumor characteristics. Distances to the ureter/UPJ region were recorded intra-procedurally

Pt. No.	Age	Sex	BMI kg/m ²	Biopsy results	Size (cm)	Location	Distance to Ureter/UPJ Region (mm)
1	72	M	23.6	RCC	2.5	Left mid-pole	11.5
2	73	F	33.2	RCC	3.1	Right mid-pole	3.5
3	80	M	25.2	RCC	3.7	Right lower pole	9.5
4	69	M	34.7	Oncocytoma	3.1	Right lower pole	10.2
5	69	M	27.8	RCC	2.1	Left lower pole	0.8
6	75	F	20.3	RCC	3.9	Left lower pole	5.5

BMI: body mass index; UPJ: ureteropelvic junction; RCC: renal cell carcinoma

Table 2. Peri-procedural and post-procedural outcomes

Pt. No.	Pyelo-perfusion	Time (min)	EBL	Hospital Stay	Complications	F/U (months)	Tumor Recurrence
1	Antegrade	134	None	1 day	None	65	None
2	Antegrade	162	None	1 day	None	25	None
3	Antegrade	283	None	1 day	Urine leak	64	None
4	Retrograde	143	None	5 days	PE on PPD 1	54	None
5	Retrograde	290	None	1 day	None	9	None
6	Retrograde	143	None	2 days	None	7	None

EBL: estimated blood loss; F/U: follow-up; PE: pulmonary embolism; PPD 1: post-procedure day 1

no intra-procedural complications, no significant blood loss was noted and no transfusion was required (Table 2). There was no statistical difference in the length of hospital stay between the two groups ($p=0.23$).

None of the patients developed tumor recurrence at an average follow-up of 37.3 months (7-65) (Table 1). Histopathological evaluation of the masses showed renal cell carcinoma (RCC) in 5 and oncocytoma in 1 patient (Table 2). There were two post-procedural complications, including one patient who suffered a self-limited urine leak at the site of the antegrade perfusion (Clavien I), which was managed expectantly and resolved on post-procedure day 1. The second complication occurred in a patient who suffered a pulmonary embolism the day following surgery (Clavien II), and was discharged after 5 days of anticoagulation therapy. There was no statistical difference between the complication rates in those who underwent antegrade versus retrograde pyeloperfusion ($p=1.0$). Follow-up imaging confirmed that no patients developed ureteral strictures or hydronephrosis.

Discussion

An aging population and a rising incidence of RCC in recent years have served as the impetus for further development of minimally invasive therapies.^[13] Partial nephrectomy is the current standard of care for healthy patients with small renal masses (<4 cm), while percutaneous thermal ablation is utilized in patients who are not surgical candidates.^[12,5] As the prevalence of obesity and comorbidities increases, ablative technologies are increasingly utilized.^[14] Techniques that spare the urinary collecting system could expand the applications and improve the safety of ablative technologies.^[15]

In a multi-institutional review by Johnson and associates, the complication rate following ablation of small renal masses was 11.1%.^[16] In addition, close proximity of the tumor to the ureter is considered a relative contraindication for ablation of renal masses due to the concern of thermal urothelial injury.^[5] Gervais et al.^[7] showed that RFA of renal masses within 1 cm of the ureter have the greatest risk of ureteral stricture (25%), although masses within 1-2 cm are still at a 10% risk for injury. Compared to RFA, effects of cold temperature on the ureter have not been as well classified, but in a canine model, direct cryoablation of the ureter caused stricture and obstruction.^[17] Clinical cases of ureteral stricture after renal cryoablation have been also reported, and indicated that ureteral damage is a serious complication of cryoablation of renal masses.^[18]

To reduce the incidence of ureteral stricture in cryoablation of renal masses in close proximity to the collecting system, three previous strategies have been employed. Froemming et al.^[19] reported the use of a manual retraction technique in three patients,

in which a cryoprobe was fixed to the tumor with a small ice ball. The probe was then used to gently manipulate the tumor away from the ureter. One drawback to this approach was that the surgeon has to keep his hand on the probe throughout the cryoablation to maintain retraction, and during CT monitoring of iceball formation. A second technique that has been reported is hydrodisplacement to move the ureter away from the ablation site. There is minimal data supporting this method as only a single case has been reported in the literature.^[20]

Pyeloperfusion, a technique of infusing saline into the ureter, is the third option reported for protecting the renal collecting system during thermal ablation. In 2002, the principle of pyeloperfusion was firstly demonstrated during partial nephrectomy to achieve renal parenchymal hypothermia by the retrograde instillation of cold saline.^[21] Subsequently, Schultze et al.^[22] successfully adapted cold pyeloperfusion to protect the ureter during a single case of radiofrequency ablation of RCC. Similarly, Cantwell et al.^[8] prospectively demonstrated similar results using retrograde injection of chilled 5% dextrose solution.

Whereas cold solutions are infused during RFA, Wah et al.^[10] recently reported the safety and efficacy of retrograde perfusion of warm (36-38°C) saline (200-300 cc) during renal cryoablation ($n=5$). Despite the trial's success, only retrograde pyeloperfusion was examined. In contrast, our study is the first to report the efficacy of antegrade warm pyeloperfusion.

Through physical contact with tissue, the freezing cryoablation probe removes heat via conduction. The extent of cellular injury caused by cryoablation is governed by four factors: rate of freezing, target temperature, time at target temperature and rate of thawing.^[23] When tissues are rapidly frozen, intracellular ice crystals form, disrupting normal organelle and plasma membranes and causing immediate necrosis. With slower freezing, less intracellular water is trapped within the cell and fewer lethal intracellular ice crystals form. Even though the cell may dehydrate and shrink, upon returning to normal body temperature, the cell rehydrates and has a greater chance of survival than cells in which intracellular crystals had formed. The rationale behind the perfusion of warm saline is that it might prevent damage to the ureter by slowing the rate of freezing, thus decreasing the amount of intracellular ice crystals that form and decreasing the time that the urothelial tissue spends at the target temperature. One theoretical drawback to warm pyeloperfusion is that tumors immediately adjacent to the ureter may receive potential protection from the cold probe, though this has not been reported to date.^[10]

Functionally, antegrade pyeloperfusion can be performed in the CT suite which does not require fluoroscopy, patient repositioning or any additional procedures, making it an efficient and valuable addition to the standard protocol of percutaneous

cryoablation. In addition, patients who have urethral stricture or who have undergone urinary diversion are not candidates for retrograde pyeloperfusion. In these patients, as well as those in which localization of the ureteral orifice is difficult due to an orthotopic bladder or reimplanted ureter, antegrade pyeloperfusion provides a useful alternative method for warm saline pyeloperfusion. These factors, as well as physician's preference and equipment availability, are likely key determinants in deciding to use antegrade versus retrograde perfusion.

It is important to note that in our study, the indication for warm pyeloperfusion was determined based on the proximity of the tumor to the pelvicalyceal system as determined intra-procedurally. Compared to the pre-ablation scans taken in the supine position, it was noted that distances decreased between the tumor and the pelvicalyceal system in all patients when they were positioned prone for ablation. Whereas distances that ranged from 6 to 20 mm on the preablation scan decreased to 0.8 to 11.5 mm when measured intra-procedurally which indicates that the intra-procedural distance must be considered when deciding whether pyeloperfusion is indicated. In patients whose preablation scans did not indicate the need for pyeloperfusion, but the tumor had shifted closer to the ureter/UPJ region on intra-procedural scans, antegrade perfusion was preferred to retrograde perfusion out of convenience, due to the patient's prone positioning.

In our series, urine leak was reported in one patient in the antegrade pyeloperfusion group. Urinary extravasation noted on intra-procedurally performed imaging, was asymptomatic, and the patient was discharged with unchanged creatinine levels on postprocedural day 1. A single patient in the retrograde pyeloperfusion group developed a pulmonary embolism in the absence of deep vein thrombosis. The incidence rates of pulmonary embolism as a complication of percutaneous renal tumor ablation were 3% and 0.5% in two prior clinical series.^[24,25] This particular patient had a BMI of 34.7 kg/m² that may have contributed to the risk for embolus formation. This was likely unrelated to the pyeloperfusion performed during the cryoablation procedure.

One inherent limitation to this study is that it was a retrospective trial, which is subject to all the limitations of a retrospective analysis. Additionally, the number of patients undergoing pyeloperfusion is modest and larger prospective trials will be required to confirm the findings of our study. In addition, this trial was performed using a team consisting of an interventional radiologist highly skilled in percutaneous access and an endourologist highly skilled in retrograde stent placement. It is possible that surgeons in other centers may not achieve equal success with both techniques. The data from this study show that there is no difference in the complication rates between antegrade and retrograde pyeloperfusion, indicating that both are efficacious options for use during cryoablation.

In conclusion, this study demonstrates that antegrade or retrograde warm saline pyeloperfusion is both effective ways of protecting the collecting system and should be considered during percutaneous cryoablation of renal masses in close proximity to the ureter.

Ethics Committee Approval: Ethics committee approval was received for this study from the ethics committee of Loma Linda University.

Informed Consent: Informed consent was waived due to the retrospective nature of the study.

Peer-review: Externally peer-reviewed.

Author Contributions: Concept – D.D.B., J.C.S.; Design – A.E., B.W., D.D.B., N.K., J.C.S.; Supervision – D.D.B., M.K., N.K., S.R.A.; Resources – D.D.B., M.K., J.C.S.; Materials – M.K., S.R.A., N.K., J.C.S.; Data Collection and/or Processing – A.E., B.W., N.K.; Analysis and/or Interpretation – A.E., B.W., M.K., D.D.B., S.R.A., N.K. Literature Search – B.W., A.E.; Writing Manuscript – B.W., M.K., N.K.; Critical Review – B.W., J.C.S., D.D.B., A.E., S.R.A., M.K., N.K.; Other – M.K., S.R.A.

Conflict of Interest: No conflict of interest was declared by the authors.

Financial Disclosure: The authors declared that this study has received no financial support.

Etik Komite Onayı: Bu çalışma için etik komite onayı Loma Linda Üniversitesi'nden alınmıştır.

Hasta Onamı: Retrospektif çalışma olması nedeniyle hasta onamı alınmamıştır.

Hakem Değerlendirmesi: Dış bağımsız.

Yazar Katkıları: Fikir – D.D.B., J.C.S.; Tasarım – A.E., B.W., D.D.B., N.K., J.C.S.; Denetleme – D.D.B., M.K., N.K., S.R.A.; Kaynaklar – D.D.B., M.K., J.C.S.; Malzemeler – M.K., S.R.A., N.K., J.C.S.; Veri Toplanması ve/veya İşlemesi – A.E., B.W., N.K.; Analiz ve/veya Yorum – A.E., B.W., M.K., D.D.B., S.R.A., N.K.; Literatür Taraması – B.W., A.E.; Yazıyı Yazan – B.W., M.K., N.K.; Eleştirel İnceleme – B.W., J.C.S., D.D.B., A.E., S.R.A., M.K., N.K.; Diğer – M.K., S.R.A.

Çıkar Çatışması: Yazarlar çıkar çatışması bildirmemişlerdir.

Finansal Destek: Yazarlar bu çalışma için finansal destek almadıklarını beyan etmişlerdir.

References

1. Campbell SC, Novick AC, Belldegrun A, Blute ML, Chow GK, Derweesh IH, et al. Guideline for management of the clinical T1 renal mass. *J Urol* 2009;182:1271-9. [[CrossRef](#)]
2. Campbell SC, Uzzo RG, Allaf ME, Bass EB, Cadeddu JA, Chang A, et al. Renal Mass and Localized Renal Cancer: AUA Guideline. *J Urol* 2017;198:520-9. [[CrossRef](#)]

3. Kaul S, Laungani R, Sarle R, Stricker H, Peabody J, Littleton R, et al. Da Vinci-Assisted Robotic Partial Nephrectomy: Technique and Results at a Mean of 15 Months of Follow-Up. *Eur Urol* 2007;51:186-92. [\[CrossRef\]](#)
4. Choi JE, You HJ, Kim DK, Rha HK, Lee SH. Comparison of Perioperative Outcomes Between Robotic and Laparoscopic Partial Nephrectomy: A Systematic Review and Meta-analysis. *Eur Urol* 2015;67:891-901. [\[CrossRef\]](#)
5. Zargar H, Atwell TD, Cadeddu JA, de la Rosette JJ, Janetschek G, Kaouk JH, et al. Cryoablation for Small Renal Masses: Selection Criteria, Complications, and Functional and Oncologic Results. *Eur Urol* 2016;69:116-28. [\[CrossRef\]](#)
6. Atwell TD VJ, Boorjian SA. Percutaneous cryoablation of stage T1b renal cell carcinoma: technique considerations, safety, and local tumor control. *J Vasc Interv Radiol* 2015 26:792-9. [\[CrossRef\]](#)
7. Gervais DA, McGovern FJ, Arellano RS, McDougal WS, Mueller PR. Radiofrequency ablation of renal cell carcinoma: part 1, Indications, results, and role in patient management over a 6-year period and ablation of 100 tumors. *Am J Roentgenol* 2005;185:64-71. [\[CrossRef\]](#)
8. Cantwell CP, Wah TM, Gervais DA, Eisner BH, Arellano R, Uppot RN, et al. Protecting the ureter during radiofrequency ablation of renal cell cancer: a pilot study of retrograde pyeloperfusion with cooled dextrose 5% in water. *J Vasc Interv Radiol* 2008;19:1034-40. [\[CrossRef\]](#)
9. Eswara JR, Gervais DA, Mueller PR, Arellano RS, Cantwell CP, McGovern FJ. Renal radiofrequency ablation with pyeloperfusion. *Int J Urol* 2015;22:131-2. [\[CrossRef\]](#)
10. Wah TM, Cartledge J. Retrograde warm pyelo-perfusion for protection of the ureter during image-guided cryoablation of central renal cell carcinoma: a prospective evaluation. *Biomed Imaging Interv J* 2013;9:1-5.
11. Clavien PA, Barkun J, de Oliveira ML, Vauthey JN, Dindo D, Schulick RD, et al. The Clavien-Dindo classification of surgical complications: five-year experience. *Ann Surg* 2009;250:187-96. [\[CrossRef\]](#)
12. Gupta A, Allaf ME, Kavoussi LR, Jarrett TW, Chan DY, Su LM, et al. Computerized tomography guided percutaneous renal cryoablation with the patient under conscious sedation: initial clinical experience. *J Urol* 2006;175:447-52. [\[CrossRef\]](#)
13. Gunn AJ, Gervais DA. Percutaneous Ablation of the Small Renal Mass-Techniques and Outcomes. *Semin Intervent Rad* 2014;31:33-41. [\[CrossRef\]](#)
14. Woldrich JM, Palazzi K, Stroup SP, Sur RL, Parsons JK, Chang D, et al. Trends in the surgical management of localized renal masses: thermal ablation, partial and radical nephrectomy in the USA, 1998-2008. *Brit J Urol Int* 2013;111:1261-8. [\[CrossRef\]](#)
15. Yang G, Villalta JD, Meng MV, Whitson JM. Evolving practice patterns for the management of small renal masses in the USA. *Brit J Urol Int* 2012;110:1156-61. [\[CrossRef\]](#)
16. Johnson DB, Solomon SB, Su LM, Matsumoto ED, Kavoussi LR, Nakada SY, et al. Defining the complications of cryoablation and radio frequency ablation of small renal tumors: a multi-institutional review. *J Urol* 2004;172:874-7. [\[CrossRef\]](#)
17. Bagley DH, Terrill R, Javadpour N, Beazley RM. Cryosurgery of the ureter in dogs. *Invest Urol* 1976;14:241-5.
18. Littrup PJ, Ahmed A, Aoun HD, Noujaim DL, Harb T, Nakat S, et al. CT-guided percutaneous cryotherapy of renal masses. *J Vasc Interv Radiol* 2007;18:383-92. [\[CrossRef\]](#)
19. Froemming A, Atwell T, Farrell M, Callstrom M, Leibovich B, Charboneau W. Probe retraction during renal tumor cryoablation: a technique to minimize direct ureteral injury. *J Vasc Interv Radiol* 2010;21:148-51. [\[CrossRef\]](#)
20. Bodily KD, Atwell TD, Mandrekar JN, Farrell MA, Callstrom MR, Schmit GD, et al. Hydrodisplacement in the percutaneous cryoablation of 50 renal tumors. *Am J Roentgenol* 2010;194:779-83. [\[CrossRef\]](#)
21. Landman J, Venkatesh R, Lee D, Vanlangendonck R, Morissey K, Andriole GL, et al. Renal hypothermia achieved by retrograde endoscopic cold saline perfusion: technique and initial clinical application. *Urology* 2003;61:1023-5. [\[CrossRef\]](#)
22. Schultze D, Morris CS, Bhave AD, Worgan BA, Najarian KE. Radiofrequency ablation of renal transitional cell carcinoma with protective cold saline infusion. *J Vasc Interv Radiol* 2003;14:489-92. [\[CrossRef\]](#)
23. Erinjeri JP, Clark TW. Cryoablation: mechanism of action and devices. *J Vasc Interv Radiol* 2010;21:S187-91. [\[CrossRef\]](#)
24. Chen JX, Guzzo TJ, Malkowicz SB, Soulen MC, Wein AJ, Clark TWI, et al. Complication and Readmission Rates following Same-Day Discharge after Percutaneous Renal Tumor Ablation. *J Vasc Interv Radiol* 2016;27:80-6. [\[CrossRef\]](#)
25. Schmit GD, Atwell TD, Leibovich BC, Callstrom MR, Kurup AN, Woodrum DA, et al. Percutaneous cryoablation of anterior renal masses: technique, efficacy, and safety. *Am J Roentgenol* 2010;195:1418-22. [\[CrossRef\]](#)