



A rare case of lobulated complete renal fusion with multiple hila and vasculature

Multipl hilum ve damarlanmalı seyrek görülen bir lobüle komplet renal füzyon olgusu

Prasanna LC, Aparna Varma, Huban R. Thomas, Antony Sylvan Dsouza

Cite this article as: LC P, Varma A, Thomas HR, Dsouza AS. A rare case of lobulated complete renal fusion with multiple hila and vasculature. Turk J Urol 2017; 43(4): 571-5.

ABSTRACT

Complete renal fusion without crossed renal ectopia denotes the medial fusion of the renal parenchyma (with or without changes in the microarchitecture) in the pelvis with anteriorly placed short ureters terminating into the bladder. This could be due to the failure of renal analgen to ascent, lateral migration, axial rotation, and persistence of primitive vascular supply. Though remain asymptomatic such cases warrant concomitant congenital anomalies of other organ systems as well as the microarchitecture changes in the renal parenchyma.

Keywords: Cake kidney; pelvic kidney; renal ectopia; renal mass.

ÖZ

Çapraz renal ektopinin eşlik etmediği komplet renal füzyon böbreğin mikro yapısında değişiklikler olsun veya olmasın pelviste böbrek parankiminin mediyal füzyonuyla birlikte mesane içinde sonlanan anterior yerleşimli kısa üreterleri ifade eder. Bu durum renal analgenin yükselişini, dışyana göçünü, eksenli etrafındaki rotasyonunu gerçekleştirememesine ve primitif damarsal yapının sebat etmesine bağlı olabilir. Semptom vermemelerine rağmen bu olguların eşlik eden diğer organ sistemlerinin doğuştan anomalileri ve böbrek parankimi mikro yapısındaki değişiklikler açısından değerlendirilmeleri gerekir.

Anahtar Kelimeler: Kek böbreği; pelvik böbrek; renal ektopi; renal kitle.

Introduction

Complete renal fusion (cake or pancake or lump kidney) without crossed renal ectopia is the rarest form of congenital renal anomaly with an estimated frequency of 2% of all fused kidney types and an incidence of 1/65000 to 1/375000 cases.^[1,2] The term cake (pancake) denotes the medial fusion of the renal parenchyma (with or without changes in the microarchitecture) in the pelvis without an intervening septum.^[2] The fused renal mass is often lobulated on the anterior surface and smooths in the posterior aspect. Usually, in such cases, the complex renal hilum is placed anteriorly with anteriorly placed short ureters and normal urinary bladder. Such a rare congenital anomaly could be due to many developmental

sequential events such as an abnormal ureteric bud or metanephric blastema and/failure of ascent of renal analgen, lateral migration, axial rotation, and persistence of primitive vascular supply.^[3] The present case should be distinguished from the ‘crossed renal ectopia’ where the fused kidneys with crossed ureters or the ‘solitary kidney’ where a single ureter draining into the bladder are observed.^[2] Renal fusion anomalies are frequently associated with vesicoureteral reflux (70%) and anomalies of genital (15-75%), skeletal (50%), cardiovascular (42%), and gastrointestinal (33%) systems.^[4] Though the cake kidney remains asymptomatic such cases warrant investigation of concomitant congenital anomalies of other organ systems as well as the microarchitecture changes in the renal parenchyma.

Department of Anatomy,
Kasturba Medical College,
Manipal University, Manipal,
India

Submitted:
09.08.2016

Accepted:
02.11.2016

Correspondence:
Prasanna LC
E-mail:
anatomy1cp@yahoo.com

©Copyright 2017 by Turkish
Association of Urology

Available online at
www.turkishjournalofurology.com

Case presentation

During routine anatomical dissection on a 61-year-old male cadaver we found a large, single and irregular renal mass at the level of the sacral promontory. This single mass was situated on the terminal part of abdominal aorta (AA) and the origin of the inferior vena cava (IVC). No gross changes were noticed in the caliber of the said larger vessels both proximal and distal to the renal mass. The departmental records of this individual had not revealed any past as well as current clinical history suggestive of renal disease at the time of death.

The kidney had dimensions of 12.8 x 13.1x 5.3 cm. On inspection the anterior surface of this renal mass showed several lobulations and five hilar regions (Figure 1-3) whereas the posterior surface was smooth (Figure 4). Out of five, four hilar regions were seen on the anterior surface with two regions on either side of the midline and the 5th hilum was seen on the inferior surface (Figure 1a, b). There were no clear morphological features to distinguish the poles as well as the borders.

Hilum 1: It is localized anteriorly on the right side of the fused kidney (Figure 1a, b) and surrounded anteroposteriorly with renal vein, renal pelvis, and renal artery. It receives a renal artery directly from the AA coursing anterior to the IVC without further branching at or near the hilum. Three to four major calyces emerging from the hilum join with each other to form a larger major calyx which could be considered as a renal pelvis.

Two veins emerging from the hilum (Figure 3) joined with each other to form a single left renal vein which drains into the left edge of IVC at the level of L3.

Hilum 2: It is situated anteriorly below the hilum 1 with an artery in front and a renal pelvis behind. Renal artery arises directly from the AA, courses towards the hilum and divides into two branches. Larger branch enters into the hilum 2 and a smaller one into the hilum 1 behind the renal vein. A larger renal pelvis exits from the hilum, joins with the renal pelvis from the hilum 1, continues as the right ureter and enters into the bladder at its normal anatomical location after their normal pelvic course.

Hilum 3: It is situated anteriorly on the left side of the fused kidney with an artery, major calyx and vein from above downwards. Renal artery arises directly from the AA coursing downward to enter the hilum at a higher level. A small vein from the hilum joined with a vein coming from the 4th hilum. Two major calyces soon after their exit joined to form renal pelvis. Two small veins arising behind the calyx joined to form a single vein which later fuses with the vein of the 4th hilum.

Hilum 4: It is situated below the 3rd hilum with an artery, calyx and a vein from above downwards. Renal artery to the 4th hilum sprung from the left side of the AA at the L4 level and after a short course it divides into two branches. One of its branches run downward and left side to reach the 4th hilar regions and the other

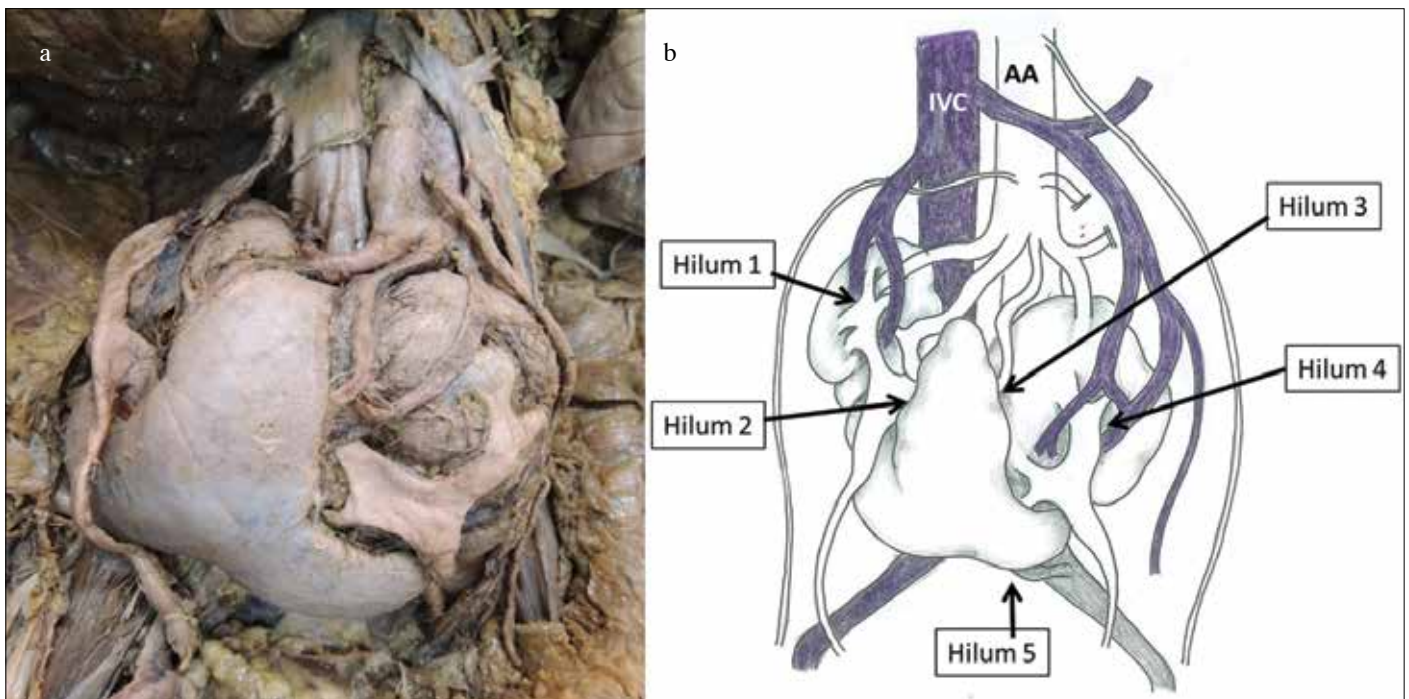


Figure 1. a, b. (a) *In situ* kidney specimen with multiple vascular variations, (b) Schematic diagram of Figure 1a

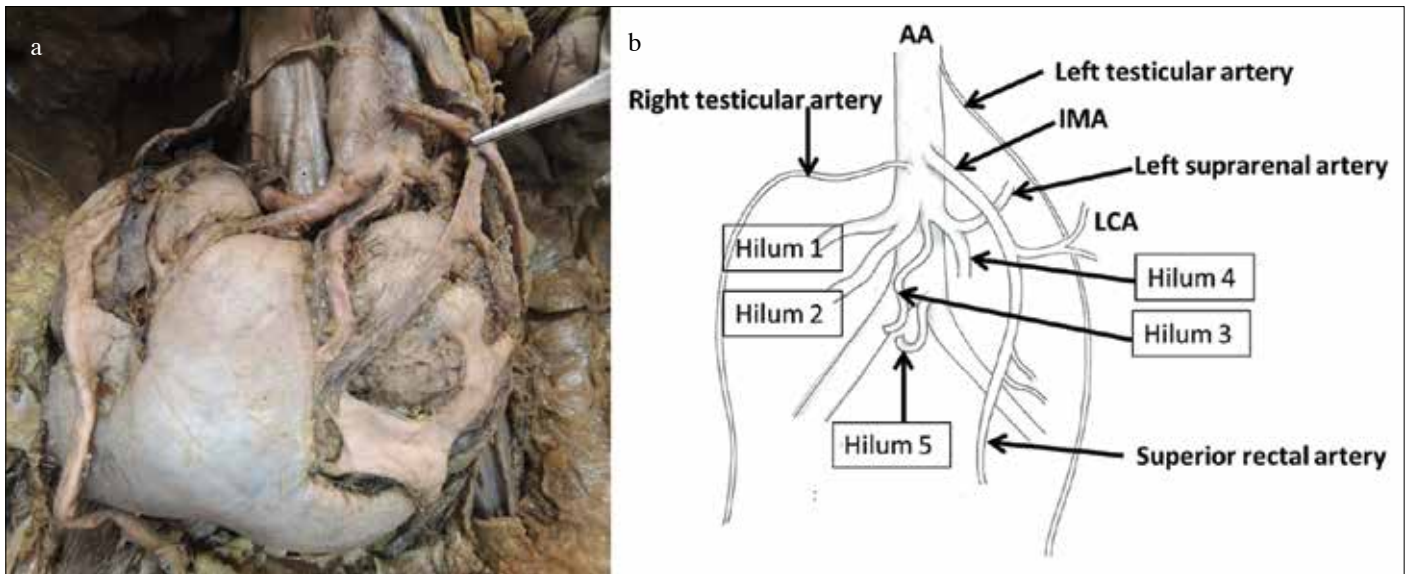


Figure 2. a, b. (a) *In situ* kidney specimen showing left suprarenal artery (below the inferior mesenteric artery held with forceps) arising from the left renal artery going towards the 4th hilum. (b) Schematic diagram showing arterial arborization of the present case

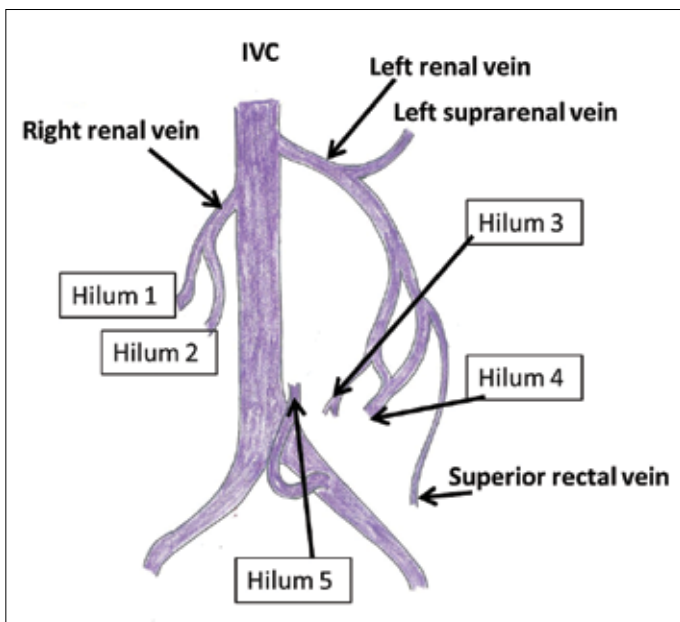


Figure 3. Schematic diagram showing the venous drainage of the fused kidney



Figure 4. *In situ* kidney specimen (lifted with forceps) showing smooth inferior surface with its vasculature

branch continues upwards on the posterior abdominal wall to enter the left suprarenal gland as the inferior suprarenal artery. Three major calyces from the hilum come out to form a large renal pelvis which later joins with the renal pelvis from the 3rd hilum to form a larger single renal pelvis. Left ureter from the renal pelvis followed a normal pelvic course till it entered into the bladder. Veins from the 3rd and 4th hilar regions joined with the superior rectal vein coming from the posterior surface of the rectum to form a wide vessel.

Later it received left suprarenal vein to form a larger left renal vein to drain into the left side of the inferior vena cava.

Hilum 5: It was found on the inferior surface below the aortic bifurcation (Figure 4). It receives a renal artery from the proximal part of the left common iliac artery. A single vein emerges out from the hilum and drains into the left common iliac vein. No minor as well as major calyx from the 5th hilum is noted.

Gross observations may provide clue that each collecting system drains its respective half of the kidney and does not com-

municate with the opposite side. No evidence of hydronephrosis or vascular compression at any point along their course, or close to their sites of entry into the bladder was noted.

Right testicular artery (Figure 1a, b) arised from the right side of the abdominal aorta at 3rd lumbar vertebral level close to the origin of inferior mesenteric artery. It passed behind the right renal vein to enter the right spermatic cord. The left testicular artery stemming from the front of abdominal aorta at 2nd lumbar vertebral level followed the normal course till its entry into left spermatic cord.

Discussion

Congenital renal fusion anomalies are being recognized by clinicians with newer imaging modalities and by anatomists during routine post-mortem dissection. This could be due to the rarity of the condition or the scarce number of the individuals present with renal complications or may die due to complications from the associated congenital anomalies. Pannorlus first described the rarest variety of complete fusion of two kidneys into a single entity referred to as the cake or kuchenniere's kidney.^[5] When the kidney fails to ascend and remain in the pelvis, the ureters would not normally cross the midline. Because of failure of renal ascent the kidney retains its primitive vascular supply leading to formation of major renal vascular anomalies.^[1]

Development of the kidney begins as a result of inductive interaction between the metanephric blastema and ureteric bud at 4th week of gestation. During 6th to 9th weeks of gestation the fetal kidney undergoes a complex process like ascent, lateral migration, 90° rotation around their longitudinal axis before they occupy their final lumbar position. The ascending kidney receives newer arteries cranially followed by the degeneration of the caudal ones. Therefore, renal anomalies can occur due to abnormalities in the renal development, ascent, rotation and vasculature.^[6] Two theories have been put forward to explain the mechanism of the present case. The mechanical theory proposed that the cranial migration of the metanephric (nephrogenic) blastema and ascent of ureteric buds may be facilitated by the normal relations of the umbilical arteries with the surrounding structures as they provide enough space for a normal ascent of the nephrogenic blastemas.

Nephrogenic blastemas were squeezed by the malpositioned umbilical arteries prior to the renal ascent in 6th and 9th gestational week (i.e., at 10 mm stage of embryo) so that the two blastemas fuse together as a single mass. The genetic theory stated that the positioning of the kidney along the mediolateral axis has been signaled by the sonic hedgehog gene.^[1-3] Any disruptions in their positioning will result in complete renal fusion. The development of separate renal pelvis (i.e., duplex collecting

system) in our case could be due to the premature division of the distal part of the ureteric bud resulting in two separate collecting systems. As a matter of fact this fusion anomaly may show gross histological abnormalities like immature glomeruli, hemorrhagic/cystic changes, grossly dilated tubules and evidence of infarction secondary to the abnormal blood supply. However, in our case histological structure of the renal parenchyma showed no changes.^[1]

During the renal ascent, the kidney is perfused with the branches of median sacral, internal iliac, common iliac as well as the caudal part of abdominal aorta. As the cranial arteries sprouting the caudal ones gradually disappear, the latter ones settle in their permanent location in the lumbar region. Fused kidney has numerous nutrient arteries, so it is difficult to predict the main and accessory renal arteries. In our case, four renal arteries originated from the abdominal aorta close to its bifurcation and one from the left common iliac artery. Four of these arteries approached the kidney through the four renal hila situated on the anterior surface of the fused kidney and the fifth one entered into the kidney through its inferior surface. In our case the presence of multiple renal arteries coming from the caudal part of aorta and its bifurcation indicates the primitive pattern of renal vasculature. This could be due to failure of renal ascent from the pelvis.^[7,8]

Venous vascularization of pelvic kidneys is not known clearly. Similar to the renal artery the pelvic renal veins may be multiple, slightly larger and drain either into the IVC or into the ipsilateral common iliac vein.^[2] In our case the formation of the left renal vein was significant in that it was composed of smaller renal veins coming from the left side of the fused kidney. In addition they received the superior rectal and left suprarenal vein before they formed the main left renal vein. Overall, this anomalous blood supply may be a contributing factor for the renal vascular compromise associated with pressure on surrounding structures, pelvic trauma, atherosclerosis and aneurysm formation. Fused kidney poses much problem in the treatment of distal aortic aneurysm and ilioaortic aneurysms. Mobilization of the fused kidney by dissecting the parenchyma may cause postoperative renal vascular injury, damage to the collecting systems and even the renal failure.

Typically, the cake kidney coexists with other malformations, such as abnormal testicular descent, tetralogy of Fallot, vaginal atresia, sacral agenesis, caudal regression syndrome, bifid spine and anal abnormalities. No such anomalies were noted in our case.^[9] Generally pelvic kidney may remain asymptomatic during the lifetime of the patient, but few may complain of local pain from dragging on the renal vessels by the weight of an organ or pain in the lower limb due to compromised blood supply to the lower limb caused by the fused renal mass resting on the

aortic bifurcation and iliac vein formation. Incidental finding of this anomaly may warn us to look out for other associated congenital abnormalities but interestingly such cases warrant constant evaluation of the renal function to reduce the associated morbidity.

In conclusion, diagnosis of the fused renal mass (cake kidney) requires continuous evaluation of the renal function, early detection of renal and its vascular complications, and exclusion of concomitant congenital anomalies of the other organ systems. Knowledge of possibilities of such congenital anomalies may avoid confusion/misdiagnosis during various image analyses and may also help in explaining the unexpected symptoms or complications.

Informed Consent: Written informed consent was obtained from the relatives of this deceased patient that was presented in this case report.

Peer-review: Externally peer-reviewed.

Author Contributions: Concept – L.C.P., A.V., H.R.T.; Design – L.C.P., H.R.T.; Supervision – H.R.T., A.S.D.; Data Collection and/or Processing – L.C.P., H.R.T.; Analysis and/or Interpretation – L.C.P., H.R.T.; Literature Search – H.R.T.; Writing Manuscript – L.C.P.; Critical Review – A.S.D.

Conflict of Interest: No conflict of interest was declared by the authors.

Financial Disclosure: The authors declared that this study has received no financial support.

Hasta Onamı: Yazılı hasta onamı bu olguya katılan hastanın yakınlarından alınmıştır.

Hakem Değerlendirmesi: Dış bağımsız.

Yazar Katkıları: Fikir – L.C.P., A.V., H.R.T.; Tasarım – L.C.P., H.R.T.; Denetleme – H.R.T., A.S.D.; Veri Toplanması ve/veya İşlemesi – L.C.P., H.R.T.; Analiz ve/veya Yorum – L.C.P., H.R.T.; Literatür Taraması – H.R.T.; Yazıyı Yazan – L.C.P.; Eleştirel İnceleme – A.S.D.

Çıkar Çatışması: Yazarlar çıkar çatışması bildirmemişlerdir.

Finansal Destek: Yazarlar bu çalışma için finansal destek almadıklarını beyan etmişlerdir.

References

1. Miclaus GD, Pupca G, Gabriel A, Matsusz P, Loukas M. Right lump kidney with varied vasculature and urinary system revealed by multidetector computed tomographic (MDCT) angiography. *Surg Radiol Anat* 2015;37:859-65. [\[CrossRef\]](#)
2. Kaufman MH, Findlater GS. An unusual case of complete renal fusion giving rise to a cake or lump kidney. *J Anat* 2001;198:501-4. [\[CrossRef\]](#)
3. Babu CSR, Sharma V, Gupta OP. Renal fusion anomalies: A review of surgical anatomy. *Anat Physiol* 2015;S5:1. [\[CrossRef\]](#)
4. Tiwari AK, Chaudhary AK, Khowal H, Chaudhary P, Arora MP. Pancake kidney: A rare developmental anomaly. *Can Urol Assoc J* 2014;8:E451-2. [\[CrossRef\]](#)
5. Glenn JF. Fused pelvic kidney. *J Urol*. 1958;80:7-9. [\[CrossRef\]](#)
6. Sadler TW. Langman's medical embryology. 2015, 13th edn, pp. 250-261. Wolters Kluwer Health: china. ISBN: 978-1-4511-9164-6.
7. Prasanna LC, Babu A, D'Souza AS, Bhat KMR. A rare case of bilateral high origin of the testicular artery with variation in the course and branches. *J Surg Acad* 2014;4:45-8.
8. Venkataramulu M, Vinaykumar N, Prasanna LC. Renal vascular morphology and their significance in predicting accessories. *Int J Res Med Sci* 2014;2:506-9. [\[CrossRef\]](#)
9. Rosenkrantz AB, Kopec M, Laks S. Pelvic cake kidney drained by a single ureter associated with unicornuate uterus. *Urology* 2010;76:53-4. [\[CrossRef\]](#)