



## Intratesticular calcified nodule

### *Intratestiküler kalsifiye nodül*

Fatih Akdemir<sup>1</sup>, Mustafa Aldemir<sup>2</sup>, Huban Sibel Orhun<sup>3</sup>

**Cite this article as:** Akdemir F, Aldemir M, Orhun HS. Intratesticular calcified nodule. Turk J Urol 2017; 43(4): 563-5.

#### ABSTRACT

Since calcified nodule of the testis is seen very rarely, its etiology and diagnostic approach are not fully known. There have been a few cases reported in the literature. The objective of this study was to review the literature and report the case of a 30-year-old patient, who applied to our clinic due to a suspicious stiffness in his testis and underwent partial orchiectomy.

**Keywords:** Calcified nodule; partial orchiectomy; testis.

#### ÖZ

Testisin kalsifiye nodülü çok nadir görülmesi dolayısıyla etiolojisi ve tanısal yaklaşımı tam olarak bilinmeyen bir durumdur. Literatürde bu konuda birkaç vaka bildirilmiştir. Kliniğimize testisinde şüpheli bir sertlik sebebiyle gelen ve parsiyel orşiektomi yapılan 30 yaşındaki hasta literatür bilgileri de gözden geçirilerek tartışıldı.

**Anahtar Kelimeler:** Kalsifiye nodül; parsiyel orşiektomi; testis

#### Introduction

Along with their rarity, testis malignancies constitute the most commonly seen solid urologic malignancies in men between the ages of 24 and 30, and 1-2% of all male cancers. They are frequently seen between the ages of 30 and 34; however, they reach to peak under the age of 5 and after the age of 60.<sup>[1]</sup> Intratesticular calcifications show 3 patterns on ultrasound examination namely microlithiasis, nonmicrolithiasis calcification (macrocalcification), and tumor-associated calcifications. Testicular microcalcifications are less than 1 mm, and macrocalcifications bigger than 1 mm.<sup>[2]</sup> Dystrophic calcified nodule of the testis is a rarely encountered lesion whose etiology is unknown and diagnostic evaluation is controversial.

#### Case presentation

A 30-year-old male patient presented to our clinic with a suspicious solid mass in his left

testis, which he newly noticed. There wasn't anything remarkable in his medical history. During his physical examination, a solid palpable mass in the size of a chick-pea near the upper pole of the left testis was noted. The contralateral testis was normal in appearance. A 16 x 12 mm mass with rim was detected during the color- Doppler scrotal ultrasonography of the patient which also revealed calcification and lobulated contour. However, the mass could not be distinguished as being benign or malignant. Alpha-fetoprotein (AFP), beta subunit of human chorionic gonadotropin (beta-HCG) and lactate dehydrogenase (LDH) levels of the patient were within normal limits. As a result of the pelvic magnetic resonance imaging performed with the thought of receiving further information regarding the status of the patient, it was reported that a mass was observed within the parenchyma of the left testis, and calcification of the tunica albuginea was present, while contrast involvement was not evident (Figure 1). Thereupon, realization of left partial, or if necessary, radical orchi-

<sup>1</sup>Clinic of Urology, Samsun Terme State Hospital, Samsun, Turkey

<sup>2</sup>Clinic of Urology, Ankara Atatürk Training and Research Hospital, Ankara, Turkey

<sup>3</sup>Clinic of Pathology, Ankara Atatürk Training and Research Hospital, Ankara, Turkey

**Submitted:**  
17.10.2016

**Accepted:**  
28.11.2016

**Correspondence:**  
Fatih Akdemir  
E-mail:  
nfatihakdemir@hotmail.com

©Copyright 2017 by Turkish Association of Urology

Available online at  
www.turkishjournalofurology.com

ectomy was decided upon. Owing to the fact that the patient was single and there was a risk of gonad loss, a preoperative semen analysis was conducted which was determined to be normal. After completing preoperative preparations and obtaining informed consent of the patient, the patient was taken to surgery and the spermatic cord was found through a left inguinal incision and clamped with a tourniquet. The testis was freed from the scrotum and delivered out through the inguinal incision. After the tunica vaginalis was opened, the tunica albuginea was incised to reach the palpable nodule. The nodule within the testicular tissue, which was approximately a chick-pea in size, yellow in color and sharply-circumscribed, was extracted as a whole (Figure 2). Intraoperatively frozen section procedure was performed, and the specimen was examined histopathologically in order to decide on whether to carry out a radical orchiectomy or not, and after the lesion was reported as a calcified nodule, partial orchiectomy was found sufficient and the operation was ended by closing the layers properly. Later, the final histopathologic examination of the whole specimen was found to be consistent with that of the frozen section procedure, and the lesion was reported as degenerated calcified nodule (Figure 3). Due to the fact that it is a rare occurrence, there is no data regarding the follow-up of these patients in the literature. Therefore, during the 11-month follow-up, the physical examination, abdominal ultrasonographic findings, and hormonal profile of the patient were assessed to be within normal limits.

## Discussion

Testicular cancer is a rare disease accounting for 1-2% of male neoplasms and the most commonly malignancies were found in 20 to 34-year-old man. Usually they begin as a palpable, solid

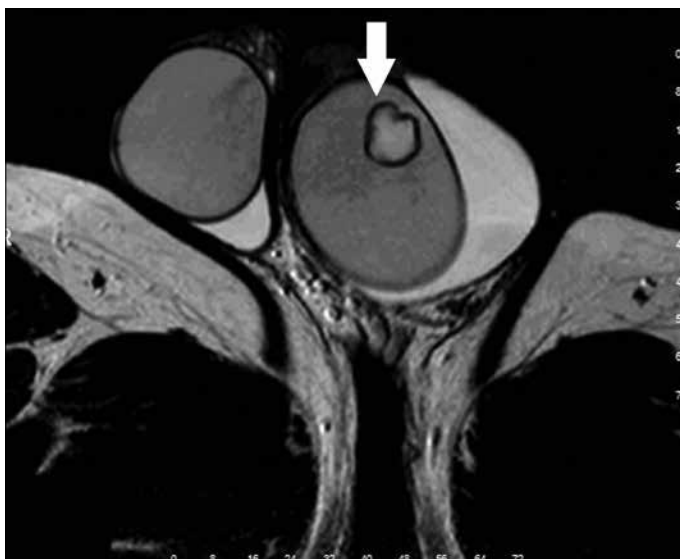

Figure 1. Intratesticular mass seen in the MRI (arrow)

mass. There is a clear increase in the incidence of testicular cancers worldwide particularly within the last 20 years. Such an increase leads urologists and andrologists to pay more attention to testicular nodules and to testicular symptoms such as a testicular mass, pain, swelling, hardness, epididymitis or orchitis.<sup>[3]</sup>

Dystrophic degenerated calcified nodule of the testis is a very rare occasion, and there have been a few cases reported in the literature that carry the same characteristics. The etiology of intratesticular calcified nodule is unclear, and it was first reported by

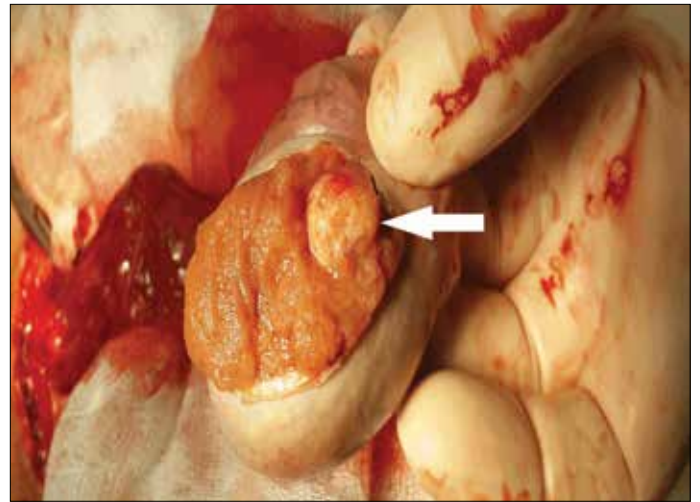


Figure 2. Intraoperative image of the intratesticular nodule (arrow)

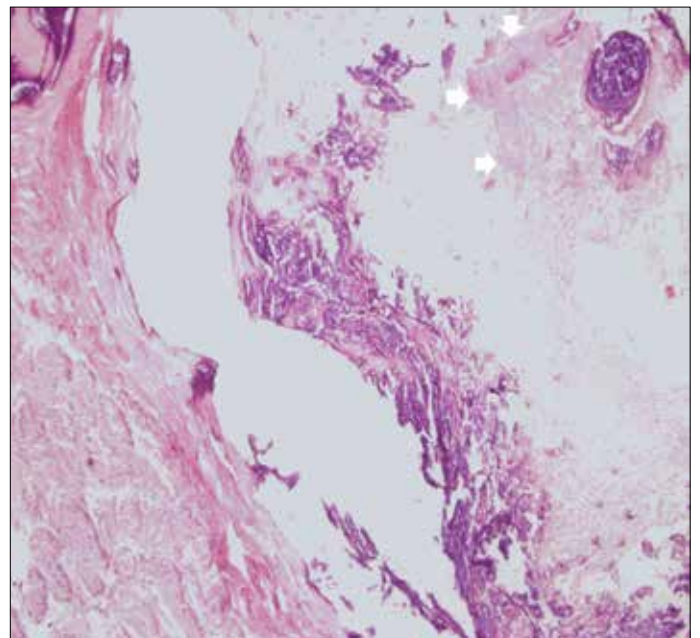


Figure 3. HEX40: the calcified region with seminiferous tubules in the testis (arrows)

Minkowitz et al.<sup>[4]</sup> in 1965. After the first report, various authors have reported cases with the same characteristics.<sup>[5-8]</sup> Numerous soft tissues have osteogenic potential, and the renal pelvis, artery wall, eyes, muscles and tendons have been classified as the regions where ectopic ossification is seen.<sup>[5]</sup> Scrotal calcifications are classified as intratesticular and extratesticular. Intratesticular calcifications show three patterns on ultrasound examination: microlithiasis, nonmicrolithiasis (macrocalcification), and tumor-associated calcifications. The etiology of the testicular microlithiasis is not clearly known. The presence of microlithiasis in the testis has been known for a long time, and reported both in children and adults with its association with tumoral and nontumoral pathologies. Macrocalcification is defined as any focus of “coarse” calcification larger than 1 mm separate from any intratesticular mass, if present. Extratesticular calcifications can be localized in the epididymis, testicular or epididymal appendices, wall of tunica vaginalis, or within the intravaginal space.<sup>[2]</sup>

Intratesticular calcifications are generally associated with phlebolith or spermatic granuloma, and regions of vascular calcification are seen as clusters. Teratocarcinoma, metastatic carcinoid tumor or embryonal cell carcinoma can be seen as calcifications associated with hypoechoic regions.<sup>[9]</sup> Regions having a calcified scar image and acoustic shadowing are classified as “burned-out tumors” and accepted as the histologic proof of regressed testicular cancer. Hemosiderin accumulation is seen in the testicular regression syndrome along with dystrophic calcification. Intratesticular calcifications, large cell calcified Sertoli cell tumor, simple testicular cysts, infective conditions like tuberculosis or filariasis can be seen in the regions of trauma, peripheral infarction, and necrosis.<sup>[3]</sup>

If the contralateral testis is normal in testis tumors, the standard approach is radical inguinal orchiectomy. In cases with bilateral solitary testicular tumors or atrophic contralateral testis, organ-preserving surgery can be performed. In many young patients with a normal testosterone level, fertility and life expectancy, the same procedure can be implemented without causing relapse or progression in order to prevent the physiologic and psychological effects of castration, and hence, unnecessary gonad loss will be prevented in cases with benign testicular lesions.<sup>[10]</sup>

Intratesticular calcified nodules can present with benign pathologies, and the urologist, radiologist, and pathologist must act together while assessing these. Since the calcified nodule of the testis is a rare occasion, differential diagnosis of testicular masses should be also kept in mind. If malignancy is suspected, biopsy will be useful in the surgical approach.

**Informed Consent:** Written informed consent was obtained from patient who participated in this case.

**Peer-review:** Externally peer-reviewed.

**Author Contributions:** Concept – F.A.; Design – F.A.; Supervision – F.A., M.A.; Resources – F.A., H.S.O.; Materials – F.A., H.S.O.; Data Collection and/or Processing – F.A.; Analysis and/or Interpretation – F.A.; Literature Search – F.A.; Writing Manuscript – F.A.; Critical Review – F.A., M.A., H.S.O.; Other – F.A.

**Conflict of Interest:** No conflict of interest was declared by the authors.

**Financial Disclosure:** The authors declared that this study has received no financial support.

**Hasta Onamı:** Yazılı hasta onamı hastadan alınmıştır.

**Hakem Değerlendirmesi:** Dış bağımsız.

**Yazar Katkıları:** Fikir – F.A.; Tasarım – F.A.; Denetleme – F.A., M.A.; Kaynaklar – F.A., H.S.O.; Malzemeler – F.A., H.S.O.; Veri Toplanması ve/veya İşlemesi – F.A.; Analiz ve/veya Yorum – F.A.; Literatür Taraması – F.A.; Yazıyı Yazan – F.A.; Eleştirel İnceleme – F.A., M.A., H.S.O.; Diğer – F.A.

**Çıkar Çatışması:** Yazarlar çıkar çatışması bildirmemişlerdir.

**Finansal Destek:** Yazarlar bu çalışma için finansal destek almadıklarını beyan etmişlerdir.

## References

1. Jemal A, Siegel R, Ward E, Xu J, Ward E: Cancer statistics. *CA Cancer J Clin* 2010;60:277-300. [\[CrossRef\]](#)
2. Nistal M, Paniagua R, González-Peramato P, Reyes-Múgica M. Perspectives in Pediatric Pathology, Chapter 13. Calcifications in the Testis and Paratesticular Structures. *Pediatr Dev Pathol* 2016;19:173-82. [\[CrossRef\]](#)
3. Viola P, Claudi R, Pompa P, Lattanzio G, Zappacosta R. A diagnostic dilemma: dystrophic calcified nodule of the testicle in a patient with no other symptoms - case report and review of the literature. *Urol Int* 2012;88:232-4. [\[CrossRef\]](#)
4. Minkowitz S, Soloway H, Soscia J. Ossifying interstitial cell tumor of the testes. *J Urol* 1965;94:592-5. [\[CrossRef\]](#)
5. Yoneda F, Kagawa S, Kurokawa K. Dystrophic calcifying nodule with osteoid metaplasia of the testis *Br J Urol* 1979;51:413. [\[CrossRef\]](#)
6. Mesia L, Georgsson S, Zuretti A. Ossified intratesticular mucinous tumor. *Arch Pathol Lab Med* 1999;123:244-6.
7. Goel RK, Norman RW, Gupta R. Dystrophic calcified nodule of the testicle: a case report. *Can Urol Assoc J* 2007;1:402-3. [\[CrossRef\]](#)
8. Law H, Mushtaq I, Wingrowe K, Malone M, Sebire NJ. Histopathological features of testicular regression syndrome: relation to patient age and implications for management. *Fetal Pediatric Pathol* 2006;25:119-29. [\[CrossRef\]](#)
9. Dagash H, Mackinnon EA. Testicular microlithiasis: what does it mean clinically? *BJU Int* 2007;99:157-60. [\[CrossRef\]](#)
10. Heidenreich A, Weissbach L, Höltl W, Albers P, Kliesch S, Köhrmann KU. German Testicular Cancer Study Group. Organ sparing surgery for malignant germ cell tumor of the testis. *J Urol* 2001;166:2161-5. [\[CrossRef\]](#)