



# Glans wings are separated ventrally by the septum glandis and frenulum penis: MRI documentation and surgical implications

## *Penis glansı ventralde septum glandis ve frenulum ile ayrılmıştır: MR bulguları ve cerrahiye katkısı*

Hüseyin Özbey<sup>1</sup>, Ali Kumbasar<sup>2</sup>

**Cite this article as:** Özbey H, Kumbasar A. Glans wings are separated ventrally by the septum glandis and frenulum penis: MRI documentation and surgical implications. Turk J Urol 2017; 43(4): 525-9

### ABSTRACT

**Objective:** In the normal human penis, the glans wings are in apposition in the midline ventrally, and are separated by the “septum glandis” and “frenulum” of the prepuce. However, most of the hypospadias repair techniques include dissection of the glans wings and their approximation enclosing the neourethra within the glans.

**Material and methods:** In order to obtain detailed information about the normal anatomy of glans penis, magnetic resonance imaging (MRI) findings of the penis were studied in three adults. Transverse, and sagittal sections of the penis were performed with a 1.5-T MRI scanner.

**Results:** The present MRI study has confirmed that the glans wings do not fuse at the ventral midline and they are separated by a fibrous tissue (septum glandis). This fibrous tissue is connected to the frenulum, traversing the wings of the glans penis. The glanular urethra forming the fossa navicularis has a wider caliber than the proximal urethra, and its walls are radiologically seen as the extension of that fibrous tissue.

**Conclusion:** The male urethra is not a uniform tubular structure and has distinct attachments in glans penis. The glans wings are separated ventrally by the septum glandis and frenulum. In hypospadias, the septum glandis and frenulum are entirely missing structures. Therefore, in hypospadias surgery, the anatomical features of the glanular urethra must be taken into consideration.

**Keywords:** Frenulum; hypospadias; glans penis; penis; septum glandis.

### ÖZ

**Amaç:** Normal insan penisinde glans kanatları ventral yüzde "septum glandis" ve prepusyuma ait "frenulum" ile birbirinden ayrıdır. Oysa, hipospadiyas cerrahisinde uygulanan tekniklerin çoğunluğu glans kanatlarının diseksiyonunu ve neöütretrayı içine alacak şekilde karşılıklı olarak birleştirilmesini içermektedir.

**Gereç ve yöntemler:** İnsan penis glansı anatomisi hakkında detaylı bilgiler edinmek amacıyla üç erişkinde penis anatomisi MR bulguları ile değerlendirilmiştir. Penisin yatay ve dikey kesitleri 1,5-T MR tarayıcı ile gerçekleştirilmiştir.

**Bulgular:** Bu çalışma ile glans kanatlarının ventralde birleşmediği ve bir fibröz doku ile birbirinden ayrıldığı gösterilmiştir. Bu fibröz doku glans kanatlarını geçerek, frenulum ile birleşmektedir. Fossa navicularisi oluşturan glanular üretranın proksimal üretradan daha geniş olduğu ve duvarlarının bu fibröz dokunun uzantıları ile oluştuğu, radyolojik olarak görülmüştür.

**Sonuç:** Erkek üretrası uniform bir tüp yapısında değildir ve penis glansı içinde özel bağlantıları mevcuttur. Glans kanatları ventralde septum glandis ve frenulum ile ayrılmıştır. Hipospadiyas olgularında septum glandis ve frenulum yoktur. Bu sebeple, glanular üretranın özellikleri hipospadiyas cerrahisinde dikkate alınmalıdır.

**Anahtar Kelimeler:** Frenulum; hipospadiyas; glans penis; penis; septum glandis.

### Introduction

In hypospadias surgery, a clear understanding of the normal anatomy of the penis and origin

of the penile urethra is essential, together with a grasp of precise microscopic anatomy of the penile hypospadias. In the normal human penis, the glans wings are in apposition in the

<sup>1</sup>Department of Pediatric Surgery and Division of Pediatric Urology, İstanbul University İstanbul School of Medicine, İstanbul, Turkey

<sup>2</sup>Emar-med Radiology Center, İstanbul, Turkey

**Submitted:**  
31.07.2017

**Accepted:**  
23.08.2017

**Correspondence:**  
Hüseyin Özbey  
E-mail:  
huseyinbey@hotmail.com

©Copyright 2017 by Turkish Association of Urology

Available online at  
www.turkishjournalofurology.com

midline ventrally, and are separated by the “septum glandis” in conjunction with the “frenulum”. The frenulum is also included in the formation of the distal (glanular and subcoronal) urethra, which has a special part known as the “fossa navicularis”.<sup>[1-4]</sup> Almost all hypospadias repair techniques include glans dissection and their approximation over the neo-urethra. However, the male urethra is not a tubular structure with uniform configuration and diameter, and has distinct attachments in glans penis.<sup>[1-4]</sup>

In order to obtain detailed information about the anatomy of glans penis, magnetic resonance imaging (MRI) findings of adult penis were studied, with particular reference to the glanular urethra, septum glandis and frenulum. To the best of our knowledge, this is the first study to examine MR images of this particular part of the penis.

## Material and methods

Magnetic resonance imaging of the glans penis in three adult men (aged 23, 23, and 24 years) were performed using a 1.5-T 8-channel MRI scanner (Siemens Magnetom Essenza, Siemens

Healthcare, Erlangen, Germany). The patients were members of a football team, who were to undergo MRI studies for soft tissue injuries. All individuals were otherwise normal on physical examination, but circumcised. The men consented to penile MRI after being informed of the purpose and procedure of the study. MRI of the glans penis was performed with a fixed position, lying the penis backwards onto the pubis.

Cross-sections of the glans penis were performed at six levels; submeatal, distal glanular, mid-glanular, proximal glanular, coronal and subcoronal levels. Four main structures: the glans penis, septum glandis, frenulum, and the corpus spongiosum were visualized with particular reference to the glanular urethra.

## Results

It was observed that the penile urethra was located within the corpus spongiosum terminating at the mid-glanular level of the glans penis. The walls of the glanular urethra were seen radiologically as an extension of the fibrous tissue (septum glandis) connected to the frenulum, traversing the wings of the glans

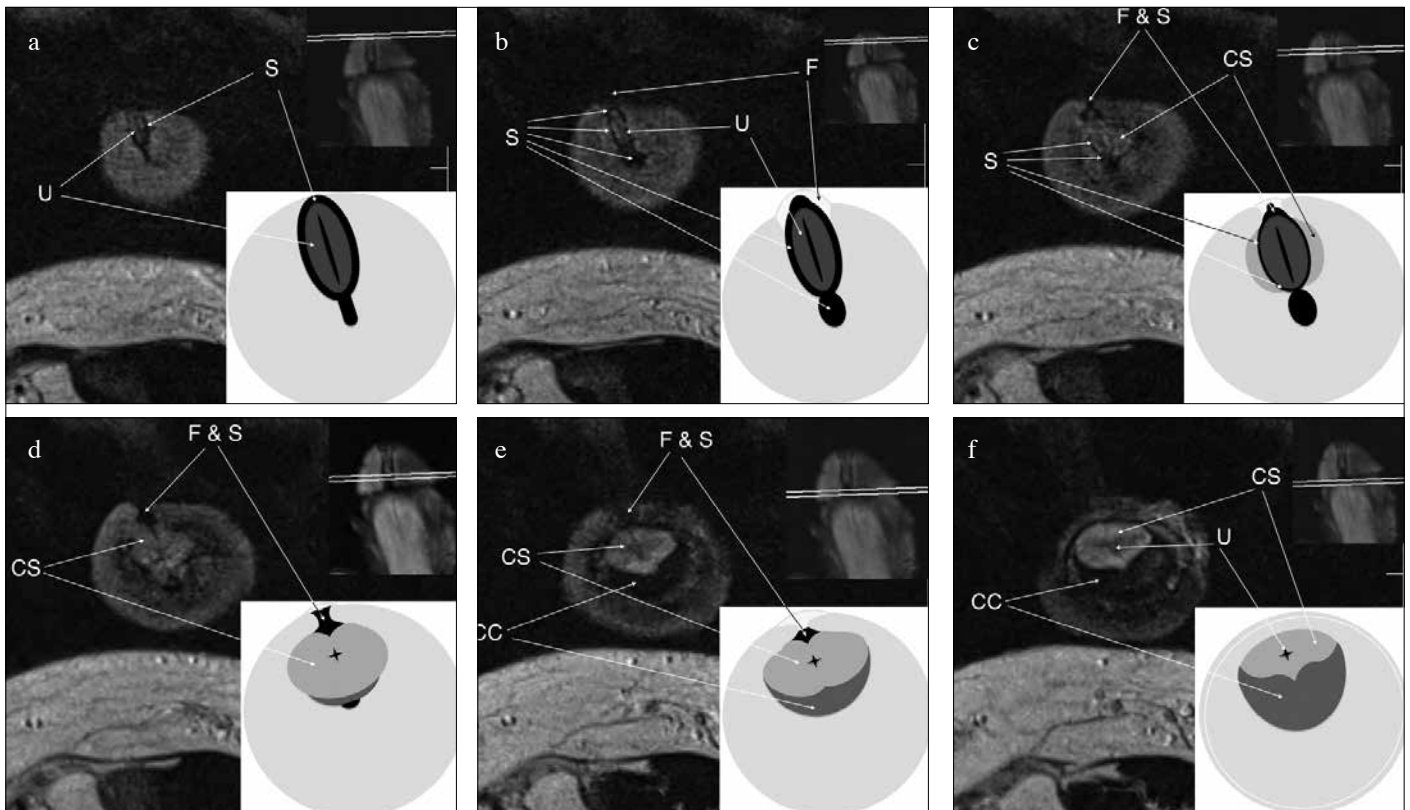


Figure 1. a-f. Cross sectional MRI anatomy of the glans penis in a 24 year old man, showing the fibrous tissue (septum glandis) between the glans wings (S). Note the walls of the glanular urethra as extension of the fibrous tissue connected to the frenulum (F), traversing the wings of the glans penis.

a: submeatal level; b: distal glanular level; c: mid-glanular level; d: proximal glanular level; e: coronal level; f: subcoronal level. U: urethra; CS: corpus spongiosum; CC: corpus cavernosum.

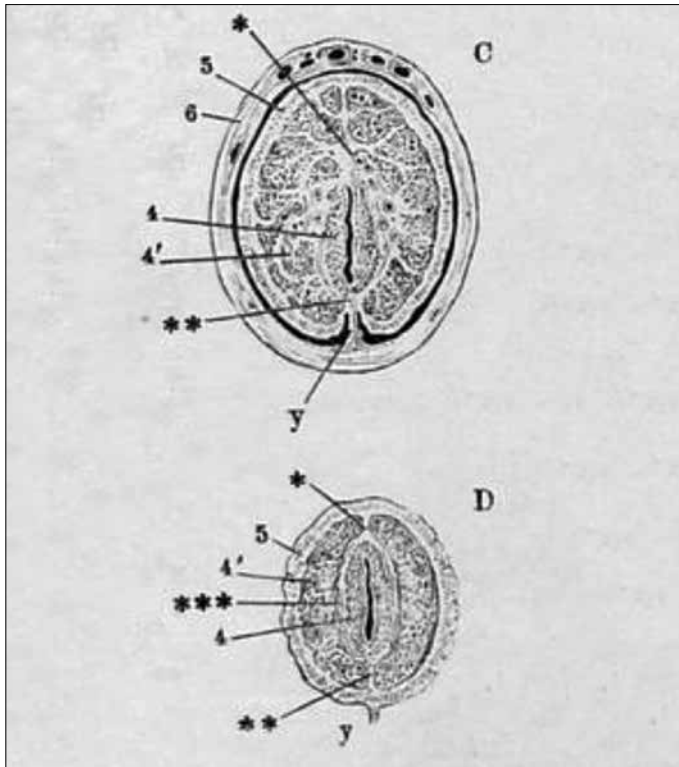


Figure 2. Cross sections of the glans penis showing the septum and frenulum in “Anatomischer Hand-Atlas zum Gebrauch im Secirsaal (Band 6) Eingeweide – Braunschweig, 1877”. [4] C) mid-glanular level, D) submeatal level. Upper median septum (\*), lower median septum (\*\*), fibrous tissue surrounding the glanular urethra and connecting the upper and lower median septum (\*\*\*), frenulum (y)

penis. Hence, the glans wings do not fuse at the ventral midline (Figure 1a-f). The area between the wings of the glans was composed of these extensions, forming a frenular delta at the subglanular level (Figure 1e, f). The glanular urethra had a wider caliber than the proximal urethra, resembling a laterally compressed, slit-like passage (“fossa navicularis”) (Figure 1a-f).

## Discussion

In the normal human penis, glans wings merge in the ventral midline, but they are also separated by the frenulum and do not attach to each other in the deeper layers. The septum of the glans penis (septum glandis) is a median partition within the glans, which extends to the tunica albuginea and it is attached to the frenulum, the urethra and the ventral aspect of the urethral meatus. These anatomical features of the glans penis were well described previously (Figure 2).<sup>[1-4]</sup>

In hypospadias, the frenulum is an entirely missing structure in addition to a defective urethra and corpus spongiosum. Glans

wings are spread widely away and the glanular urethra is laid open. The foreskin is not fused ventrally, and it appears as a hood over the glans penis. Recent studies have shown that masculinization of the urethral plate occurs in association with the growth and fusion of the preputial fold along the ventral midline of the genital tubercle, which also forms the frenulum of the proximal part of the glanular urethra. It has been proposed that preputial folds accompany the urethral folds during the formation of the glanular urethra and the preputial frenulum.<sup>[5,6]</sup> A reconstruction of the pathogenesis of hypospadias and associated anomalies has been recently described with histopathologic findings.<sup>[7]</sup> In this novel study, the description of the distalward growth process of median fascial tissues that form the ventral prepuce and frenulum is a new concept, which may change current concepts in hypospadias repair.

Owing to the differences in signal intensity of the corpora cavernosa, corpus spongiosum, fibrous layers, arteries and veins, subcutaneous connective tissue, tunica dartos, epidermis and the urethra the anatomy of the penis becomes visible in MR imaging.<sup>[8]</sup> A recent MRI study of the tissue planes and vessels in hypospadias penis revealed their relationship with each other. A close connection was demonstrated between the dartos and bifurcated spongiosum of the laid open urethra, which are continuous with glans tissue and the adjacent preputium.<sup>[9]</sup> In our study, we showed that the frenulum was connected to the septum between the glans wings as an epidermally lined fibrous tissue. We found that the walls of the glanular urethra are radiologically seen as an extension of that fibrous tissue forming the septum glandis. Additionally, the glanular urethra is seen wider than the proximal urethral caliber. We may say that the frenulum is included in the formation of the distal (glanular and subcoronal) urethra as proposed by van der Putte. Hence, anatomic correction of hypospadias should include tubularization of the urethral plate, reunion of the diverted corpus spongiosum, and construction of the septum, frenulum and foreskin to form the glanular, and subcoronal urethra.

The findings in embryologic and radiologic studies inspired the author (HÖ), and invented a hypospadias repair technique (ie. the Glanular-Frenular Collar (GFC) technique) that simulates the development of the glanular and subcoronal urethra.<sup>[10]</sup> In the GFC technique, the split glans wings are supported by a neo-septum and a neo-frenulum ventrally, which allows tension-free tubularization afforded by the limited spongioplasty (Figure 3). A normal wave-like flow pattern of micturition in 86% of the patients was observed as suggested by Wheeler et al.<sup>[11]</sup> Most of the techniques for hypospadias repair include glansplasty with glanular surface enhancement and dissection of the glans wings. Furthermore, “extensive” dissection of the glans wings and their approximation was recently advised. It was concluded that, enclosing the neourethra within the glans provides a normally reconstructed penis.<sup>[12]</sup>

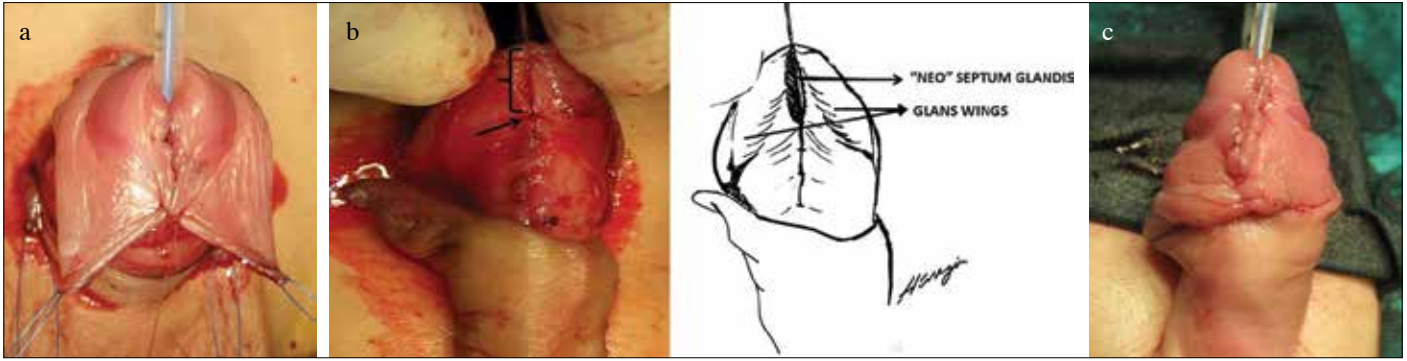


Figure 3. a-c. Hypospadias repair with the glanular-frenular collar (GFC) technique<sup>[10]</sup>:

(a) Subepithelial approximation of the glans wings and a holding suture at mid-frenular level of the ventral mucosal collar. (b) Holding the suture superiorly exposes a cleft-like area between the glans wings (curly bracket) and the last stitch of the partial spongioplasty extending up to the subcoronal level (arrow), filling the cleft-like area between the glans wings (septum glandis) with the terminal ends of the spongiosum and dartos of the mucosal collar. (c) Midline skin closure of the ventral collar providing a neo-fenulum reinforced with spongiosum and dartos: the glanular-frenular collar (GFC)

However, our contention is that, extensive dissection of the glans wings and their approximation over the neo-urethra is not anatomical and may be counter-productive. According to our MRI findings of the glans penis and to our experience with the GFC technique, the glans wings should stay separated by a neo-septum and supported by a neo-frenulum ventrally, which allows tension-free tubularization.<sup>[13]</sup> The male (glanular) urethra is not a tubular structure with a uniform configuration and diameter, and its reconstruction over a catheter/stent should allow for its expansion to emulate fossa navicularis. One way to achieve this outcome is to (re)create the frenular triangle or delta between the glans wings with the described GFC technique.

In conclusion, MRI findings of the normal glans penis show that the septum glandis and the frenulum separate the glans wings on the ventrum. They are also included in the formation of the distal (glanular and subcoronal) urethra, which include the fossa navicularis. Our findings prove that the glanular urethra is not a uniform tubular structure, and special attention should be given to form that particular portion of the urethra in hypospadias reconstruction.

**Ethics Committee Approval:** Authors declared that the research was conducted according to the principles of the World Medical Association Declaration of Helsinki "Ethical Principles for Medical Research Involving Human Subjects", (amended in October 2013).

**Informed Consent:** Written informed consent was obtained from patients who participated in this study.

**Peer-review:** Externally peer-reviewed.

**Author Contributions:** Concept – H.Ö.; Design – H.Ö., A.K.; Supervision – H.Ö.; Resources – A.K.; Materials – A.K.; Data Collection and/or Processing – H.Ö., A.K.; Analysis and/or Interpretation – H.Ö.,

A.K.; Literature Search – H.Ö.; Writing Manuscript – H.Ö.; Critical Review – H.Ö.

**Conflict of Interest:** No conflict of interest was declared by the authors.

**Financial Disclosure:** The authors declared that this study has received no financial support.

**Etik Komite Onayı:** Yazarlar çalışmanın World Medical Association Declaration of Helsinki "Ethical Principles for Medical Research Involving Human Subjects", (amended in October 2013) prensiplerine uygun olarak yapıldığını beyan etmişlerdir.

**Hasta Onamı:** Yazılı hasta onamı hastalardan alınmıştır.

**Hakem Değerlendirmesi:** Dış bağımsız.

**Yazar Katkıları:** Fikir – H.Ö.; Tasarım – H.Ö., A.K.; Denetleme – H.Ö.; Kaynaklar – A.K.; Malzemeler – A.K.; Veri Toplanması ve/veya İşlemesi – H.Ö., A.K.; Analiz ve/veya Yorum – H.Ö., A.K.; Literatür Taraması – H.Ö.; Yazıyı Yazan – H.Ö.; Eleştirel İnceleme – H.Ö.

**Çıkar Çatışması:** Yazarlar çıkar çatışması bildirmemişlerdir.

**Finansal Destek:** Yazarlar bu çalışma için finansal destek almadıklarını beyan etmişlerdir.

## References

1. Putz R, Pabst R. Sobotta atlas of human anatomy. 14th edn. Munich: Elsevier, Urban & Fischer. Munich; 2006.p.199
2. Robinson A. Cunningham's Text-book of Anatomy. New York: W.Wood; 1914. Available via BHL Biodiversity Heritage Library. Available from: <http://www.biodiversitylibrary.org/item/95627#page/1334/mode/1up>
3. Hayek Hv. Der Penis. Conrad K, Ferner H, Gisel A, Hayek Hv, Krause W, Wieser S, Zaki C, editors. Anatomie und Embriologie, Berlin-Heidelberg: Springer-Verlag; 1969.p.370-2.

4. Henle J. Anatomischer Hand-Atlas zum Gebrauch im Secirsaal (Band 6). Eingeweide – Braunschweig; 1877 Available via University Library Heidelberg. Available from: <http://digi.ub.uni-heidelberg.de/diglit/henle1877bd6/0093>
5. Kurzrock EA, Baskin LS, Cunha GR. Ontogeny of the male urethra: Theory of endodermal differentiation. *Differentiation* 1999;64:115-22. [\[CrossRef\]](#)
6. Hynes PJ, Fraher JP. The development of the male genitourinary system: II. The origin and formation of the urethral plate. *Br J Plast Surg* 2004;57:112-21. [\[CrossRef\]](#)
7. Van der Putte SCJ. Hypospadias and associated penile anomalies: a histological study and a reconstruction of the pathogenesis. *J Plast Reconstruct Aesthet Surg* 2007;60:48-60. [\[CrossRef\]](#)
8. Pretorius ES, Siegelman ES, Ramchandni P, Banner MP. MR imaging of the penis. *Radiographics* 2001;21:283-98. [\[CrossRef\]](#)
9. Kureel SN, Gupta A, Sunil K, Dheer Y, Kumar M, Tomar VK. Surgical Anatomy of the Penis in Hypospadias: Magnetic Resonance Imaging Study of the Tissue Planes, Vessels, and Collaterals. *Urology* 2015;85:1173-8. [\[CrossRef\]](#)
10. Özbey H, Etker Ş. Hypospadias repair with the glanular-frenular collar (GFC) technique. *J Pediatr Urol* 2017;13:34e1-34e6.
11. Wheeler APS, Morad S, Bucholz N, Knight MM. The shape of the urinary stream—from biophysics to diagnostics. 2012; *PLoS One* 2012;7:e47133. [\[CrossRef\]](#)
12. Snodgrass W, Bush N. TIP hypospadias repair: a pediatric urology indicator operation. *J Pediatr Urol* 2016;12:11-8. [\[CrossRef\]](#)
13. Özbey H. Consequences of extensive glanular dissection. *J Pediatr Urol* 2017;13:227-8.