



## Long-term outcome of laparoscopic vesicouterine fistula repair: Experience from a tertiary referral centre

### *Laparoskopik vezikouterin fistül onarımının uzun dönem sonuçları: Üçüncü basamak bir referans merkezi deneyimi*

Bimalesh Purkait<sup>1</sup>, Seema Mehrotra<sup>2</sup>, Rahul Janak Sinha<sup>1</sup>, Ved Bhaskar<sup>1</sup>, Vishwajeet Singh<sup>1</sup>

**Cite this article as:** Purkait B, Mehrotra S, Sinha RJ, Bhaskar V, Singh V Long-term outcome of laparoscopic vesicouterine fistula repair: Experience from a tertiary referral centre. Turk J Urol 2017; 43(4): 512-6.

#### ABSTRACT

**Objective:** Vesicouterine fistula (VUF) is an uncommon cause of female genito-urinary fistula. Most of these fistulas are due to lower segment uterine cesarean section (LSCS). Traditionally, open surgical repair has been the traditional treatment. However, laparoscopic repair of VUF is a minimally invasive technique and few case reports have been published with short term follow up. In the present study, we are presenting our long- term outcome of laparoscopic repair of VUF.

**Material and methods:** A retrospective analysis of 8 patients with VUF was performed from 2010 to 2015. Approval of Institutional Review Committee was obtained. All had history of LSCS of whom 3 had history of prolonged obstructed labor. Radiological imaging included ultrasound of kidney, ureter and bladder for all patients and hysterosalpingography in 4 patients and contrast enhanced computed tomography scan in 4 patients.

**Results:** Median age of the patient was 25.5 years (range, 22-32), and median follow up was 2.3 years (range, 1 -4). The most common presentation was cyclical menstrual bleeding through urine (menouria) in all, associated amenorrhea in 6 and vaginal leakage of urine in 2 cases. All patients underwent laparoscopic repair with successful outcomes. The mean operating time was 155±14.5 min (range, 135-186 min) with a median blood loss of 100 mL (range, 50-210 mL). Successful pregnancy was completed in 2 patients and other patients were taking contraceptives.

**Conclusion:** Laparoscopic repair of VUF is a safe and effective minimally invasive technique with successful pregnancy in long- term follow up.

**Keywords:** Laparoscopic repair; menouria; pregnancy; vesicouterine fistula.

#### ÖZ

**Amaç:** Vesikouterin fistül (VUF) sık görülmeyen bir kadın genitoüriner fistülüdür. Bu fistüllerin çoğu alt uterus segmentinde yapılan sezaryen ameliyatına bağlıdır. Geleneksel olarak açık cerrahi onarım yapılır. Ancak VUF'un laparoskopik onarımı minimal invaziv bir teknik olup kısa izlem süreli az sayıda bildiri yayınlanmıştır. Burada VUF'un laparoskopik onarımının uzun dönem sonuçlarını sunmaktayız.

**Gereç ve yöntemler:** 2010 ile 2015 yılları arasında VUF belirtileri ile başvuran 8 hastanın sonuçları retrospektif olarak analiz edildi. Lokal etik kurulun onayı alındı. Hastaların hepsinde sezaryen ve üçünde uzamış obstrüktif doğum öyküsü mevcuttu. Her hastada üriner ultrason incelemesi, 4 hastada histerosalpingografi (HSG) ve diğer 4 hastaya kontrastlı bilgisayarlı tomografi taraması yapılmıştır.

**Bulgular:** Yaş ortalaması 25,5 yıl (22-32 yıl) olan hastalar ortalama 2,3 yıl (1-4 yıl) takip edilmiştir. En sık görülen belirti hastaların tümünde görülen idrarla gelen siklik menstrüel kanama (menüri) idi. Altı hastada ayrıca amenore ve 2 olguda vajinadan idrar kaçırma saptandı. Hastaların hepsine başarılı sonuçlarla laparoskopik onarım yapılmıştır. Ortalama ameliyat süresi 155±14,5 dk (135-186 dk), ortalama kan kaybı 100 mL (50-210 mL) idi. İki hastada gebelikleri başarılı doğumla sonlanmış olup diğer hastalar doğum kontrol yöntemleri uygulamıştır.

**Sonuç:** Vezikouterin fistülün laparoskopik onarımı uzun dönemli izlemde başarılı gebelikle sonlanan güvenli ve etkili bir minimal invaziv tekniktir.

**Anahtar Kelimeler:** Laparoskopik onarım; menüri; gebelik; vezikouterin fistül.

<sup>1</sup>Department of Urology, King George Medical University, Lucknow, India

<sup>2</sup>Department of Gynecology and Obstetrics, King George Medical University, Lucknow, India

**Submitted:**  
23.02.2017

**Accepted:**  
23.05.2017

**Correspondence:**  
Bimalesh Purkait  
E-mail:  
purkaitbimalesh1@gmail.com

©Copyright 2017 by Turkish Association of Urology

Available online at  
www.turkishjournalofurology.com

## Introduction

Vesicouterine fistula (VUF) is an uncommon cause of female genito-urinary fistula. It comprises 1-4% of all urogenital fistulas.<sup>[1]</sup> Most of these fistulas are due to complications of lower segment cesarean section (LSCS). The incidence of this fistula is increasing all over the world because of increasing prevalence of cesarean section.<sup>[2]</sup> The presentation of VUF may vary from cyclic hematuria, amenorrhea, and infertility with or without urinary incontinence. The variant of VUF associated with urinary continence is called Youssef syndrome in which uterine cervix become competent and the opening of the fistulous tract is above the cervical os.<sup>[3]</sup> Open surgical repair is the traditional treatment of VUF, however minimally invasive treatments have recently been feasible.<sup>[2]</sup>

Laparoscopic repair of VUF is a minimally invasive technique and it has known advantages over open repair. Only few case reports have been published on laparoscopic repair of VUF with limited follow up. In this case series, we are presenting our experience of laparoscopic repair of VUF and long-term follow up data. The aim of this study was to analyze the long-term outcome of laparoscopic VUF repair. To the best of our knowledge, this is the largest laparoscopic series of VUF with long-term follow up reported in English literature.

## Material and methods

A retrospective analysis of 8 patients with VUF was performed from 2010 to 2015. Institutional Review Committee approval was taken. Informed consent was obtained from all patients. All had history of lower segment cesarean section (LSCS), and 3 patients had history of prolonged obstructed labor. Radiological imaging includes ultrasound of kidney, ureter and bladder for all patients and hysterosalpingography (HSG, Figure 1) in 4 patients and contrast enhanced computed tomography (CT) scan in 4 patients. VUF developed due to emergency cesarean section in all patients except one who underwent elective cesar-

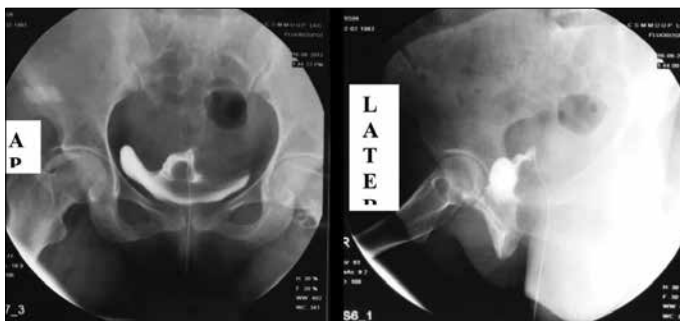

Figure 1. Hysterosalpingogram showing contrast agent leaking into urinary bladder

ean section because of placenta previa. All patients underwent laparoscopic repair by an experienced surgeon. Medical records regarding age, cause of fistula, clinical presentation, radiological imaging, operative details and follow up data have been collected and analyzed.

## Operative technique

Three ureteral catheters (6 Fr) were inserted initially with the patient in the lithotomy position into ureter orifices (n=2) and one into the fistula opening. A Foley catheter was inserted into the bladder. The patient was laid in supine position with head slightly tilted downward. A sponge stick was inserted through the vagina for manipulation of bladder/uterus during laparoscopic procedure if needed. Pneumoperitoneum was created using open Hasson technique. Standard 3 ports were used including one 12 mm (supra umbilical camera port) and two 5 mm ports on either side laterally (in pararectal area) in a triangular configuration. Goal of the dissection was to separate bladder from the uterus. Usually there will be dense adhesion between bladder and uterus due to previous operation. Sometimes bowel may adhere which needs careful dissection. Both sharp and blunt dissections (Figure 2a) started at the vesicouterine fold, and extended more posteriorly till fistulous communication was seen. Cystoscopically placed ureteral catheter helped to identify the level and location of the fistula (Figure 2c). Cystostomy was made in the posterior wall of bladder (Figure 2b) which was then extended to include fistula opening circumferentially. Uterine fistula was closed (Figure 2d) with interrupted 3-0 vicryl sutures and ureteral catheter gradually was pulled out from uterine cavity before tying the final knot. Bladder opening was closed (Figure 2e) with continuous 3-0 vicryl sutures in two layers in a watertight fashion and the ureteral catheter was withdrawn through urethra. Integrity of bladder repair was checked with filling of bladder with 200 mL of normal saline mixed with indigo carmine. The vesicouterine fold was then repositioned between bladder and uterus and suture-fixed over the anterior wall of uterus. Omental flap can also be mobilized and interposed if vesicouterine fold seems to be inadequate (Figure 2f). A tube drain was placed in the vesicouterine fold. Patient was started on anti-cholinergic medication on daily basis as soon as oral intake started.

## Results

Median age of the patients was 25.5 years (range, 22-32 years). The most common presentation was cyclical menstrual bleeding through urine (menouria) in all, associated amenorrhea in 6 and vaginal leakage of urine in 2 cases. All patients had successful outcomes (Table 1). The mean operating time was 155±14.5 min (range, 135-186 min) with median blood loss of 100 mL (range, 50-210 mL). The procedure was uncomplicated in all cases. Pelvic drain was removed when the urine output became <20 mL, usually on postoperative day 2. Ureteral catheters (cannulated in

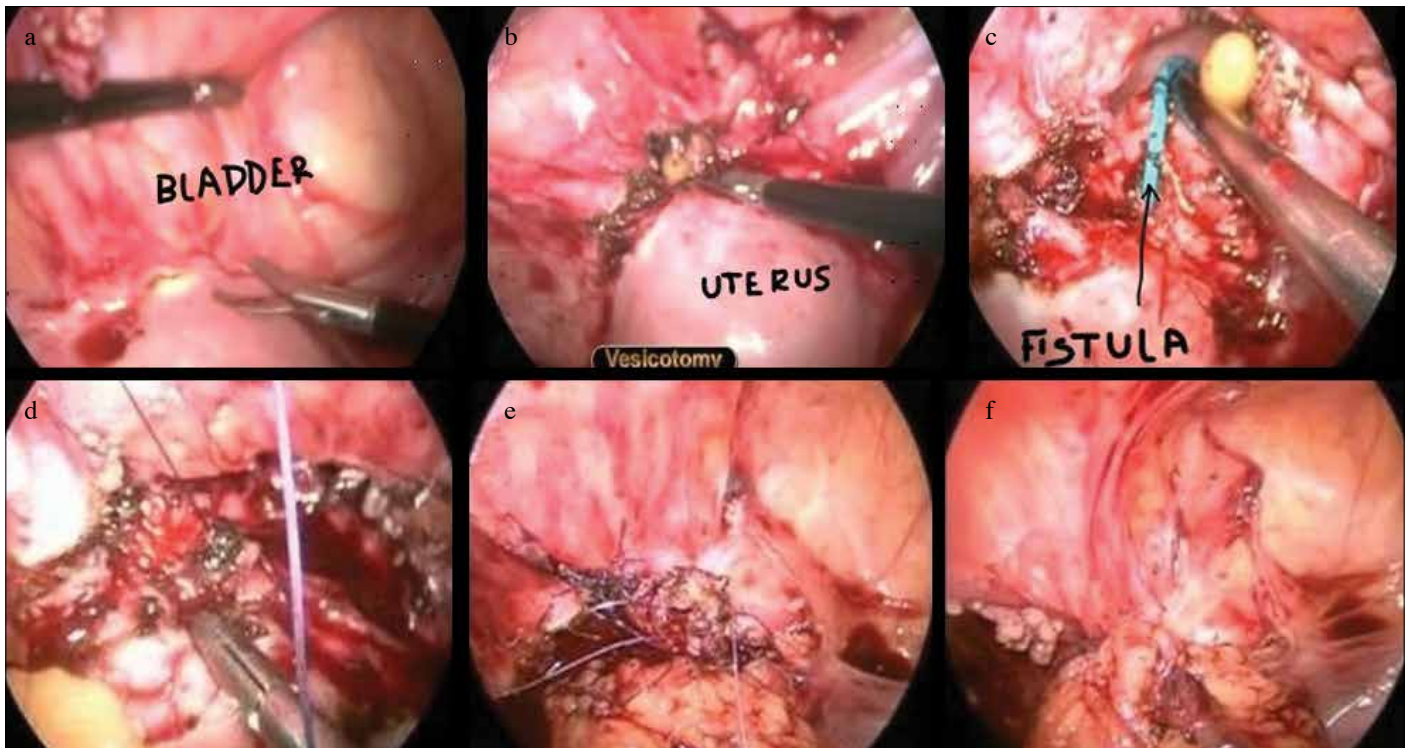


Figure 2. a-f. Techniques of laparoscopic repair: (a) Dissection between bladder and uterus, (b) vesicotomy made with scissor encircling fistula communication, (c) Fistulous communication and Foley catheter seen in the bladder, (d) closure of uterus, (e) closure of bladder and (f) omental flap transposition

Table 1. Presenting symptoms and outcomes

Patients	Age (year)	Presenting symptoms	Median operating time (min)	Result
1	31	Menouria, amenorrhea	171	Cured
2	22	Menouria, amenorrhea	186	Cured
3	30	Menouria, vaginal leakage of urine	137	Cured
4	27	Menouria, amenorrhea	148	Cured
5	32	Menouria, amenorrhea	151	Cured
6	24	Menouria, amenorrhea	135	Cured
7	26	Menouria, vaginal leakage of urine	150	Cured
8	24	Menouria, amenorrhea	166	Cured

orifices) were removed after 4-5 days. Cystograms were obtained after 2-3 weeks on outpatient basis and if there was no leak, we removed the Foley catheter. The mean hospital stay was  $9.4 \pm 2.4$  days (range, 7-12 days). Median follow-up was 2.3 years (range, 1-4 years). Successful pregnancy was completed in 2 patients and other patients were taking contraceptive measures.

## Discussion

Vesicouterine fistula is a rare iatrogenic urogenital fistula that communicates between urinary bladder and uterus or rarely

cervix. Emergency lower segment cesarean section is the most common cause of VUF which accounts for 2/3<sup>rd</sup> of the cases.<sup>[4]</sup> All patients in the present study had history of lower segment cesarean section. Excessive intraoperative bleeding, abnormal position of placenta (placenta previa/percreta), incomplete reflection of bladder wall from uterus, uterine rupture, attempted forceps delivery and previous cesarean section are significant risk factors for VUF.<sup>[5,6]</sup>

Clinical history, vaginal examination, cystography or hysterosalpingography and cystoscopy will be required for the diag-

nosis of VUF. HSG and cystoscopy can confirm the fistula but small fistula may not be identifiable with these modalities. Four patients in the present cohort had HSG study that showed leakage of contrast agent from uterus to the urinary bladder (Figure 1). Contrast-enhanced CT and MRI (magnetic resonance imaging) scan can delineate the fistulous communication and their relation to surrounding structures but they are not routinely recommended.<sup>[6,7]</sup>

Prevention of urogenital fistula has paramount importance. Not only it is associated with significant morbidity and social separation but also it has medicolegal consequences. Most of the patients are in the reproductive age group and face social challenge with great morbidity. Poor socioeconomic status and lack of proper medical facility often delay conservative or early definitive care. Careful separation of bladder from uterus, emptying bladder with Foley catheter, good hemostasis, and anticipation of difficulty in preoperative imaging (ultrasonography-placenta previa, percreata etc) and experience of surgeon have pivotal roles in preventing the formation of VUF. Urological care during an anticipated difficult operation may decrease the occurrence of VUF by identifying proper plane of dissection between bladder and uterus and repair of inadvertent bladder injury.

The role of conservative management for post partum small fistulas has been reported.<sup>[8,9]</sup> Conservative management includes continuous bladder drainage, antibiotics, judicious use of anti-muscarinic agents and hormonal manipulation, but the success rate is quite low as described by Hadzi-Djokic et al.<sup>[8]</sup> We did not find any of our patients suitable or willing for conservative therapy. The definitive management of VUF includes surgical disconnection either via open or minimally invasive technique. Minimally invasive techniques have added advantages of lower pain, shorter convalescence period, lesser hospital stay and better cosmetic results.

Basic principle of surgical treatment of VUF is disconnection of the fistulous communication and repair of bladder and uterus. The principles used in open surgery are also valid for laparoscopic technique. However, the treatment may differ if patient does not need further pregnancy in which case hysterectomy and closure of bladder opening will be the best treatment option. The technique of laparoscopic repair was described in an earlier study by Singh et al.<sup>[10]</sup> Most of the reported literature was either single case report or having fewer case series than the present study or mixed series including vesicovaginal fistula.<sup>[11-13]</sup> Naouar et al.<sup>[12]</sup> described a case of 42-year-old female with transperitoneal laparoscopic VUF repair. The operative time was 165 min and blood loss was 50 mL. No complication was reported in that case. Chibber et al.<sup>[14]</sup> reported 2 cases of laparoscopic VUF repair in a series of 8 urogenital fistulas (the remaining 6 cases were vesicovaginal fistulas). Median operating time was 220 min (190-280)

which was longer than our study (135-186 minutes) and any complication was not reported.<sup>[14]</sup> Aminsharifi et al.<sup>[15]</sup> described transperitoneal laparoscopic repair of two VUF with average time of 170 min and less than 100 mL blood loss. They obtained cystograms at 4 weeks postoperatively and urethral catheter was removed when there was no leakage on cystogram. At 6 months follow-up there was no recurrence. They concluded that laparoscopic repair of VUF is feasible and effective but longer follow-up data needed.<sup>[15]</sup> In the present study, cystograms were obtained for all patients at 2-3 weeks postoperatively with no leakage of contrast. Because of very rare incidence of VUF, the individual experiences in the management of these challenging cases are also limited in number. With expertise in managing vesicovaginal fistula (VVF, which is very common), we no longer performed routine postoperative cystographic examinations in all patients of VVF. However, we have performed postoperative cystographic examinations in all cases of VUF.

The laparoscopic repair of VUF requires expertise specially for intracorporeal suturing. Interposition of omentum or peritoneal flap is important to prevent future recurrence. The plane of dissection can be better appreciated with a ureteral catheter placed cystoscopically and brought through cervix and vagina through and through as previously described by the author.<sup>[16]</sup> We have used interposition flaps in all cases (one vesicouterine fold, 3 peritoneal fold and 4 omental interpositions). Previous surgery often leads to intraperitoneal nearby adhesion and one of the above-mentioned interposition flaps can be used according to availability and requirement.

Our study population consisted of relatively younger age group (22-32 years), while none of the patients underwent hysterectomy, and all were willing to preserve their uteruses. Over long-term follow up, successful pregnancy was achieved in two patients and rest of the patients was taking contraceptive measures. Cosmetic outcomes were excellent in all patients. In a retrospective analysis, Lotocki et al.<sup>[17]</sup> reported fertility rate following repair of vesicouterine fistula. Overall pregnancy rate was 31.25% with term delivery of 25%. Bonillo García et al.<sup>[18]</sup> reported 2 successful pregnancies out of 6 patients with minimum 2 years of follow up. All procedures were uneventful. No significant postoperative complication occurred in any patients.

Laparoscopic repair of VUF is rarely described in the literature. Our study is the largest series of laparoscopic repair of VUF with 100% success rate. However, our limitations include small number of patients and a single experienced urologist performed all the procedures.

In conclusion, laparoscopic repair of vesicouterine fistula is a safe and effective minimally invasive technique with successful pregnancy in long-term follow up.



**Ethics Committee Approval:** Ethics committee approval was received for this study from the ethics committee of King George's Medical University.

**Informed Consent:** Written informed consent was obtained from patients who participated in this study.

**Peer-review:** Externally peer-reviewed.

**Author Contributions:** Concept – B.P., V.S., S.M.; Design – B.P., S.M., V.B.; Supervision – B.P., S.M., R.S.J., V.S.; Materials – V.S., V.B., R.S.J.; Data Collection and/or Processing – B.P., V.S., S.M.; Analysis and/or Interpretation – B.P., S.M., V.B.; Literature Search – B.P., R.S.J., V.S.; Writing Manuscript – B.P., V.S., V.B.; Critical Review – R.S.J., V.S.

**Conflict of Interest:** No conflict of interest was declared by the authors.

**Financial Disclosure:** The authors declared that this study has received no financial support.

**Etik Komite Onayı:** Bu çalışma için etik komite onayı Kral George Tıp Üniversitesi'nden alınmıştır.

**Hasta Onamı:** Yazılı hasta onamı bu çalışmaya katılan hastalardan alınmıştır.

**Hakem Değerlendirmesi:** Dış bağımsız.

**Yazar Katkıları:** Fikir – B.P., V.S., S.M.; Tasarım – B.P., S.M., V.B.; Denetleme – B.P., S.M., R.S.J., V.S.; Malzemeler – V.S., V.B., R.S.J.; Veri Toplanması ve/veya İşlemesi – B.P., V.S., S.M.; Analiz ve/veya Yorum – B.P., S.M., V.B.; Literatür Taraması – B.P., R.S.J., V.S.; Yazıyı Yazan – B.P., V.S., V.B.; Eleştirel İnceleme – R.S.J., V.S.

**Çıkar Çatışması:** Yazarlar çıkar çatışması bildirmemişlerdir.

**Finansal Destek:** Yazarlar bu çalışma için finansal destek almadıklarını beyan etmişlerdir.

## References

- Ramamurthy S, Vijayan P, Rajendran S. Sonographic diagnosis of an uterovesical fistula. *J Ultrasound Med* 2002;21:817-9. [\[CrossRef\]](#)
- Porcaro AB, Zicari M, Zecchini Antonioli S, Pianon R, Monaco C, Migliorini F, et al. Vesicouterine fistulas following caesarean section: report on a case, review and update of the literature. *Int Urol Nephrol* 2002; 34:335-44. [\[CrossRef\]](#)
- Tancer ML. Vesicouterine fistula: A review. *Obstet Gynecol Surv* 1986;41:743-53. [\[CrossRef\]](#)
- Rao MP, Dwivedi US, Datta B, Vyas N, Nandy PR, Trivedi S, et al. Post caesarean vesicouterine fistulae-- Youssef syndrome: our experience and review of published work. *ANZ J Surg* 2006;76:243-5. [\[CrossRef\]](#)
- Iloabachie GC, Njoku O. Vesico-uterine fistula. *Br J Urol* 1985;57:438-9. [\[CrossRef\]](#)
- Yossepowitch O, Baniel J, Livne PM. Urological injuries during caesarean section: intraoperative diagnosis and management. *J Urol* 2004;172:196-9. [\[CrossRef\]](#)
- Shanmugasundaram R, Gopalakrishnan G, Kekre NS. Youssef's syndrome: Is there a better way to diagnose? *Indian J Urol* 2008;24:269-70. [\[CrossRef\]](#)
- Hadzi-Djokic JB, Pejic TP, Colovic VC. Vesico-uterine fistula: report of 14 cases. *BJU Int* 2007;100:1361-3. [\[CrossRef\]](#)
- Ravi B, Schiavello H, Abayev D, Kazimir M. Conservative management of vesicouterine fistula. A report of 2 cases. *J Reprod Med* 2003;48:989-91.
- Singh V, Mandhani PA, Mehrotra S, Sinha RJ. Laparoscopic repair of vesicouterine fistula: a brief report with review of literature. *Urol J* 2011;8:149-52.
- Maioli RA, Macedo AR, Garcia AR, Almeida SH, Rodrigues MA. Laparoscopic repair for vesicouterine fistulae. *Int Braz J Urol* 2015;41:1030-1. [\[CrossRef\]](#)
- Naouar S, Braiek S, El Kamel R. Laparoscopic Repair of Vesicouterine Fistula: A Case Report and Mini-Review of the Literature. *Journal of Current Surgery* 2016;6:75-7. [\[CrossRef\]](#)
- Mahapatra PD, Bhattacharyya P. Laparoscopic intraperitoneal repair of high-up urinary bladder fistula: a review of 12 cases. *Int Urogynecol J* 2007;18:635-9. [\[CrossRef\]](#)
- Chibber PJ, Shah HN, Jain P. Laparoscopic O'Conor's repair for vesico-vaginal and vesico-uterine fistulae. *BJU Int* 2005;96:183-6. [\[CrossRef\]](#)
- Aminsharifi A, Afsar F, Shirazi MK. A retrovesical approach for the laparoscopic repair of vesicouterine fistulas. *Int J Gynaecol Obstet* 2014;124:148-50. [\[CrossRef\]](#)
- Singh V, Mandhani PA, Mehrotra S, Sinha RJ. Cystohysteroscopy: novel use of semi-rigid ureteroscope to establish an access via fistulous tract between urinary bladder and vagina for confirming the diagnosis and facilitating laparoscopic repair of vesicouterine fistula. *J Endourol* 2011;25:913-5. [\[CrossRef\]](#)
- Lotocki W, Jóźwik M, Jóźwik M. Prognosis of fertility after surgical closure of vesicouterine fistula. *Eur J Obstet Gynecol Reprod Biol* 1996;64:87-90. [\[CrossRef\]](#)
- García MB, Bru JP, Martí JP, Alacreu JA, Gorrea MA, Guzmán SA, et al. Fistulas vesicouterinas. nuestra experiencia tras 25 años. *Actas Urológicas Españolas* 2003;27:707-12. [\[CrossRef\]](#)