



A novel method in decision making for the diagnosis of anterior urethral stricture: using methylene blue dye

Ön üretra darlığının tanısına karar vermede yeni bir yöntem: Metilen mavisi boyasının kullanılması

Pankaj Joshi¹, Cevdet Kaya², Sandesh Surana¹, Devang J. Desai¹, Hazem Orabi¹, Subramanian Iyer¹, Sanjay B. Kulkarni¹

Cite this article as: Joshi P, Kaya C, Surana S, Desai DJ, Orabi H, Iyer S, et al. A novel method in decision making of anterior urethral stricture diagnosis: Using methylene blue dye. Turk J Urol 2017; 43(4): 502-6

ABSTRACT

Objective: The use of methylene blue dye (MB) to highlight anatomical structures in urology has been well-established. Urethral stricture may extend about a centimeter beyond the abnormal area seen on urethrogram. Although the current literature suggests a tension-free and end-to-end anastomosis after excision of the strictured urethral segment with spongiofibrosis and surrounding corpus spongiosum in short bulbar strictures, some centers dealing with urethroplasty prefer anastomosis for short bulbar strictures while others prefer augmentation. With this study, use of MB for delineating stricture line and assessing spongiofibrosis in the diagnosis of urethral stricture was evaluated.

Material and methods: Five cc MB including 10 mg/mL is diluted with 10 cc saline. In the first scenario, MB is gently injected into urethra via the meatus before the urethroplasty procedure. Meanwhile, the extent of urethral segment stained by MB is noted. In the second scenario (MB spongiosography) in short bulbar stricture, insulin needles are inserted in spongiosa of the stricture site distally and proximally. MB is gently injected with distal needle. The two remaining needles are then observed. Presence of MB efflux in proximal needle implies deficiency of significant spongiofibrosis, so buccal augmentation is performed. Absence of efflux of MB implies significant spongiofibrosis and anastomotic site excised.

Results: Four hundred and ninety-two consecutive cases prospectively evaluated between 2010 and 2014. Precise staining of stricture was successfully observed in 464 (94%) patients. Grossly normal appearing urethelium remained pink. Histopathology confirmed that the stained urethra had a stricture. Of the 22 short bulbar idiopathic strictures, in 18 (82%) MB was seen across the stricture and urethral transection was avoided. Anastomosis was performed in 4 (18%) cases where no MB went across the primary excision. There were no known allergic complications.

Conclusion: MB aids in delineating the urethral lumen and exact site of stricture that needs augmentation. MB Spongiosography in short bulbar strictures could be used as a beneficial guide in relation to the type of urethral repair to be performed in terms of augmentation versus excision and anastomosis.

Keywords: Methylene blue dye; spongiofibrosis; urethra; urethroplasty; urethral stricture; urethral reconstruction.

ÖZ

Amaç: Ürolojide anatomik yapıların değerlendirilmesinde metilen mavisinin (MM) kullanılması oldukça iyi bilinmektedir. Üretra darlığı üretrogramda görülen patolojik alanın bir santimetre ötesine uzanabilir. Güncel literatür kısa bulber darlıklarda sponjiyofibrozla daralmış üretra segmentiyle birlikte çevreleyen spongiöz cismin eksizyonu sonrası uçuca gergin olmayan anastomozu önermesine rağmen; üretroplastiyile uğraşan bazı merkezler kısa bulber darlıklarda anastomozu bazılarını ise ogmentasyonu tercih etmektedir. Bu çalışma ile üretra darlığı tanısında darlık hattının tanımlanmasında ve sponjiyofibrozun değerlendirilmesinde MM'nin kullanımını değerlendirilmiştir.

Gereç ve yöntemler: On mg/mL konsantrasyonda 5 cc MM 10 cc salinle seyreltilir. İlk senaryoda MM üretroplastisi işleminden önce nazikçe meadan içeri üretraya enjekte edildi. Bu arada MM ile boyanmış üretra segmentinin uzunluğu kaydedilir. İkinci senaryoda kısa bulber darlıkta (MM sponjiyozografisi) insülin iğneleri darlık bölgesindeki spongiöz cismin proksimal ve distal uçlarına batırılır. Distaldeki iğneden nazikçe MM verilir. Daha sonra geri kalan iki iğne gözlemlenir. Proksimal iğneden MM'nin gelmesi önemli oranda sponjiyofibrozun olmadığını gösterir ve bukkal ogmentasyon gerçekleştirilir. Metilen mavisinin gelmemesi önemli oranda sponjiyofibroz varlığını gösterir ve eksizyon anastomozu yapılır.

Bulgular: Dört yüz doksan iki ardışık olgu 2010 ile 2014 yılları arasında prospektif olarak değerlendirilmiştir. Olguların %94'ünde (n=464) darlığın başarıyla ve doğru olarak boyandığı gözlenmiştir. Makros-

¹Kulkarni Reconstructive Urology Center, Pune, India

²Department of Urology, Marmara University School of Medicine, İstanbul, Turkey

Submitted:
16.02.2017

Accepted:
08.05.2017

Correspondence:
Pankaj Joshi
E-mail:
drpankajmjoshi@gmail.com

©Copyright 2017 by Turkish Association of Urology

Available online at
www.turkishjournalofurology.com

kopik olarak normal görünümlü ürotelyum pembe renkte kalmıştır. Histopatoloji boyalı üretrada darlık olduğunu doğrulamıştır. Yirmi iki kısa bulber idiyopatik darlığın 18'inde (%82) darlıkta MM görülmüş ve üretra transeksiyonundan kaçınılmıştır. MM görülmeyen 4 (%18) olguda primer eksizyon ve anastomoz gerçekleştirilmiştir. Bilinen herhangi bir alerjik komplikasyon olmamıştır.

Sonuç: Metilen mavisi üretra lümenini ve ogmentasyon gerektiren darlık bölgesini tam olarak tanımlamaya yardımcı olur. Kısa bulber darlıklarda MM sponjiyografisi, uygulanacak üretra onarımının tipini (ogmentasyon veya eksizyon + anastomoz) belirlemede yararlı bir kılavuz olarak kullanılabilir.

Anahtar Kelimeler: Metilen mavisi; sponjiyofibroz; üretra; üretroplasti; uretra darlığı; üretra rekonstrüksiyonu.

Introduction

The bulbar urethra is the most common anatomical site for urethral strictures with the etiology of idiopathic, iatrogenic and fall-astride perineal injuries.^[1] In a short segment bulbar urethral stricture, the standard form of urethroplasty is end-to-end anastomosis of the healthy edges of urethra after excision of the strictured segment including spongioblastic area and surrounding corpus spongiosum.^[2,3] Longer stricture with or without excision mostly require the management by an augmentation urethroplasty with buccal mucosa grafting.^[4] The raising of the question of whether to transect the urethra or not, helps to conclude that transecting the urethra allows complete removal of scar tissue resulting in higher success rates in the long term, but causes vascular damage and increased erectile dysfunction. On the other hand, augmentation technique may not completely remove the scar tissue leading to stricture recurrence, but it preserves urethral vasculature and erectile function.^[5]

The use of methylene blue (MB) to highlight anatomical structures in urology is a well-established practice. It has been used locally as well as intravenously in locating the ureteral orifice. Urethral stricture may extend about a centimeter beyond the abnormal area seen on urethrogram. Augmentation urethroplasty would be most likely to fail if the urethra is not augmented across the true extent of stricture. Also there are differing opinions regarding the management of short bulbar strictures. Some favor augmentation with buccal mucosal graft, while others favor excision and primary anastomosis (EPA). The divergence of opinion is unified toward EPA in the face of significant spongioblastic. Our objective is to determine if MB can be used to delineate the true extent of stricture and to assess the degree of spongioblastic in short atraumatic bulbar strictures.^[6]

Material and methods

This is a prospective study performed in a high volume tertiary referral center for the management of patients with urethral stricture (about 2400 urethroplasty operations have been performed since 1995). A total of 492 consecutive cases of anterior urethral stricture were prospectively evaluated between the years 2010, and 2014. The patients with a median age of 44.8 years (range, 19-68 years) underwent urethroplasty operation due to anterior urethral strictures. The etiologic factors in urethral strictures include lichen sclerosis in nearly 57% of cases

and iatrogenic, and idiopathic causes, trauma, infection in 43% of the patients.

Ethics committee approval was taken prior to enrollment of the patients into the study. We have been evaluating the use of methylene blue in urethra for 2 different scenarios since 2010. One of them is to delineate the extent of stricture and the other is to assess the degree of spongioblastic in short bulbar strictures. A freshly prepared sterile 5 cc MB (10 mg/mL), which is diluted in 10 cc of normal saline was used for both conditions.

In the first scenario, MB is gently injected retrogradely into the urethra at the beginning of the procedure. A penile clamp is applied for about 5 minutes to increase the contact time of the MB with the urethra (Figure 1). This allows methylene blue dye to traverse the narrow lumen of the stricture. Hence, the urethroplasty operation is commenced and the urethra is opened. This study on the impact of MB on the anatomy of the urethra was performed by subjective assessments of a single surgeon.

The second scenario is termed as the MB spongiography. In this method, the dissection for the urethroplasty continues until the bulbar urethra is exposed. After the location of the stricture is

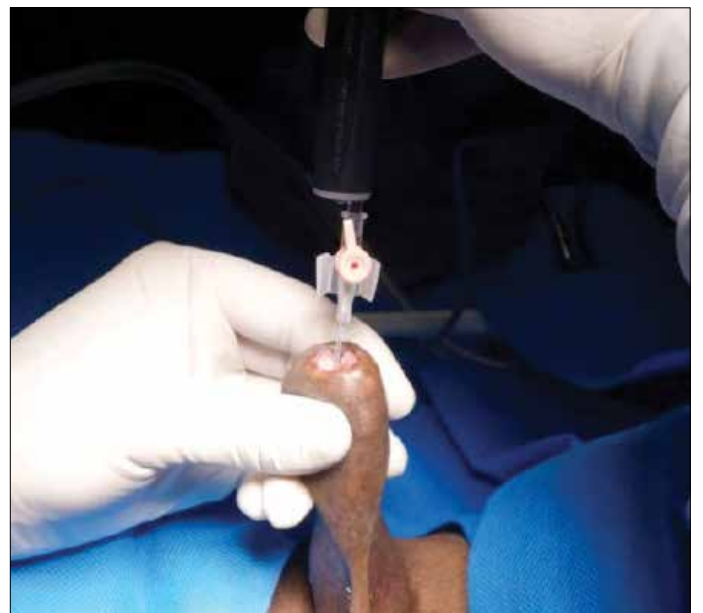

Figure 1. Methylene blue dye is gently injected retrogradely into the urethra at the beginning of the procedure

identified, insulin needles are inserted in three locations. One needle is placed into the spongiosum proximal to the stricture. Another needle is placed into the spongiosum at the level of stricture, and finally the third needle is placed in the spongiosum distal to the stricture. An atraumatic gentle clamp can be placed at the most proximal extent of the bulb to limit the confounding blood flow from the bulbar artery. At this point, methylene blue is gently injected via distal needle. The two remaining needles are then observed for MB efflux. Presence of MB efflux in the needle proximal to the stricture implies a deficiency of significant spongiofibrosis, so urethral transection with EPA is not performed. Absence of efflux of methylene blue in the proximal needle implies significant spongiofibrosis and EPA is performed (Figures 2 and 3).

Statistical analysis

Data was analyzed by means of IBM Statistical Package for Social Sciences (IBM SPSS Statistics; Armonk, NY, USA) Statistics 20 software.

Results

The precise staining of the narrow lumen was successfully observed in 94% (n=464) of the cases. In these 464 cases, the segment with urethral stricture was stained blue with MB. The grossly normal appearing urothelium remained pink and did not take up significant MB stain. In 28 (6%) cases, minimal or no

staining was observed. An extravasation into the spongiosa was seen in 8 (2%) cases. In 22 (4%) cases there was dense staining distal to the narrow lumen. Histopathology was performed in representative cases from both stained and unstained urethra. The area stained with methylene blue confirmed the presence of stricture. The unstained pink urethra revealed normal urothelium. There were no known allergic complications.

We performed MB spongiosography in 22 short bulbar idiopathic strictures. Median length of the stricture was 1.2 cm (range 1 to 1.5). In 18 (82%) cases, MB was seen across the stricture and urethral transection was avoided. In 4 (18%) cases where no MB went across, primary excision and anastomosis was performed. None of the patients had adverse reaction or complication related to administration of methylene blue.

Discussion

Methylene blue has been described as “the first fully synthetic drug used in medicine.” Its use in the treatment of malaria was pioneered by Paul Guttman and Paul Ehrlich in 1891. Researchers believed that drugs and dyes worked in the same way, by preferentially staining pathogens and possibly harming them. MB continued to be used in the Second World War, where it was not well liked by soldiers, who observed, “Even at the loo, we see, we pee, navy blue”. The blue urine was used to monitor psychiatric patients’ compliance with drug regimes.^[7] Side effects of systemically used MB include hypertension, dizziness, confusion, headache, injection site necrosis, discoloration of body fluids and vomiting.^[8]

Publications from Kulkarni and Barbagli^[6] regarding techniques in urethroplasty have mentioned the use of MB injections in the urethra prior to urethroplasty. However any prospective study has not been done to evaluate the effectiveness of this technique. Each urologist dealing with cases of urethral stricture know that the MB stains urothelium in the stricture zone but not the normal urethra. The healthy urothelium is water proof and not permeable to fluids. Nonetheless, the stricture causes gaps in between

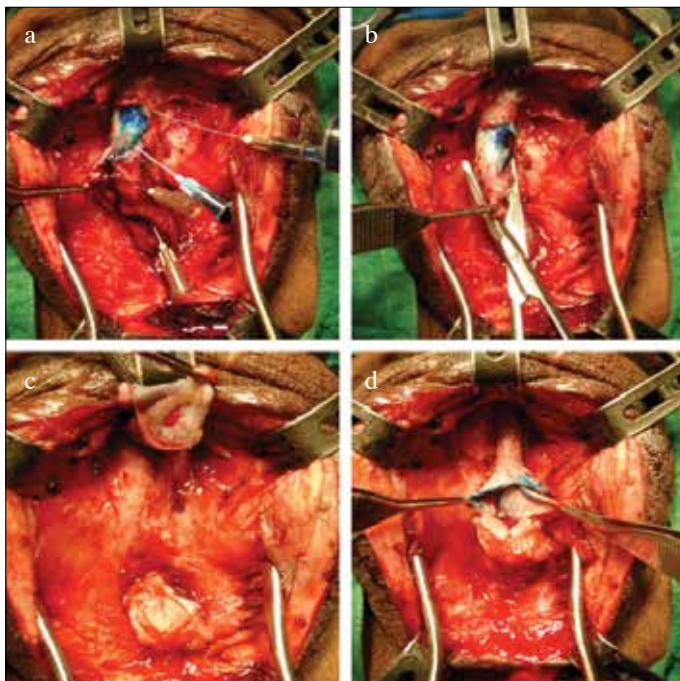


Figure 2. a-d. If methylene blue does not go beyond the strictured area (a), the urethra is transected (b, c), and the anastomosis is performed (d)

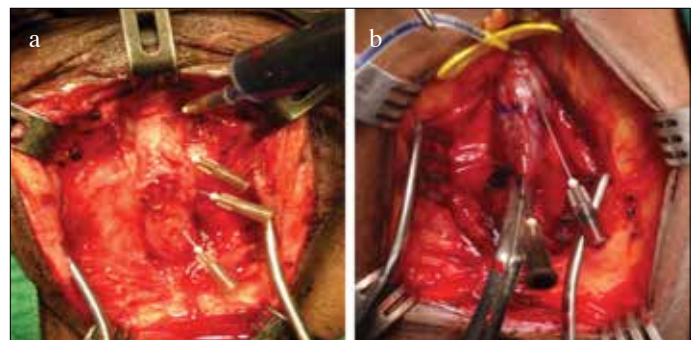


Figure 3. a, b. If the methylene blue dye goes across the stricture (a), then the augmentation technique is performed (b)

the cells. This allows for staining of the abnormal epithelium. However, as of now, there is no molecular basis to explain the staining of strictured abnormal epithelium. There are 2 distinct advantages of injecting MB in the urethra. First, the MB stains the strictured epithelium and therefore allows us to assess the length of urethra that merits augmentation. The graft should extend more proximally and distally than the length of the stricture. The recurrence after urethroplasty can be associated with inadequate placement of the graft.^[8] The property of MB to stain strictured urethra can be thus used to our advantage.

Secondly, many strictures are almost obliterative and guidewire or narrow ureteral catheter may not pass across the stricture before resorting to the surgical procedure. While incising the urethra, we may not precisely incise urethral lumen due to near obliterative nature of stricture, and this may lead to false passage. MB stains urethra precisely and gives us exact guide to incise the strictured lumen. Both uses of MB have not been mentioned in the literature so far.

Short bulbar strictures have ongoing controversy regarding the optimal modality of treatment. Many reconstructive urologists across the world debate about alternatives of anastomotic versus augmentation urethroplasty for bulbar strictures. However, the success rate of anastomotic urethroplasty is higher than augmentation urethroplasty.^[5,9,10] There are concerns regarding erectile dysfunction and ejaculatory dysfunction after bulbar urethroplasty.

Angermeier suggested augmentation urethroplasty in longer strictures requiring excision in which the ventral spongiosum is anastomosed in an end-to-end fashion and the dorsal aspect is augmented with a graft.^[4,11] If the stricture is not excised, then a simple oral grafting augmentation procedure is appropriate. But some studies recently suggested successful end-to-end anastomosis for proximal bulbar strictures even up to 5 cm.^[12] In his blood supply preserving technique of modification to end-to-end anastomosis, Jordan et al.^[13] reported that 98.8% of the patients were symptom-free and required no further procedures after excision and end-to-end anastomosis for bulbar strictures. Early (n=2), and late-term (n=1) recurrent strictures also occurred. As complications position-related neuropraxia was encountered in 3.4% of the patients all of which resolved within the early postoperative period. Erectile dysfunction was encountered in only 2.3% of the patients, among whom some had a history of significant straddle trauma who later responded well to oral pharmacotherapy.^[13]

Barbagli et al.^[14] published a brief review on the treatment of short bulbar strictures. They highlighted studies comparing anastomotic urethroplasty and buccal mucosa augmentation for bulbar strictures. Guralnick and Webster^[10] suggested that end-to-end anastomosis is appropriate only for a bulbar stricture of 1 cm or

less. The authors emphasized that excision of a longer urethral segment conveys risks of penile shortening or chordee, even if lengthening manoeuvres are applied. On the contrary, Morey and Kizer^[15] reported 22 patients with proximal bulbar urethral strictures longer than 2.5 cm (range 2.6 - 5 cm) that were managed using an extended anastomotic approach, and suggesting that the possibility of reconstructing the urethra is proportional to the length and elasticity of the distal urethral segment. They reported a 91% success rate with a median follow-up of 22.1 months, and with no increase in erectile complaints compared to shorter strictures.

Chen et al.^[16] presented a study on 47 short urethral strictures treated with end-to-end anastomosis or buccal mucosal graft urethroplasty and compared the results to determine the best technique. The recurrence rate was 7% in patients who underwent end-to-end anastomosis, however in patients who underwent buccal mucosal graft urethroplasty any disease recurrence had not occurred. Complications including chordee and erectile dysfunction occurred in 18% of the patients after anastomotic repair. In their conclusion, buccal mucosal onlay graft urethroplasty is suggested as the operation of choice even for short urethral strictures.

Barbagli et al.^[17] performed retrospective evaluation and statistical analysis of outcomes in patients who underwent bulbar end-to-end anastomosis, reported that 23.3% of the patients had postoperative ejaculation difficulty and 31.6% had neurovascular disorders of the glans or distal penile shaft. The most frequent postoperative ejaculation disorder was decreased force of ejaculation jet (20%). The most frequent postoperative neurovascular disorder was decreased sensitivity of the glans or distal penile shaft. It was stated that further studies are necessary to clarify the etiology of these neurovascular disorders and identify the modality to fully preserve the neurovascular supply to the glans and penile shaft during end-to-end anastomosis.

The incidence of sexual complications is higher after excision and primary anastomosis (EPA) as compared to augmentation urethroplasty. We apply EPA only for traumatic strictures. However, at times, we have patients with unclear history of trauma and these could be rooting from significant spongiofibrosis. Although ultrasound could be used as an adjunctive tool, we needed an intraoperative assessment of spongiofibrosis. With this need, Our test of MB spongiosography was performed based on this requirement.

According to Mundy^[18] and Mundy and Andrich^[19], anastomotic urethroplasty is only applicable in two situations. As first, it could be practised for short 1-2 cm long strictures of the bulbar urethra with traumatic aetiology or for idiopathic strictures. The external trauma is usually a straddle injury. The second situation is a pelvic fracture related to injury of the membranous urethra or bulbo-membranous junction.

Although our center is a tertiary referral center, so we have a large number of urethroplasty cases, MB dye was effectively used to decide the type of surgery, there are some limitations to the present study. Firstly, the anterior urethra occasionally does not get stained with MB dye and then it becomes tough to decide the exact length of the stricture during surgery. Secondly, if one injects the MB with too much force, it may cause extravasation of the dye resulting in some diagnostic difficulty after the procedure.

Our test of MB spongiosography is an effective clinical intraoperative adjunct to decide on the appropriateness of transecting versus non-transecting augmentation urethroplasty. It has become a standard test in our unit for short bulbar strictures with unclear etiology.

In conclusion, the use of MB is found to be a useful tool in urethroplasty. Firstly, it helps us in delineation of the extension of the stricture and identification of the urethral lumen. Secondly, MB spongiosography helps to guide the type of urethral repair to be performed. In our high volume tertiary referral unit, injection of MB into urethra immediately prior to urethroplasty has become a standard procedure. Furthermore, intraurethral injection and MB spongiosography can be regarded as simple and cost-effective tools in urethral surgery.

Ethics Committee Approval: Ethics committee approval was received for this study from the ethics committee of Kulkarni Reconstructive Urology Center.

Informed Consent: Written informed consent was obtained from patients who participated in this study.

Peer-review: Externally peer-reviewed.

Author Contributions: Concept – S.B.K., P.J., S.I.; Design – C.K., S.B.K., P.J., S.I.; Supervision – S.S., D.J.D., H.O., S.I.; Resources – S.B.K.; Materials – S.B.K., S.S., D.J.D., H.O., S.I.; Data Collection and/or Processing – S.B.K., P.J., C.K., S.I.; Analysis and/or Interpretation – S.B.K., P.J., C.K.; Literature Search – S.B.K.; Writing Manuscript – C.K., S.B.K., P.J., S.I.; Critical Review – C.K.

Conflict of Interest: No conflict of interest was declared by the authors.

Financial Disclosure: The authors declared that this study has received no financial support.

Etik Komite Onayı: Bu çalışma için etik komite Kulkarni Reconstructive Urology Center Etik Kurulu'ndan alınmıştır.

Hasta Onamı: Yazılı hasta onamı bu çalışmaya katılan hastalardan alınmıştır.

Hakem Değerlendirmesi: Dış bağımsız.

Yazar Katkıları: Fikir – S.B.K., P.J., S.I.; Tasarım – C.K., S.B.K., P.J., S.I.; Denetleme – S.S., D.J.D., H.O., S.I.; Kaynaklar – S.B.K.; Malzemeler – S.B.K., S.S., D.J.D., H.O., S.I.; Veri Toplanması ve/veya İşlemesi – S.B.K., P.J., C.K., S.I.; Analiz ve/veya Yorum – S.B.K., P.J.,

C.K.; Literatür Taraması – S.B.K.; Yazıyı Yazan – C.K., S.B.K., P.J., S.I.; Eleştirel İnceleme – C.K.

Çıkar Çatışması: Yazarlar çıkar çatışması bildirmemişlerdir.

Finansal Destek: Yazarlar bu çalışma için finansal destek almadıklarını beyan etmişlerdir.

References

- Hampson LA, McAninch JW, Breyer BN. Male urethral strictures and their management. *Nat Rev Urol* 2014;11:43-50. [CrossRef]
- Joshi P, Kaya C, Kulkarni S. Approach to bulbar urethral strictures: Which technique and when? *Turk J Urol* 2016; 42:53-9. [CrossRef]
- Mundy AR. Anastomotic urethroplasty. *BJU Int* 2005;96:921-44. [CrossRef]
- Abouassaly R, Angermeier KW. Augmented anastomotic urethroplasty. *J Urol* 2007;177:2211-6. [CrossRef]
- Bugeja S, Andrich DE, Mundy AR. Non-transecting bulbar urethroplasty. *Trans Androl Urol* 2015;4:41-50.
- Kulkarni SB, Barbagli G. *Art of urethral Reconstruction*. Elsevier. 2012.
- Available from: https://en.wikipedia.org/wiki/Methylene_blue
- Al-Qudah HS, Santucci RA. Buccal mucosal onlayurethroplasty versus anastomotic urethroplasty (AU) for short urethral strictures: which is better? *J Urol* 2006;175(Suppl):abstract 313.
- Morey AF, Watkin N, Shenfeld O, Eltahawy E, Giudice C. SIU/ICUD Consultation on urethral strictures: Anterior urethra-primary anastomosis. *Urology* 2014;83:S23-6. [CrossRef]
- Guralnick ML, Webster GD. The augmented anastomotic urethroplasty: indications and outcome in 29 patients. *J Urol* 2001;165:1496-501. [CrossRef]
- Mori RL, Angermeier KW. Staged urethroplasty in the management of complex anterior urethral stricture disease. *Transl Androl Urol* 2015;1:29-34.
- Terlecki RP, Steele MC, Valadez C, Morey AF. Grafts are unnecessary for proximal bulbar reconstruction. *J Urol* 2010;184:2395-9. [CrossRef]
- Jordan GH, Eltahawy EA, Virasoro R. The technique of vessel sparing excision and primary anastomosis for proximal bulbous urethral reconstruction. *J Urol* 2007;177:1799-802. [CrossRef]
- Barbagli G, Lazzeri M. Surgical treatment of anterior urethral stricture diseases: brief overview. *Int Braz J Urol* 2007;33:461-9. [CrossRef]
- Morey AF, Kizer WS. Proximal bulbar urethroplasty via extended anastomotic approach--what are the limits? *J Urol* 2006;175:2145-9. [CrossRef]
- Chen ML, Odom BD, Santucci RA. Substitution urethroplasty is as successful as anastomotic urethroplasty for short bulbar strictures. *Can J Urol* 2014;21:7565-9.
- Barbagli G, De Angelis M, Romano G, Lazzeri M. Long-Term Follow up of Bulbar End-to-End Anastomosis: A Retrospective Analysis. *J Urol* 2007;178:2470-3. [CrossRef]
- Mundy A. Management of urethral strictures. *Postgrad Med J* 2006;82:489-93. [CrossRef]
- Mundy A, Andrich DE. Urethral strictures. *BJU Int* 2011;107:6-26. [CrossRef]