



# Does antegrade JJ stenting affect the total operative time during laparoscopic pyeloplasty?

## Laparoskopik pyeloplasti sırasında antegrad JJ stent yerleştirme, operasyon süresini etkiler mi?

Mustafa Suat Bolat, Önder Çınar, Ekrem Akdeniz

**Cite this article as:** Bolat MS, Çınar Ö, Akdeniz E. Does antegrade JJ stenting affect the total operative time during laparoscopic pyeloplasty? Turk J Urol 2017; 43(4): 497-501.

### ABSTRACT

**Objective:** We aimed to show the effect of retrograde JJ stenting and intraoperative antegrade JJ stenting techniques on operative time in patients who underwent laparoscopic pyeloplasty.

**Material and methods:** A total of 34 patients were retrospectively investigated (15 male and 19 female) with ureteropelvic junction obstruction. Of the patients stentized under local anesthesia preoperatively, as a part of surgery, 15 were retrogradely stentized at the beginning of the procedure (Group 1), and 19 were antegradely stentized during the procedure (Group 2). A transperitoneal dismembered pyeloplasty technique was performed in all patients. The two groups were retrospectively compared in terms of complications, the mean total operative time, and the mean stenting times.

**Results:** The mean ages of the patients were  $31.5 \pm 15.5$  and  $33.2 \pm 15.5$  years ( $p=0.09$ ), and the mean body mass indexes were  $25.8 \pm 5.6$  and  $26.2 \pm 8.4$  kg/m<sup>2</sup> in Group 1 and Group 2, respectively. The mean total operative times were  $128.9 \pm 38.9$  min and  $112.7 \pm 21.9$  min ( $p=0.04$ ); the mean stenting times were  $12.6 \pm 5.4$  min and  $3.5 \pm 2.4$  min ( $p=0.02$ ); and the mean rates of catheterization-to-total surgery times were 0.1 and 0.03 ( $p=0.01$ ) in Group 1 and 2, respectively. The mean hospital stays and the mean anastomosis times were similar between the two groups ( $p>0.05$ ).

**Conclusion:** Antegrade JJ stenting during laparoscopic pyeloplasty significantly decreased the total operative time.

**Keywords:** Antegrade stenting; laparoscopic pyeloplasty; operative time; retrograde stenting.

### ÖZ

**Amaç:** Laparoskopik pyeloplasti uygulanan hastalarda retrograd ve intraoperatif antegrad JJ stent uygulama tekniğinin ameliyat süresi üzerine etkisini göstermeyi amaçladık.

**Gereç ve yöntemler:** Ureteropelvik darlık nedeniyle transperitoneal laparoskopik pyeloplasti yapılan toplam 34 hastanın bulguları retrospektif olarak incelendi. Hastaların 15'ine laparoskopik cerrahiye başlamadan hemen önce retrograd olarak stent uygulaması yapıldı (Grup 1) ve 19 hastaya işlem sırasında antegrad stent yerleştirildi (Grup 2). İki grubun komplikasyonları, total ameliyat süreleri ve stent yerleştirme süreleri geriye dönük olarak karşılaştırıldı.

**Bulgular:** Grup 1 ve Grup 2'de hastaların yaş ortalaması  $31,5 \pm 15,5$  ve  $33,2 \pm 15,5$  yıl ( $p=0,09$ ); ortalama vücut kitle indeksleri  $25,8 \pm 5,6$  ve  $26,2 \pm 8,4$  kg/m<sup>2</sup> idi. Total cerrahi süreleri  $128,9 \pm 38,9$  ve  $112,7 \pm 21,9$  dakika; ortalama JJ stent yerleştirme süresi  $12,6 \pm 5,4$  ve  $3,5 \pm 2,4$  dakika bulundu ( $p=0,02$ ). Ortalama JJ kateterizasyonun total cerrahi süreye oranı Grup 1'de 0,1; Grup 2'de ise 0,03 ( $p=0,01$ ) bulundu. Hastane ortalama kalış süresi ve ortalama anastomoz süreleri iki grup arasında benzerdi ( $p>0,05$ ).

**Sonuç:** Laparoskopik pyeloplasti sırasında yapılan antegrad JJ stent uygulaması, retrograd tekniğe göre cerrahi süreyi belirgin olarak kısaltmaktadır.

**Anahtar Kelimeler:** Antegrad stentleme; laparoskopik pyeloplasti; operasyon süresi; retrograd stentleme.

### Introduction

A ureteropelvic junction obstruction (UPJO) is the most commonly seen pathology of the

upper urinary system either due to congenital or acquired diseases.<sup>[1]</sup> Because of the disease's slow progression, a gradual loss of renal function is expected. Since the first laparoscopic

Department of Urology, Health Sciences University, Samsun Training and Research Hospital

**Submitted:**  
12.05.2017

**Accepted:**  
20.06.2017

**Correspondence:**  
Mustafa Suat Bolat  
E-mail:  
msbolat@gmail.com

©Copyright 2017 by Turkish Association of Urology

Available online at  
www.turkishjournalofurology.com

pyeloplasty was defined by Kavoussi, and with the advent of technological improvements, this minimally invasive procedure has shown comparable functional results to traditional open surgery.<sup>[2,3]</sup> Laparoscopic pyeloplasty has now taken its place as a rapid, effective, and standard technique that removes the need to reposition the patient.<sup>[4]</sup> Many studies have compared retrograde and antegrade stenting techniques. Laparoscopic antegrade JJ stenting diminishes the need for an additional procedure and decreases the risk of complications, such as the stent being cut or migrating upward.<sup>[5]</sup> Moreover, antegrade JJ stenting provides better anatomical delineation and dissection around the ureteropelvic junction (UPJ) since the renal pelvis remains distended. However, Papalia et al.<sup>[6]</sup> reported that retrograde JJ stenting was a favorable technique with a high success rate.

Acceptable pain levels, shorter hospital stays, faster convalescence, and less scarring are the most pronounced advantages of laparoscopic pyeloplasty compared to the open technique.<sup>[7]</sup> In addition to its functional results, the duration of the surgery is also important for both the patient and the surgeon. In this study, we compared the differences in the surgery times of the patients who were intraoperatively JJ stentized immediately after the completion of the posterior ureteropelvic anastomosis and the patients who underwent retrograde JJ stenting before the laparoscopic pyeloplasty.

## Material and methods

### Study design

A total of 34 patients were retrospectively investigated (15 male and 19 female) with UPJO between June 2011 and December 2016. This work was designed in accordance with the Helsinki Declaration. Preoperative renal ultrasonography and renal diuretic scintigraphy were routinely done. In a 13-year-old pediatric patient, a voiding cystogram was performed to exclude vesicoureteral reflux, because it may result with secondary UPJO. Written informed consent was obtained from the participants or their parents. The 34 patients were separated into two groups: Group 1 had 15 patients, and Group 2 had 19 patients. Preoperative characteristics, intraoperative variables, and postoperative findings were recorded.

### Inclusion criteria

Cases with hydronephrosis that was confirmed by preoperative ultrasound/intravenous urography and that had a T1/2 radionuclide excretion time longer than 20 minutes on a renal scintigraphy were included in this study.

### Exclusion criteria

Patients with a history of previous renal surgery, those with multiple renal pelvic calculi, those who were unfit to undergo laparoscopic surgery, and those who have other congenital or acquired anomalies were excluded.

### Patient characteristics

The characteristics of the patients included the age at surgery, gender, laterality, body mass index (BMI), presence of aberrant crossing vessels, number of comorbidities, and complications.

### Surgical procedure

In Group 1, 15 patients were retrogradely stentized at the beginning of the procedure with a 4.8 Fr JJ catheter using a 21 Fr rigid cystoscope under direct vision. In Group 2, patients in flank position were antegradely stentized during laparoscopic procedure; under general anesthesia, following nasogastric tube decompression and a urethral Foley catheter insertion. A 10-mm trocar was placed for camera at five cm lateral to the umbilicus using the Hasson technique. Our preference is the open Hasson technique for the introduction of the first trocar in order to insert the other trocars under direct vision. A pneumoperitoneum was created using carbon dioxide 3.5 L/min until 12 mmHg pressure was reached, and additional 10 mm and five mm trocars were placed more laterally to the upper and lower quadrants in order to obtain a triangular shape. 10-mm trocar was placed for camera at five cm lateral to the umbilicus using the Hasson technique. A flattened suture needle was used for stabilization of the anastomotic site through the abdominal wall under direct vision for traction (Figure 1). A dismembered pyeloplasty technique was performed for all the patients. Routine steps-including mobilization of the colon and entering into the retroperitoneum, exploration of the UPJO, excision of the stenotic part of the tissue, and then sufficient spatulation-were completed. In Group 2, 19 patients were antegradely catheterized during the procedure. A 4.8 Fr JJ catheter was advanced antegradely after the completion of the posterior ureteropelvic anastomosis, in the guidance of a 12 Fr Amplatz dilator using the manual navigation of its tip closer to the ureteral lumen. After placement of the stent, anterior anastomosis was completed (Figure 2).



Figure 1. A flattened suture needle application for stabilization of the anastomotic site through the abdominal wall

The antegrade stenting time was defined as the period between the insertion of the Amplatz dilator and placement of the distal tip of the stent into the ureter and the proximal tip into the renal pelvis. The retrograde stenting time was defined as the time between putting the patient in the lithotomy position, introducing the JJ catheter using the cystoscope, and urethral Foley catheterization.

Time period from the anesthesia induction until the patients were completely awoken after the surgery at the end of the procedure was defined as the surgery time in Group 1 and Group 2. The data were obtained from Excel worksheets in which the operative steps had been previously recorded.

**Follow-up**

Imaging studies were performed six to eight weeks after the procedure to show that there was no residual obstruction. Unless the patients experienced a recurrence of flank pain or had evidence of a urinary tract infection at the first postoperative control, they were monitored with imaging studies twice in a year. Because an obstruction can occur any time after surgery, patients were generally advised to have a lifetime of follow-ups. The surgery success criteria were defined as the cessation of patient symptoms, ultrasonic improvement of hydronephrosis, and scintigraphically measured improvement in urine drainage that did not require additional any intervention.

**Complications**

All patient charts, including the medical records of patients with categorized postoperative complications, were reviewed and stratified according to the Clavien-Dindo classification. Medical and surgical complications during the first six weeks were evaluated at the end of this period using medical records from our institution as well as reports from the radiologic findings.

**Statistical analysis**

Data analyses were performed using the Statistical Package for the Social Sciences (IBM SPSS Statistics; Armonk, NY, USA) 21.0 for Windows. The data were presented as mean ± standard deviation

(SD) and frequency (%). Comparisons between the groups were performed using the chi-square test for qualitative variables and the Mann-Whitney U test for quantitative variables. For non-parametric variables, a Student’s t-test with equal variance was used. A p value of <0.05 was considered to be statistically significant.

**Results**

The female-to-male ratios were 9/6 in Group 1 and 10/9 in Group 2. The mean ages of the patients were 31.5±15.5 years (13-51) and 33.2±15.5 years (16.3-59), and the mean BMIs were 25.8±5.6 kg/m<sup>2</sup> (19.2-33.4) and 26.2±8.4 kg/m<sup>2</sup> (18.1-35.8) in Group 1 and Group 2, respectively (Table 1). Nine patients (60%) in Group 1 and eight patients (42.1%) in Group 2 had right UPJO, whereas six patients (40%) in Group 1 and 11 patients (57.9%) in Group 2 had right UPJO.

The mean age of the patients was similar between the two groups (p=0.09). Nine patients (60%) in Group 1, and 11 patients (57.9%) in Group 2 revealed aberrant crossing vessels (Table 1) (p=0.21). The mean total surgery times were 128.9±38.9 min (118-245) and 112.7±21.9 min (95-210) (p=0.04); the mean stenting times were 12.6±5.4 min and 3.5±2.4 min (p=0.02); and the mean rates of stenting-to-total surgery times were 0.1 and 0.03 (p=0.01) in Group 1 and Group 2, respectively. The mean hospital stays and the mean anastomosis times were similar between the two groups (p>0.05) (Table 2).

The mean follow-up periods were 54.7±7 months in Group 1, and 57.1±2 months in Group 2 (p=0.11). A prolonged ileus in one patient (6.7%) and subcutaneous emphysema in two patients (13.3%) were reported in Group 1; persistent pain in one patient (5.3%) and subcutaneous emphysema in one patient (5.3%) were recorded in Group 2. No significant complications were reported between the two groups.

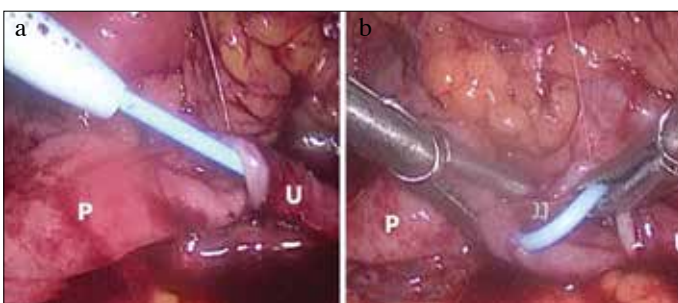


Figure 2. a, b. Antegrade JJ catheter placement with the guidance of 12 Fr Amplatz dilator after completion of posterior ureteropelvic anastomosis

Table 1. Demographic and peroperative characteristics of the groups			
	Group 1 (n=15)	Group 2 (n=19)	p
Gender (Female/male)	9/6	10/9	-
Age (year±SD) (min-max)	31.5±15.5 (13-51)	33.2±15.5 (16.3-59)	0.09
BMI (kg/m <sup>2</sup> ) (min-max)	25.8±5.6 (19.2-33.4)	26.2±8.4 (18.1-35.8)	0.18
Aberrant crossing vessel (n, %)	9 (60.0)	11 (57.9)	0.21
Laterality (n, %)			
Right	9 (60)	8 (42.1)	
Left	6 (40)	11 (57.9)	-
BMI: body mass index			

## Discussion

Stenting is a one of the critical stages of laparoscopic pyeloplasty, though stentless procedures have been reported in the literature.<sup>[8]</sup> JJ stenting decreases the risk of urinary leakage (resulting in urinary ascites and bowel paralysis) from the anastomotic site, which is particularly vital in the transperitoneal approach.<sup>[9]</sup> It is important to place the JJ catheter safely within a short period of time as well as to place it without causing complications, which can include ureteral perforation, urethral displacement of the distal end of the JJ stent, and fixation. Although most studies initially reported retrograde stenting during laparoscopic pyeloplasty,<sup>[10]</sup> recent studies investigating the efficacy of antegrade stenting have been published in recent years.<sup>[11]</sup> Retrograde pyelography and stenting were defined routine initial steps in the literature, prior the laparoscopic procedure that entail an additional procedure with added time and resources.<sup>[12-14]</sup> In compatible with literature, our findings on both the mean antegrade stenting time was shorter, and the antegrade stenting-to-total operative time ratio was significantly much less than that of the retrograde route.

In absence of a standardized technique, JJ stenting may become a bothersome stage of laparoscopic correction of UPJO. Although many stent placement techniques have been defined, but none of them is accepted as the gold standard. It may possible to reduce the operative time, and thus to reduce the complications associated with it, using a standardized technique.<sup>[15]</sup> It is reasonable to assume that many urologists are experienced in the practice of retrograde JJ stenting, and there is no doubt that the duration of the retrograde stenting is already short. However, as a surgeon becomes more experienced in laparoscopy, the duration of the anterior JJ stenting time can be shortened. From this point of view, a shorter operative time decreases. Complications due to JJ stenting that occur during insertion or due to the presence of

the JJ stent in situ are described in the literature.<sup>[16]</sup> Mandhani et al.<sup>[5]</sup> recognized inadvertent injury to the ureterovesical junction. Although it is expected that JJ catheter-related complications can be seen in both techniques,<sup>[17]</sup> retrograde and antegrade ureteral JJ stenting were associated with no increase in complications in the present study.

Another advantage of antegrade stenting is apart from saving operative time, antegrade stenting allows the renal pelvis to remain distended, which helps in identifying of the ureteropelvic junction and in subsequent dissection around the ureter. Prior stent placement using retrograde route may resulted with decompression of renal pelvis. Preoperative retrogradely inserted JJ stent might hampered suturing during the posterior part of the anastomosis.<sup>[18]</sup> Similarly it was reported posterior stent placement negatively affected surgeon ability to suture the posterior layer, and repeated manipulations to keep the stent away from the suturing line could lead to its cut, or upward migration.

The risk of complications-such as deep vein thrombosis, serious infections, and sepsis-due to anesthesia and the comorbidity of the patient. Daley et al.<sup>[19]</sup> showed that an additional hour of operative time over standard was associated with a 16.6 times higher risk of sepsis.

Another issue is whether the ureter should be visualized for additional pathology before pyeloplasty in patients. A retrograde stenting can actually be done in the first plan to visualize the ureter and the UPJ and-if present-to correct the additional pathology. In fact, a majority of urologists still have this clinical dilemma in their daily practice. Because the rate of coincidental distal ureteral pathologies can vary in patients with UPJO, some researchers advocate performing a retrograde pyelogram plus retrograde JJ stenting.<sup>[20]</sup> However, many other studies maintain that doing routine retrograde pyelography to define the level of obstruction is not necessary for successful primary pyeloplasty.<sup>[21,22]</sup> In accordance with these reports, we started to use the antegrade stenting method as we improved our experience, though we routinely performed retrograde stenting in the early stages of our laparoscopic practice.

The responsibility of the surgeon is to provide the patient's safety first, to perform a functional surgery, and to use the time efficiently. Thus, it may be possible to shift the time gained from antegrade stenting to other critical stages of surgery. So far, we have not encountered an increased risk of complications related to this method. We believe that our findings will support the effectivity of antegrade stenting technique, and will have an additional contribution into the current armamentarium in laparoscopic pyeloplasty surgery.

In conclusion, antegrade JJ stenting during laparoscopic pyeloplasty significantly decreased the total operative time, and it is a safe, feasible, and effective technique with acceptable functional outcomes.

**Table 2. Intraoperative and postoperative data for surgery and catheterization time**

	Group 1 (n=15)	Group 2 (n=19)	p
Total operative time (min) (mean±SD)	128.9±38.9 (118-245)	112.7±21.9 (95-210)	0.04
JJ stenting time (min) (mean±SD)	12.6±5.4	3.5±2.4	0.02
Rate of stenting time to total operative time (%)	0.1	0.03	0.01
Hospital stay (day) (mean±SD)	3.4±2.4	3.1±1.9	0.11
Anastomosis time (min) (mean±SD)	14.2±8.5	12.3±6.7	0.08
Follow-up (months) (mean±SD)	54.7±7	57.1±2	0.11



**Ethics Committee Approval:** Authors declared that the research was conducted according to the principles of the World Medical Association Declaration of Helsinki “Ethical Principles for Medical Research Involving Human Subjects”, (amended in October 2013).

**Informed Consent:** Written informed consent was obtained from participants who participated in this study.

**Peer-review:** Externally peer-reviewed.

**Author Contributions:** Concept – M.S.B., Design – M.S.B., E.A., Ö.Ç.; Supervision – M.S.B., E.A., Ö.Ç.; Resources – M.S.B., E.A.; Materials – M.S.B., E.A., Ö.Ç.; Data Collection and/or Processing – M.S.B., E.A., Ö.Ç.; Analysis and/or Interpretation – M.S.B., E.A., Ö.Ç.; Literature Search – M.S.B., E.A., Ö.Ç.; Writing Manuscript – M.S.B., E.A., Ö.Ç.; Critical Review – M.S.B., E.A., Ö.Ç.; Other – M.S.B., E.A., Ö.Ç.

**Conflict of Interest:** No conflict of interest was declared by the authors.

**Financial Disclosure:** The authors declared that this study has received no financial support.

**Etik Komite Onayı:** Yazarlar çalışmanın World Medical Association Declaration of Helsinki “Ethical Principles for Medical Research Involving Human Subjects”, (amended in October 2013) prensiplerine uygun olarak yapıldığını beyan etmişlerdir.

**Hasta Onamı:** Yazılı hasta onamı bu çalışmaya katılan katılımcılardan alınmıştır.

**Hakem Değerlendirmesi:** Dış bağımsız.

**Yazar Katkıları:** Fikir – M.S.B., Tasarım – M.S.B., E.A., Ö.Ç.; Denetleme – M.S.B., E.A., Ö.Ç.; Kaynaklar – M.S.B., E.A.; Malzemeler – M.S.B., E.A., Ö.Ç.; Veri Toplanması ve/veya İşlemesi – M.S.B., E.A., Ö.Ç.; Analiz ve/veya Yorum – M.S.B., E.A., Ö.Ç.; Literatür Taraması – M.S.B., E.A., Ö.Ç.; Yazıyı Yazan – M.S.B., E.A., Ö.Ç.; Eleştirel İnceleme – M.S.B., E.A., Ö.Ç.; Diğer – M.S.B., E.A., Ö.Ç.

**Çıkar Çatışması:** Yazarlar çıkar çatışması bildirmemişlerdir.

**Finansal Destek:** Yazarlar bu çalışma için finansal destek almadıklarını beyan etmişlerdir.

## References

1. Tripp BM, Homsy YL. Neonatal hydronephrosis-the controversy and the management. *Pediatr Nephrol* 1995;9:503-9. [\[CrossRef\]](#)
2. Schuessler WW, Grune MT, Tecuanhuey LV, Preminger GM. Laparoscopic dismembered pyeloplasty. *J Urol* 1993;150:1795-9. [\[CrossRef\]](#)
3. Braga LHP, Pace K, DeMaria J, Lorenzo AJ. Systematic review and meta-analysis of robotic-assisted versus conventional laparoscopic pyeloplasty for patients with ureteropelvic junction obstruction: effect on operative time, length of hospital stay, post-operative complications, and success rate. *Eur Urol* 2009;56:848-58. [\[CrossRef\]](#)
4. Noh PH, Defoor WR, Reddy PP. Percutaneous antegrade ureteral stent placement during pediatric robot-assisted laparoscopic pyeloplasty. *J Endourol* 2011;25:1847-51. [\[CrossRef\]](#)
5. Mandhani A, Goel S, Bhandari M. Is antegrade stenting superior to retrograde stenting in laparoscopic pyeloplasty? *J Urol* 2004;171:1440-2.
6. Papalia R, Simone G, Leonardo C, Guaglianone S, Forestiere E, Buscarini M, et al. Retrograde placement of ureteral stent and ureteropelvic anastomosis with two running sutures in transperitoneal laparoscopic pyeloplasty: tips of success in our learning curve. *J Endourol* 2009;23:847-52. [\[CrossRef\]](#)
7. Bolat MS, Acikgoz A, Akdeniz E. Transperitoneal laparoscopic treatment of ureteropelvic obstruction: our initial experience: Laparoscopic Pyeloplasty. *Medical Science and Discovery* 2016;3:230-5. [\[CrossRef\]](#)
8. Liss ZJ, Olsen TM, Roelof BA, Steinhardt GF. Duration of urinary leakage after open non-stented dismembered pyeloplasty in pediatric patients. *J Pediatr Urol* 2013;9:613-6. [\[CrossRef\]](#)
9. Olsen LH, Rawashdeh FF. Campbell- Walls Urology. Book Chapter 2016;133:3057-3074.e3.
10. Viprakasit DP, Altamar HO, Miller NL, Herrell SD. Intraoperative retrograde ureteral stent placement and manipulation during laparoscopic pyeloplasty without need for patient repositioning. *J Endourol* 2010;24:1571-4. [\[CrossRef\]](#)
11. Arumainayagam N, Minervini A, Davenport K, Davenport K, Kumar V, Masieri L, et al. Antegrade versus retrograde stenting in laparoscopic pyeloplasty. *J Endourol* 2008;22:671-4. [\[CrossRef\]](#)
12. Soulie M, Salomon L, Patard JJ, Mouly P, Manunta A, Antiphon P, et al. Extraperitoneal laparoscopic pyeloplasty: a multicenter study of 55 procedures. *J Urol* 2001;166:48-50. [\[CrossRef\]](#)
13. Eden CG, Cahill D, Allen D. Laparoscopic dismembered pyeloplasty: 50 consecutive cases. *BJU Int* 2001;88:526-31. [\[CrossRef\]](#)
14. Jarrett TW, Chan, DY, Charambura TC, Fugita O, Kavoussi LR. Laparoscopic pyeloplasty: the first 100 cases. *J Urol* 2002;167:1253-6. [\[CrossRef\]](#)
15. Kalkan S, Ersöz C, Armagan A, Taşçı AI, Silay MS. A Modified Antegrade Stenting Technique for Laparoscopic Pyeloplasty in Infants and Children. *Urol Int* 2016;96:183-7. [\[CrossRef\]](#)
16. Pansota MS, Rasool M, Saleem MS, Tabassum SA, Hussain A. Indications and complications of double J ureteral stenting: Our experience. *Gomal J Med Sci* 2013;11:8-12.
17. Stravodimos K, Katafigiotis I, Fragkiadis E, Tyrantzis S, Constantinides CA. Correcting and sharing our complications. Misplacement of pigtail catheter, during a Robot Assisted Pyeloplasty. Clinical findings, diagnosis, possible causes and endoscopic treatment. *Arch Ital Urol Androl* 2015;87:165-6.
18. Tan HL. Laparoscopic Anderson Hynes dismembered pyeloplasty in children using needlescopic instrumentation. *Urol Clin North Am* 2001;28:43. [\[CrossRef\]](#)
19. Daley BJ, Cecil W, Clarke PC, Cofer JB, Guillaumondegui OD. How slow is too slow? Correlation of operative time to complications: an analysis from the Tennessee Surgical Quality Collaborative. *J Am Coll Surg* 2015;220:550-8. [\[CrossRef\]](#)
20. Mandhani A, Goel S, Bhandari M. Re: Is antegrade stenting superior to retrograde stenting in laparoscopic pyeloplasty? *J Urol* 2004;172:2484-5.
21. Rushton HG, Salem Y, Belman AB, Majd M. Pediatric pyeloplasty: is routine retrograde pyelography necessary? *J Urol* 1994;152:604-6.
22. Cakan M, Yalcinkaya F, Demirel F, Satir A. Is visualising ureter before pyeloplasty necessary in adult patients? *Int Urol Nephrol* 2000;32:33-5.