



Safety and efficacy of silodosin and tadalafil in ease of negotiation of large ureteroscope in the management of ureteral stone: A prospective randomized trial

Üreter taşı tedavisinde geniş çaplı üreteroskopun ilerletilmesini kolaylaştırmada silodosin ve tadalafilin güvenilirlik ve etkinliği: Bir prospektif randomize çalışma

Rohit Bhattar, Vipin Jain, Vinay Tomar, Sher Singh Yadav

Cite this article as: Bhattar R, Jain V, Tomar V, Yadav SS. Safety and efficacy of silodosin and tadalafil in ease of negotiation of large ureteroscope in management of ureteral stone: A prospective randomized trial. Turk J Urol 2017; 43(4): 484-9

ABSTRACT

Objective: To evaluate the safety and efficacy of silodosin and tadalafil in ease of negotiation of large size ureteroscope (8/9.8 Fr) in the management of ureteral stone.

Material and methods: Between June 2015 and May 2016, 86 patients presented with ureteral stone of size 6-15 mm were on consent randomly assigned to 1 of 3 outpatient treatment arms: silodosin (Group A), tadalafil (Group B), and placebo (Group C). After two weeks of therapy 67 patients underwent ureteroscopy, and ureteral orifice configuration, ureteroscopic negotiation, ureteral dilatation, operating time, procedural complication and drug related side effects were noted in each group.

Results: Ureteral negotiation was significantly better in Groups A (73.9%) and B (69.6%) as compared to Group C (38.1%) ($p<0.01$). Statistically significant difference was noted in the requirement for dilatation in Group C (71.4%) as compared to Groups A (26.1%) and B (39.1%) ($p<0.01$). Ureteral orifice was found to be more dilated in Groups A (69.6%) and B (60.9%) as compared to Group C (28.6%). Mean operating time was statistically lower in Groups A (35.2 min) and B (34.91 min) as compared to Group C (41.14 min) ($p<0.01$).

Conclusion: Both silodosin and tadalafil not only relax ureteral smooth muscle but also help in forward propagation of large size ureteroscope (8/9.8 Fr) without any significant risk of adverse events.

Keywords: Silodosin; tadalafil; ureteral stone; ureteroscopy; ureteral orifice.

ÖZ

Amaç: Üreter taşlarının tedavisinde kullanılan geniş kalibreli (8/9.8) üreteroskopun ilerletilmesini kolaylaştırmada silodosin ve tadalafilin güvenilirlik ve etkinliğini değerlendirmek.

Gereç ve yöntemler: Haziran 2015 ile Mayıs 2016 arasında 6-15 mm'lik üreter taşlarıyla gelen 86 hasta onay alınarak 3 ayaktan tedavi kolundan (Grup A, silodosin; Grup B, tadalafil ve Grup C, plasebo) birine randomize edildi. İki haftalık tedavi sonrası 67 hastaya üreteroskopisi uygulandı ve her bir grupta üreter orifisinin konfigürasyonu, üreteroskopun manipülasyonu, üreter dilatasyonu, ameliyat süresi, işlemin komplikasyonu ve ilaca bağlı yan etkiler kaydedildi.

Bulgular: Üreteroskopik girişim, Grup A (%79,3) ve Grup B (%69,6) hastalarda, Grup C (%38,1) hastalara göre daha kolay uygulanmıştır ($p<0,01$). Grup A (%26,1) ve B (%39,1) ile karşılaştırıldığında Grup C'de (%71,4) istatistiksel açıdan anlamlı derecede daha fazla hastada dilatasyona gerek duyulmuştur ($p<0,01$). Grup C (%28,6) ile karşılaştırıldığında Grup A (%69,6) ve B (%60,9) hastalarında üreter orifislerinin daha geniş olduğu saptanmıştır. C (41,4 dk) Grubuyla karşılaştırıldığında ortalama ameliyat süresi A (35,2 dk) ve B (34,91 dk) grubunda istatistiksel açıdan anlamlı derece daha kısa bulunmuştur ($p<0,01$).

Sonuç: Hem silodosin hem de tadalafil yalnızca üreter düz kaslarını gevşetmekle kalmaz aynı zamanda geniş çaplı üreteroskopun (8/9,8 Fr) önemli yan etki riski olmaksızın ileriye doğru ilerletilmesine yardımcı olmaktadır.

Anahtar Kelimeler: Silodosin; tadalafil; üreter taşı; üreteroskop; üreter orifisi.

Department of Urology, Sawai Man Singh Medical College, Jaipur, Rajasthan, India

Submitted:
19.05.2017

Accepted:
07.08.2017

Correspondence:
Rohit Bhattar
E-mail:
bhattarrohit@gmail.com

©Copyright 2017 by Turkish Association of Urology

Available online at
www.turkishjournalofurology.com

Introduction

The use of rigid retrograde ureterorenoscopy was first published by Drs. Perez Castro and Martinez Pineiro in 1980.^[1] Later on miniaturization of ureteroscope have optimized therapeutic and diagnostic procedures with minimal morbidity but simultaneously compromised the visibility.^[2] For successful ureteroscopy, negotiating ureteral orifice is an important part and almost 40-60% of patients require dilatation of ureteral orifice for negotiation by large size ureteroscope (8/9.8 Fr).^[3] Various techniques have been used to overcome difficult ureteroscopic negotiation but none is exempt from complication. Ureter is lined by adrenergic and phosphodiesterase receptors that are responsible for contraction of detrusor and ureteral smooth muscle. Blocking of these receptors leads to ureteral smooth muscle relaxation, causing antegrade stone propagation and expulsion.

In the literature no study has been done till date to dilate ureteral orifice with medication for ease of negotiation of larger size ureteroscope to improve stone access. Keeping this in mind we planned to carry out a study to evaluate the role of silodosin and tadalafil in ease of negotiation of large size ureteroscope. The aim of this study was to assess safety and efficacy of silodosin and tadalafil in dilatation of ureteral orifice, ease of ureteroscopic negotiation, operating time, procedural complications and drug related side effects.

Material and methods

After taking ethical approval (IRB approval no: 1693/MC/EC/2015), this prospective study was conducted in our department of urology from June 2015 to May 2016. A total of 86 patients aged 18-70 years with an uncomplicated, single ureteral calculus, size 6-15 mm, located in either lower, mid or upper ureter (up to level L-5) were included in this study. Eleven patients either not willing to participate or not following inclusion criteria were excluded from the study. Patients were randomly allocated to three groups and given either alpha blocker (silodosin), a phosphodiesterase 5 inhibitor (PDE5i) (tadalafil) or placebo (multivitamin) prior to surgery. Patients with fever, infection, moderate to gross hydronephrosis, acute or chronic renal insufficiency, multiple or bilateral ureteral stones, solitary kidney or congenital urinary abnormality were excluded. Patient having history of open surgery or endoscopic interventions, diabetes, peptic ulcer or on concomitant treatment with alpha-, beta-blockers, steroids, calcium antagonists or nitrates, pregnant or lactating mothers and patients who demand immediate intervention and passed stone spontaneously were also excluded from this study.

After taking informed written consent, all patients satisfying inclusion criteria were randomly assigned into three groups (25

subjects in each group) by means of sealed envelopes equally nominating one of the three treatment alternatives (silodosin, tadalafil or placebo). Allocation concealment was done using the SNOSE method (sequentially-numbered, opaque, sealed envelopes).

All patients underwent physical examinations, weight, height, body mass index (BMI), serum creatinine measurements, urinalysis, urine culture, ultrasonography, plain X-ray of the kidneys, ureters, and bladder (KUB), IVP or computed tomography (CT). The greatest dimension of the stone was taken into consideration as the stone size. Patients' demographic characteristics in all three groups were documented.

Patients in Groups A, B and C were given silodosin (8 mg once daily), tadalafil (10 mg once daily) and multivitamin as a placebo (once daily) for two weeks. All patients were given oral diclofenac as needed for pain relief. After 2 weeks, patients of all three groups underwent surgical interventions. First of all, cystoscopy was done and configuration of ureteral orifice was documented then 0.035 Fr guide wire was inserted. After that (Richard Wolf GmbH, Germany) we tried to insert 8/9.8 Fr Wolf ureteroscope into ureteral orifice over guide wire. If ureteroscope was negotiated easily into ureteral orifice without using any maneuver then procedure was considered as complete. If ureteroscope could not be negotiated through ureteral orifice easily than dilatation was done up to 10 Fr with Nottingham ureteral dilator over guide- wire and subsequently ureteroscope was passed and stone removal was achieved. At the end of the procedure double-J stent was placed in all patients (as a routine practice in our institution). Both cystoscopy and ureteroscopy were performed by single senior urologist who was blind to the treatment group (drug allocated) of each patient. Ureteral orifice configuration, difficult or easy negotiation, need or no need for ureteral orifice dilatation, operating time, procedural complications and side effects of the drugs were noted in each group.

Statistical analysis

Statistical analysis of data was performed using IBM Statistical Package for the Social Sciences (IBM SPSS Statistics; Armonk, NY, USA) version 21.0. Normally distributed data were compared in all three groups by ANOVA test and all classified and categorical data were analyzed using *chi-square* test. Level of significance was accepted as $p < 0.05$.

Results

A total of 75 patients met inclusion criteria which were randomly assigned into three groups (Figure 1). There was a dropout of two patients in Groups A and B and of four patients in Group C. Reasons for dropout were unknown because patients did not return for follow up.

Table 1. Demographic characteristics of the groups

Parameters	Group A silodosin n=23	Group B tadalafil n=23	Group C placebo n=21	p
Mean age±SD (years)	35.52±11.0	42.78±14.0	33.22±10.7	0.08 ^x
Male/Female (n)	15/8	18/5	15/6	0.909 ^y
BMI (kg/m ²)	23.34	23.98	34.1	0.377 ^x
Laterality (right/left)	12/11	13/10	7/14	0.345 ^y
Location (upper/middle/lower)	5/4/14	4/3/16	6/3/12	0.762 ^y
Mean stone size±SD (mm)	9.14±1.52	9.42±1.29	9.74±1.98	0.470 ^x

^xANOVA (Analysis of variance) test, ^yChi-square test. BMI: body mass index; SD: standard deviation

Table 1 shows the preoperative characteristics of all the groups. Statistically insignificant differences were observed regarding patients' age, gender, BMI, stone sizes, and locations.

Table 2 shows that ureteral orifices were found to be dilated in 69.6%, 60.9%, and 28.6% of the patients in Groups A, B, and C, respectively. Significant number of patients in Groups A and B had dilated ureteral orifices as compared to the patients in Group C. ($p=0.01$ and 0.04 , respectively) whereas difference in widening of ureteral orifice was insignificant in Groups A and B ($p=0.54$).

Ureteroscopic negotiation was easy in 73.9%, 69.6% and 38.1% of the patients in silodosin, tadalafil and placebo groups, respectively. Statistically significant number of patients in Groups A and B ureteral orifice was negotiated easily as compared to Group C ($p=0.01$ and 0.03 , respectively).

Ureteral dilatation was required in 26.1%, 39.1%, and 71.4% of the patients in Groups A, B and C, respectively. Difference in requirement of ureteral dilatation among patients was significant in Group C as compared to Groups A and B ($p=0.005$ and 0.01 , respectively) whereas it was insignificant among patients in Groups A and B ($p=0.74$).

Mean operating times were 35.2 min, 34.91 min, and 41.14 min in Groups A, B and C, respectively. Patients in Groups A and B required significantly less operating time as compared to those in Group C ($p=0.029$ and 0.022 , respectively) however difference in mean operating time was not significant between Group A and B ($p=0.908$).

Procedure-related injuries like hematuria and mucosal injury were more common in Group C as compared to Group A. Hematuria and mucosal injury were found in 52.38% and 38.09% of the patients in Group C as compared to 17.4% and 13.0% of the patients in Group A ($p=0.04$ and 0.035 , respectively). Whereas differences in the rates of hematuria and mucosal injury in Groups A and B and Group B and C were statistically insignificant ($p>0.05$) (Table 3).

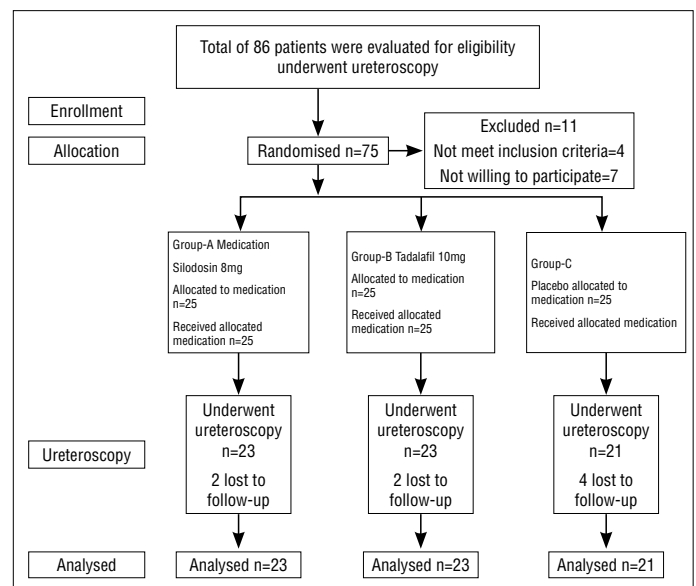


Figure 1. Study design of silodosin and tadalafil in ease of negotiation of large ureteroscope in the management of ureteral stone

Drug-related side effects like headache, backache and dyspepsia were seen at a significantly higher rate in Group B as compared to Groups A and C ($p<0.05$). Whereas dizziness and abnormal ejaculation was more common in Group A as compared to Groups B and C which was not statistically significant ($p>0.05$).

Discussion

Ureterovesical junction is the narrowest part of the ureter, thus for successful ureteroscopic negotiation through this part is one of the problems that urologist faces during ureteroscopy. Small size ureteroscope permits easy negotiation and approach to upper ureter but with poor visibility and efficacy for stone removal and larger size ureteroscope requires dilatation.^[4,5] Various techniques have been employed for dilatation like passive dilatation (using double j stent) or active dilatation (using balloon, sequential fas-

Table 2. Treatment outcome parameters of the groups

Outcome parameter		Group A silodosin n=23	Group B tadalafil n=23	Group C placebo n=21	p		
					A vs. B	A vs. C	B vs. C
Configuration of ureteral orifice	Wide	16/23 (69.6%)	14/23 (60.9%)	6/21 (28.6%)	0.5358	0.0113	0.0408 ^{yz}
	Narrow	7/23 (30.4%)	9/23 (39.1%)	15/21 (71.4%)			
Ureteroscopic negotiation (8/9.8fr)	Difficult	6/23 (26.1%)	7/23 (30.4%)	13/21 (61.9%)	0.7433	0.0113	0.0256 ^{yz}
	Easy	17/23 (73.9%)	16/23 (69.6%)	8/21 (38.1%)			
Ureteral dilatation	Required	6/23 (26.1%)	9/23 (39.1%)	15/21 (71.4%)	0.7433	0.0047	0.0113 ^{yz}
	Not required	17/23 (73.9%)	14/23 (60.9%)	6/21 (28.6%)			
Mean operative time (min)		35.22 (24.42-46.00)	34.91 (25.21-44.61)	41.14 (36.44-45.84)	0.908	0.029	0.022 ^{xz}

^xANOVA (Analysis of variance) test, ^yChi-square test, ^zpost-hoc test

Table 3. Procedural complication rates of the groups

Outcome parameter	Group A silodosin n=23	Group B tadalafil n=23	Group C placebo n=21	p ^x
Hematuria	4/23 (17.4%)	6/23 (26.1%)	11/21 (52.38%)	0.04
Mucosal injury	3/23 (13%)	4/23 (17.4%)	8/21 (38.09%)	0.21
Fever	4/23 (17.4%)	3/23 (13%)	6/21 (28.57%)	0.61

^xChi-square test.

cial dilator, meatal olives, etc) with the purpose of overcoming difficult negotiation but these are also not exempted from complications.^{16,71} Some drugs have been also tried for easy negotiation of ureteral orifice and to decrease complications associated with ureteroscopy.^{18,91} Lodh et al.¹⁹¹ showed that deflazacort is an effective drug for this purpose if given at a dose of 30 mg once a day for 10 days prior to procedure due to its potent anti-inflammatory action.¹⁸¹ Akin et al.¹⁸¹ used thiocholchicoside in the irrigant solution and showed that locally administered thiocholchicoside had aided in decreasing the stone migration rate during surgery and hence decreased operating time.

The ureter is lined by α-1 adrenergic receptors, particularly the subtype α-1A and α-1D, which are more populated in distal third ureter and ureterovesical junction as compared to proximal and middle ureter. Tatemichi et al.¹¹⁰¹ reported that in hamster ureter, ureteral contraction was mediated mainly by α-1A adrenoreceptor even though α-1D receptor are more prevalent so we used silodosin which is highly selective α-1A adrenoreceptor antagonist and has 56 fold affinity for α-1A over α-1D adrenoreceptor.^{111,121}

Gratzke et al.¹¹³¹ demonstrated the effectiveness of PDE 5 inhibitors vardenafil, sildenafil, and tadalafil in relaxation of ureteral smooth muscle in order of decreasing potency.^{114,151} As tadalafil is more selective PDE-5i receptor as compared to sildenafil, visual problems are less likely. To minimize adverse effects we use tadalafil at a lower dose.

As shown in various studies both silodosin and tadalafil cause ureteral relaxation and facilitate stone propagation and expulsion. Similar effects have been observed in our study in Groups A and B. Ureteral orifice were found to be dilated in 16 (69.6%) and 14 (60.9%) patients in Groups A and B, respectively. However ureteroscopic negotiation was easy in 17 (73.9%) and 16 (69.6%) patients in Groups A and B respectively. Whereas in Group C ureteral orifice was found to be dilated in only 6 (28.6%) patients and ureteroscopy was negotiated easily in 8 (38.1%) patients.

Elashry et al.¹¹⁶¹ used ureteroscopes of various calibres (9.5fr-11.5fr) in the management of ureteral stone. Dilation of the ureteral orifice and intramural ureter was performed in 59.5% of the cases, ureteral access sheaths were used in 15.6% of the patients, and any ureteral dilation was not required for patients who had previously undergone stenting. About 3.7% of the patients in their study had undergone secondary ureteroscopy due to intraoperative complications. Direct introduction of ureteroscopy into ureter without dilatation had been performed in 9% of the patients either using small size semi-rigid ureteroscopy or stenting ureter preoperatively.

Convincing evidence for the safety of orifice dilation was reported by Garvin and Clayman¹¹⁷¹, who reported no clinical significant long-term sequelae related to routine 24 F ureteral orifice dilation. The incidence of strictures is decreased by routine placement of postoperative double pigtail ureteral stents.

However in our study we used 8/9.8 Fr Wolf ureteroscope, so 15 (71.4%) patients required dilatation of ureteral orifice and intramural ureter in Group C as compared to 6 (26.1%) and 9 (39.1%) patients in Groups A and B, respectively.

Difference in mean operating time between patients with and without dilatation was not recorded in previous studies. However in our study mean operating time was 41.14 min in Group C which was significantly higher than that in Groups A (35.22 min) and B (34.91 min). Reason of Increased operating time was associated with the need for ureteral dilatation in significant number of patients in Group C relative to Groups A and B.

Previous studies by Kramolowsky et al.^[18], and Lytton et al.^[19] reported high chance of mucosal injury, perforation, hematuria and ureteral avulsion when patients were treated with sequential ureteral dilatation or using large- sized ureteroscopes without prior dilation. Stoller et al.^[20] also encountered complications in 19% of attempts at stone extractions with 10.5 to 12.5 F ureteroscopes. Similarly in our study incidence of mucosal injury and hematuria was higher in Group C in whom significant number of patients underwent ureteral dilatation as compared to patients in Groups A and B.

In a study by Kumar et al.^[21] the incidence of drug- related side effects like headache, dizziness, backache and orthostatic hypotension was significantly higher in the tadalafil group. Abnormal ejaculation was seen in 15.6%, and 5.9% of the patients in the silodosin, and tadalafil groups, respectively, without any statistically significant difference. In our study drug-related adverse effects like headache and backache were seen significantly more frequent in the tadalafil group as compared to silodosin and placebo groups. Since these patients were able to tolerate side effects, they were not excluded from the study. Incidence of dizziness, abnormal ejaculation and orthostatic hypotension was also not significant in Groups A, B and C.

Our study is also not free from limitation. Apart from being a single-center study and small sample size, we had no idea about the normal anatomic (original) configuration of the orifice in advance (before drug treatment) and assessment was completely subjective which can also be a major bias.

In conclusion, from our study we conclude that both silodosin and tadalafil not only relax ureteral smooth muscle but also aids in forward propagation of large size ureteroscope (8/9.8 Fr) without any significant risk of mucosal injury, hematuria and ureteral perforation with shorter operative time. However drug-related side effects like headache and backache were more significant in tadalafil group as compared to silodosin group hence we found that silodosin is better than tadalafil in our study however further studies would be required to reach at a conclusion.

Ethics Committee Approval: Ethics committee approval was received for this study from the ethics committee of Sawai Man Singh Medical College (1693/MC/EC/2015).

Informed Consent: Written informed consent was obtained from patients who participated in this study.

Peer-review: Externally peer-reviewed.

Author Contributions: Concept – R.B., V.J., V.T.; Design – R.B., V.J., V.T.; Supervision – V.T., S.S.Y.; Resources – V.T.S.S.Y.; Materials – R.B., V.J., S.S.Y.; Data Collection and/or Processing – R.B., V.J.; Analysis and/or Interpretation – R.B., V.J.; Literature Search – R.B., V.J.; Writing Manuscript – R.B., V.J.; Critical Review – V.T., S.S.Y.

Conflict of Interest: No conflict of interest was declared by the authors.

Financial Disclosure: The authors declared that this study has received no financial support.

Etik Komite Onayı: Bu çalışma için etik komite onayı Sawai Man Singh Tıp Koleji'nden (1693/MC/EC/2015) alınmıştır.

Hasta Onamı: Yazılı hasta onamı bu çalışmaya katılan hastalardan alınmıştır.

Hakem Değerlendirmesi: Dış bağımsız.

Yazar Katkıları: Fikir – R.B., V.J., V.T.; Tasarım – R.B., V.J., V.T.; Denetleme – V.T., S.S.Y.; Kaynaklar – V.T.S.S.Y.; Malzemeler – R.B., V.J., S.S.Y.; Veri Toplanması ve/veya İşlemesi – R.B., V.J.; Analiz ve/veya Yorum – R.B., V.J.; Literatür Taraması – R.B., V.J.; Yazıyı Yazan – R.B., V.J.; Eleştirel İnceleme – V.T., S.S.Y.

Çıkar Çatışması: Yazarlar çıkar çatışması bildirmemişlerdir.

Finansal Destek: Yazarlar bu çalışma için finansal destek almadıklarını beyan etmişlerdir.

References

1. Perez Castro E, Martinez Pineiroja A. La uretero rrenoscopia transuretral. Un actual proceder urologico. Arch Esp Urol 1980;23:445-60.
2. Harmon WJ, Sershon PD, Blute ML. Ureteroscopy: current practice and long-term complications. J Urol 1997;157:28-32. [\[CrossRef\]](#)
3. Auge BK, Preminger GM. Ureteral stents and their use in endourology. Curr Opin Urol 2002;12:217-22. [\[CrossRef\]](#)
4. Hubert KC, Palmer JS. Passive dilation by ureteral stenting before ureteroscopy: eliminating the need for active dilation. J Urol 2005;174:1079-80. [\[CrossRef\]](#)
5. Hosking DH, McColm SE, Smith WE. Is stenting following ureteroscopy for removal of distal ureteral calculi necessary? J Urol 1999;161:48-50.
6. El-Hakim A, Tan BJ, Smith AD. Ureteroscopy: technical aspects. Urinary stone disease: the practical guide to medical and surgical management. Humana, Totowa, New Jersey, 2007;589-607.

7. Joshi HB, Newns N, Stainthorpe A. Ureteral stent symptom questionnaire: development and validation of a multidimensional quality of life measure. *J Urol* 2003;169:1060-4. [\[CrossRef\]](#)
8. Akin Y, Gulmez H, Ates M, Ates E, Baykara M. Impact of using thiocolchicoside during endoscopic ureteral calculi removal: a preliminary study. *Minim Invasive Ther Allied Technol* 2016;25:29-34. [\[CrossRef\]](#)
9. Lodh B, Singh KA, Sinam RS. Role of steroidal anti-inflammatory agent prior to intracorporeal lithotripsy under local anesthesia for ureterovesical junction calculus: A prospective randomized controlled study. *Urology Annals* 2015;7:188-92. [\[CrossRef\]](#)
10. Tatemichi S, Tomiyama Y, Maruyama I. Uroselectivity in male dogs of silodosin (KMD-3213), a novel drug for the obstructive component of benign prostatic hyperplasia. *Neurourol Urodyn* 2006;25:792-801. [\[CrossRef\]](#)
11. Dellabella M, Milanese G, Muzzonigro G. Randomized trial of the efficacy of tamsulosin, nifedipine and phloroglucinol in medical expulsive therapy for distal ureteral calculi. *J Urol* 2005;174:167-72. [\[CrossRef\]](#)
12. Tsuzaka Y, Matsushima H, Kaneko T, Yamaguchi T, Homma Y. Naftopidil vs silodosin in medical expulsive therapy for ureteral stones: a randomized controlled study in Japanese male patients. *Int J Urol* 2012;19:792-5. [\[CrossRef\]](#)
13. Gratzke C, Uckert S, Reich O, Schlenker B, Tilki D, Seitz M, et al. PDE5 inhibitors. A new option in the treatment of ureteral colic? *Urologe A* 2007;46:1219-23.
14. Gratzke C, Uckert S, Kedia G, Reich O, Schlenker B, Seitz M, et al. In vitro effects of PDE5 inhibitors sildenafil, vardenafil and tadalafil on isolated human ureteral smooth muscle: a basic research approach. *Urol Res* 2007;35:49-54. [\[CrossRef\]](#)
15. Taher A, Schul-Knappe P, Meyer M. Characterization of cyclic nucleotide phosphodiesterase isoenzymes in the human ureter and their functional role in vitro. *World J Urol* 1994;12:286-91. [\[CrossRef\]](#)
16. Elashry OM, Elgamasy AM, Sabba MA, Abo-Elenien M, Omar MA, Eltatawy HH, et al. Ureteroscopic management of lower ureteric calculi. *BJU Int* 2008;102:1010-7. [\[CrossRef\]](#)
17. Garvin TJ, Clayman RV. Balloon dilation of the distal ureter to 24F: an effective method for ureteroscopic stone retrieval. *J Urol* 1991;146:742-5. [\[CrossRef\]](#)
18. Kramolowsky EV. Ureteral perforation during ureteroscopy: treatment and management. *J Urol* 1987;138:36-8. [\[CrossRef\]](#)
19. Lytton B, Weiss RM, Green DF. Complications of ureteral endoscopy. *J Urol* 1987;137:649-53. [\[CrossRef\]](#)
20. Stoller ML, Wolf JS Jr. Endoscopic ureteral injuries. in: McAninch JW (Ed.) *Traumatic and reconstructive urology*. W.B. Saunders, Philadelphia; 1996:199-211.
21. Kumar S, Jayant K, Agrawal MM, Singh SK, Agrawal S, Parmar KM. Role of tamsulosin, tadalafil, and silodosin as the medical expulsive therapy in lower ureteric stone: a randomized trial (a pilot study). *Urology* 2015;85:59-63. [\[CrossRef\]](#)