



# New surgical technique applied with urological instruments in bilobar multiple hepatolithiasis: Ultra-mini percutaneous hepatolithotomy

## *Bilober multiple hepatolitiaziste ürolojik enstrümanlarla uygulanan yeni cerrahi teknik: Ultra-mini perkütan hepatolitotomi*

Ahmet Öztürk<sup>1</sup>, Mehmet Giray Sönmez<sup>1</sup>, Süleyman Bakdık<sup>2</sup>, Yunus Emre Göger<sup>1</sup>, Mehmet Serkan Özkent<sup>1</sup>, Faruk Aksoy<sup>3</sup>, Metin Belviranlı<sup>3</sup>

**Cite this article as:** Öztürk A, Sönmez MG, Bakdık S, Göger YE, Özkent MS, Aksoy F, et al. New surgical technique applied with urological instruments in bilobar multiple hepatolithiasis: Ultra-mini percutaneous hepatolithotomy. Turk J Urol 2017; 43: 371-7

### ABSTRACT

Intrahepatic bile duct stones may emerge with manifestations as chronic stomach ache, cholestasis, cholangitis, abscess, post-obstructive atrophy and liver cirrhosis presentation may occur. Thus the treatment of symptomatic hepatolithiasis patients should be provided. Different methods such as biliary decompression, endoscopic, percutaneous or open surgery are recommended for the treatment of patients with intrahepatic gallstones. The aim of the treatment is to extract the stones and regain biliary drainage. But the treatment regimen to be applied should be determined after examining the age, performance condition, general condition of the patient and location of the stone carefully. In this case, we presented a young female patient who had many unsuccessful surgical interventions due to choledochal cyst and congenital malformation in bile ducts, had large stones in right and left intrahepatic bile ducts and in whom we provided complete stone-free condition through Ultra-Mini Percutaneous Hepatolithotomy (UM-PHL) using urological instruments.

**Keywords:** Hepatolithiasis; intrabiliary stone extraction; percutaneous nephrolithotomy; ultra-mini percutaneous hepatolithotomy.

### ÖZ

İntrahepatik safra kanalı taşları, kronik karın ağrısı, kolestaz, kolanjit, apse, postobstrüktif atrofi ve karaciğer sirozu tablosu oluşturabilir. Bu nedenle semptomatik olan hepatolitiyazisli hastaların tedavisi sağlanmalıdır. Tedavide intrahepatik safra taşları olan hastalar için biliyer dekompresyon, endoskopik, perkütan veya açık cerrahi gibi farklı yöntemler önerilmektedir. Tedavinin amacı, taşların temizlenmesi ve safra drenajını geri kazandırmaktır. Fakat uygulanacak tedavi rejimi hastanın yaş, performans durumu, genel durumu ve taş yeri dikkatlice incelendikten sonra kararlaştırılmalıdır. Bu olguda, doğuştan safra kanallarında malformasyon ve koledok kisti nedeniyle birçok kez başarısız cerrahi girişim geçiren, sağ ve sol intrahepatik safra kanallarında büyük boyutta taşları olan ve ürolojik enstrümanlarla yaptığımız Ultra-Mini Perkütan Hepatolitotomi (UM-PHL) ile tam taşsızlık sağladığımız genç bayan hastamızı sunduk.

**Anahtar Kelimeler:** Hepatolitiyazis; intrabilyer taş çıkartılması; perkütan nefrolitotomi; ultra-mini perkütan hepatolitotomi.

### Introduction

Hepatolithiasis is the presence of gall stones in the bile ducts proximal to the confluence of the right and left hepatic ducts regardless of the presence of stones in common bile duct (CBD) and/or gall bladder. Its prevalence is 30-50% in East Asian and 0.6-1.3% in the Western countries.<sup>[1]</sup>

Intrahepatic biliary stones may present with chronic stomach ache, cholestasis, cholangitis, abscess, post-obstructive atrophy and liver cirrhosis. Thus different methods such as biliary decompression, endoscopic, percutaneous or open surgery are used for the treatment of patients with intrahepatic biliary stones. The aim of the treatment is to extract the stones and regain biliary drainage. Liver resection was

<sup>1</sup>Department of Urology, Necmettin Erbakan University Meram School of Medicine, Konya, Turkey

<sup>2</sup>Department of Radiology, Necmettin Erbakan University Meram School of Medicine, Konya, Turkey

<sup>3</sup>Department of General Surgery, Necmettin Erbakan University Meram School of Medicine, Konya, Turkey

**Submitted:**  
30.05.2017

**Accepted:**  
16.06.2017

**Correspondence:**  
Mehmet Giray Sönmez  
E-mail:  
drgiraysonmez@gmail.com

©Copyright 2017 by Turkish Association of Urology

Available online at  
www.turkishjournalofurology.com

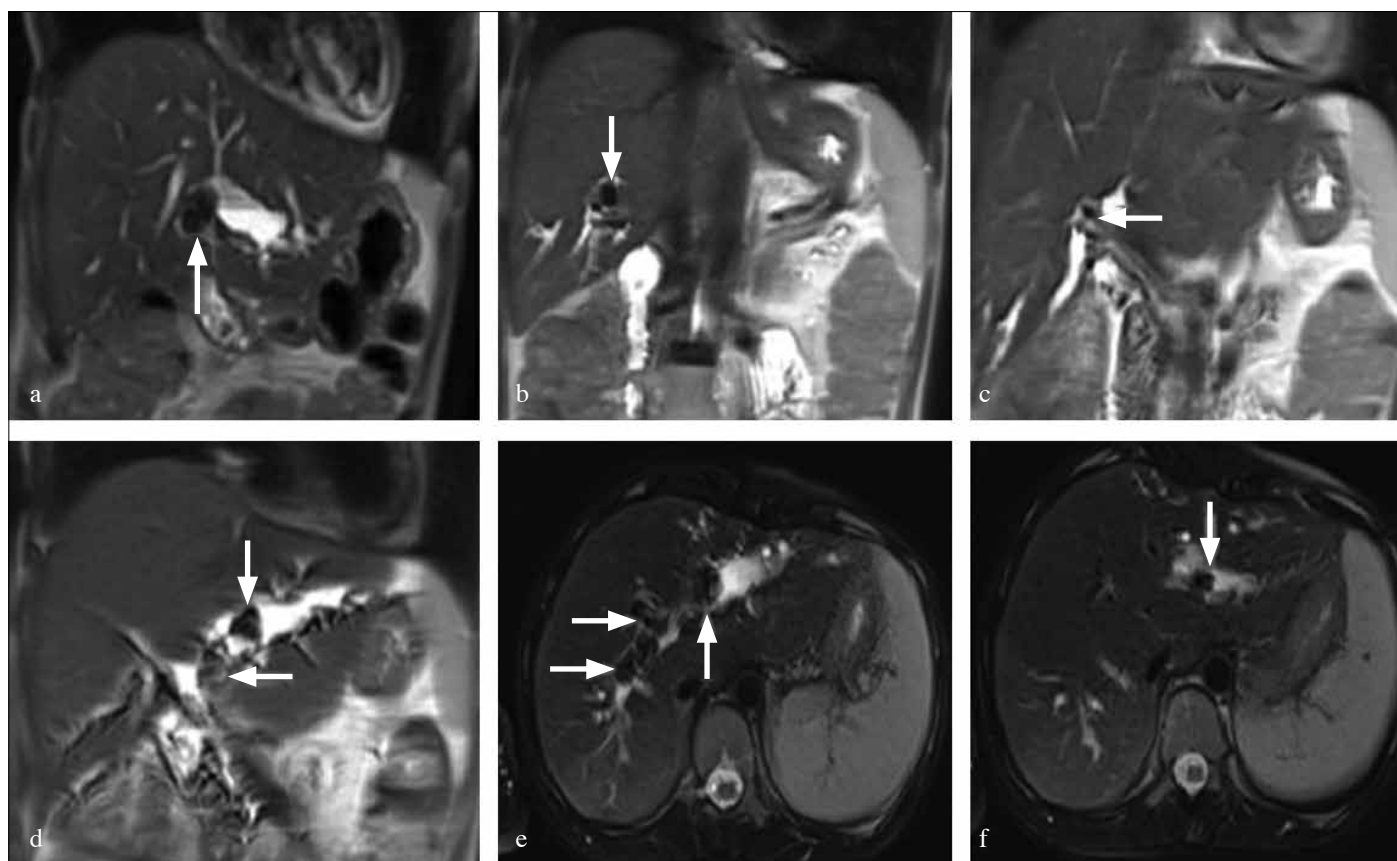


Figure 1. a-f. MRI images of multiple hepatolithiasis; (a-d): Image of MRI: coronal plane, (e,f): Image of MRI: axial plane

applied as the first treatment option for these stones in the past but new treatment modalities have been investigated in order to extract intrahepatic stones due to the high morbidity and mortality rates in open surgery managements.

So less invasive percutaneous transhepatic cholangioscopy (PTHCS), Peroral cholangioscopy (POCS), Extracorporeal shock wave lithotripsy (ESWL) were used for the treatment of these stones. But these treatments couldn't meet the expectation in especially hepatolithiasis patients with a high stone burden since they don't significantly reduce the intrahepatic stone burden and the anatomy of the bile ducts differ.<sup>[2,3]</sup>

Percutaneous nephrolithotomy (PNL) is a minimal invasive method preferred in large and multiple kidney stones. This method has been successfully applied by urologists in many centers with very high stone-free rates.<sup>[4]</sup> Ultra-mini percutaneous nephrolithotomy performed using minimal invasive tools has been applied with success thanks to accumulated PNL experience and the technological developments.<sup>[5]</sup> So with the experience gained in PNL, ultra-mini percutaneous hepatolithotomy can be used for the treatment in hepatolithiasis cases with high morbidity.

Despite different percutaneous treatments applied for the hepatolithiasis patients in the literature, Ultra-Mini Percutaneous Hepatolithotomy (UM-PHL) has not been applied in any hepatolithiasis patient before. UM-PHL was used in this case for the first time and this name was given to this procedure because of small tools used for the extraction of the stones.

In this case, we presented a young female patient who had many unsuccessful surgical interventions due to choledochal cyst and congenital malformation in bile ducts, had large stones in right and left intrahepatic bile ducts and in whom we provided complete stone-free condition through Ultra-Mini Percutaneous Hepatolithotomy (UM-PHL) using urological instruments.

### Case presentation

Twenty- three year old female patient had portoenterostomy (Kasai) and cholecystectomy operation when she was two months old due to choledochal cyst and then treatments such as balloon dilatation, basket lithotripsy and pushing the stones towards the jejunum (PTCHS) were applied three times concurrently with the aid of percutaneous transhepatic cholangiography (PTCH) performed by interventional radiologists and

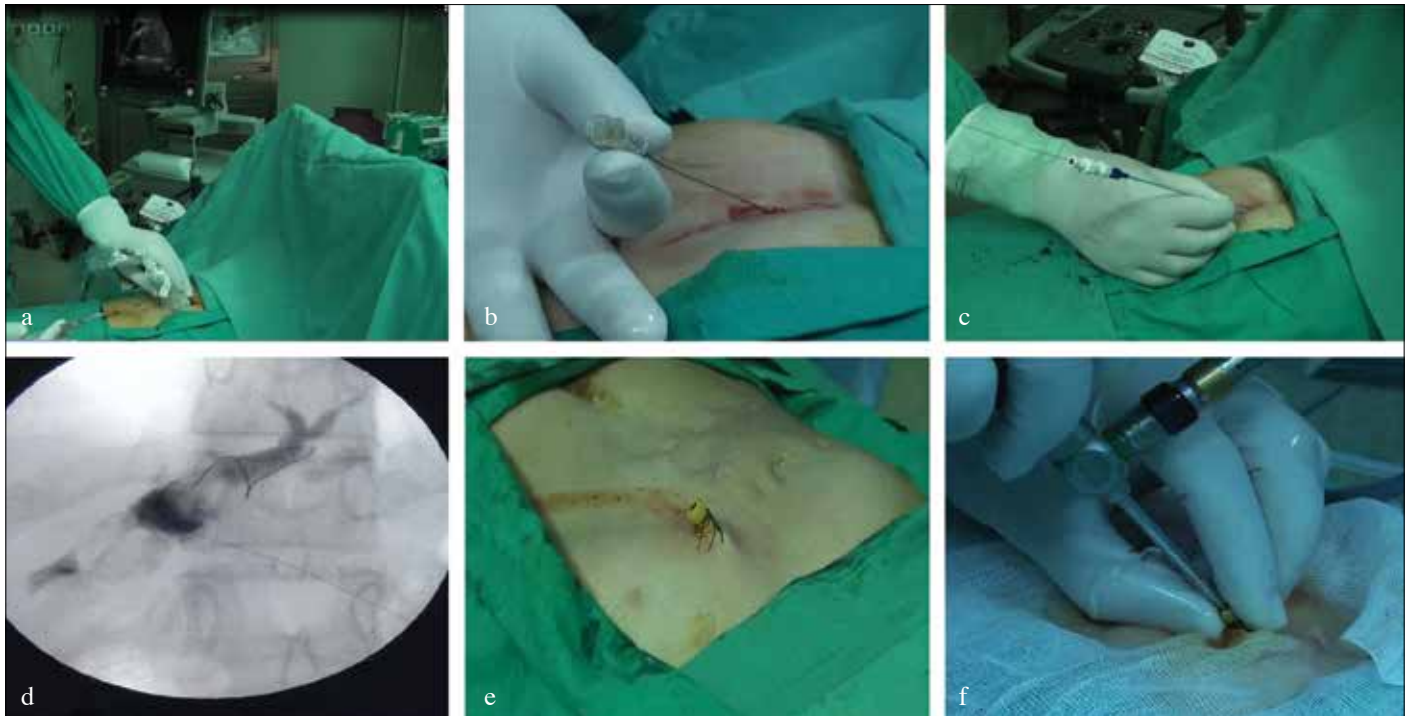


Figure 2. a-f. Providing access to intrahepatic bile ducts; (a-b): ultrasound-guided percutaneous injection of intrahepatic bile ducts, (c- d): inserting guidewire and locating dilator (e): vascular introducer sheath and making them ready for intervention (f): inserting the pediatric cystoscope into the sheath

gastroenterologists for the management of the stones in the intrahepatic bile ducts of the patient who had recurrent cholangitis and pancreatitis attacks but the treatments failed due to heavy stone load. Open resection of the choledochal cyst and Wirsung jejunostomy (Puestow) operations were made a year ago due to the continuing complaints of the patient.

In the abdominal magnetic resonance imaging (MRI) and magnetic resonance cholangiopancreatography (MRCP) of the patient who had persistent gastrointestinal complaints (dyspepsia, pain, and nausea) despite surgeries performed, multiple (more than 10) bile duct stones were observed in the bilateral intrahepatic bile ducts, and the largest of these stones was 22 mm in diameter (Figure 1). According to Dong's classification Type 2b (diffuse stone disease with segmental atrophy and/or stricture) hepatolithiasis was detected.

Some results of biochemical analyses made during hospitalization were as follows: ALT: 75 u/L AST: 64 u/L GGT: 45 u/L ALP: 168 u/L direct bilirubin: 0.24 mg/dL, indirect bilirubin: 0.29 mg/dL, WBC: 7730  $10^3/uL$ , Hb: 10.3 g/dL.

Since there was a risk of development of liver failure after open liver resection, and stone-free state couldn't be provided for the patient with heavy stone burden using PTCHS, "Ultra-

Mini Percutaneous Hepatolithotomy" procedure was planned to be performed in urology surgery room by Necmettin Erbakan University Stone diseases Diagnosis and Treatment Center upon the decision of the team consisting of urology, interventional radiology and general surgery clinics as it could provide less morbidity and a higher ratio of stone-free state.

#### Surgical Technique and follow-up of the patient

Intrahepatic bile duct was entered percutaneously with 18 Gauge needle with the aid of ultrasonography (USG) by interventional radiologist with the patient in the supine position and under general anesthesia. Bile secretion was observed inside the injector cylinder, and bile ducts were monitored with fluoroscopy after injection of opaque material (Iohexol, Kopaq 300, Kocsel, İstanbul, Turkey). Then a 0.035 inch soft-edged hydrophilic guidewire was inserted and a 10 F vascular introducer sheath (Terumo Medical Corporation, Elkton, USA) was advanced over the guidewire. The end of this sheath which is outside the skin was used as access sheath by cutting the end to allow entrance of instruments (Figure 2).

Then intrahepatic bile duct was entered with 9.5F pediatric rigid cystoscope (Karl-Storz, Tuttlingen, Germany) by the urologist through the vascular sheath. More than two small stones of

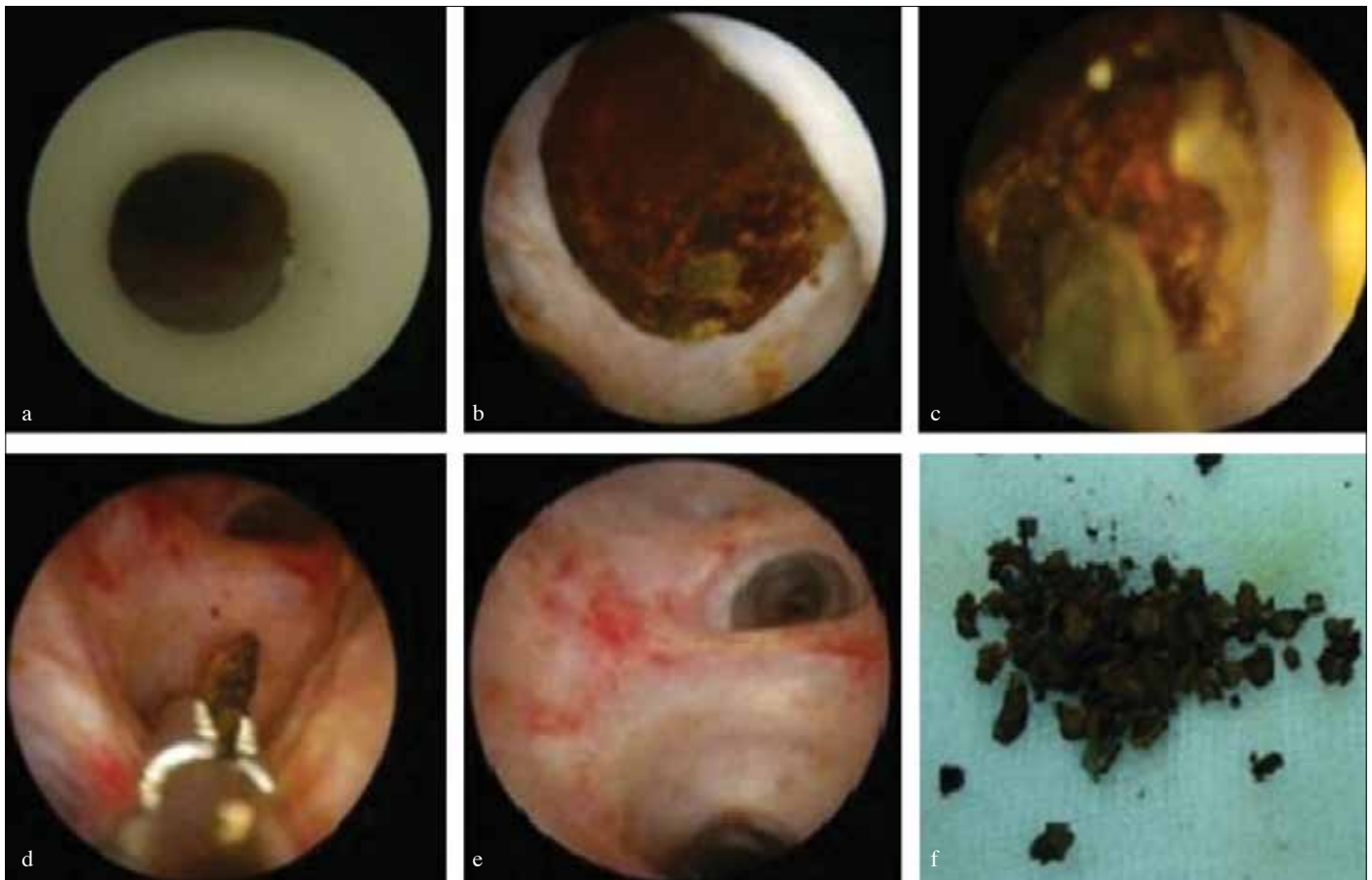


Figure 3. a-f. Surgical technique and the appearance of the stones

nearly 2 cm were observed in the left intrahepatic bile duct and the duct was extremely dilated. The stones were fragmented with pneumatic lithotripter (Aymed Medical, İstanbul, Turkey). The duct was cleaned by completely extracting the stones with forceps and irrigation (Figure 3).

In cholangiography performed afterwards, no problems were observed in the contrast transfer and there were no stones left in the duct. The operation was ended by locating a biliary drainage catheter inside the vascular sheath for drainage. The surgical operation lasted 126 minutes.

The patient didn't have any problems during the postoperative follow-up period, and the stones in the right intrahepatic bile duct were extracted with the same method a week later. The second surgical operation lasted 103 minutes. All stones of the patient in the intrahepatic bile ducts were removed, thus a stone-free state was achieved.

Both operations were successfully performed by a multidisciplinary team including urologists, general surgeons and interventional radiologists.

The patient was discharged on the fourth postoperative day after removal of the drain.

Some results of biochemical analyses made before discharge were as follows: ALT: 13 u/L AST: 35 u/L GGT: 27 u/L ALP: 113 u/L direct bilirubin: 0.23 mg/dL, indirect bilirubin: 0.26 mg/dL, WBC: 5540  $10^3/uL$ , Hb: 11.2 g/dL. PTCH images of the patient before the operation and after UM-PHL are presented in Figure 4.

## Discussion

Although the etiology of hepatolithiasis is not exactly known, it is considered that nutrition, environmental factors and genetic factors play roles in the etiology. The aim of hepatolithiasis treatment is to eradicate the persistent infections and to prevent recurrent cholangitis, hepatic fibrosis and the development of cholangiocarcinoma.<sup>[1]</sup>

Symptomatic hepatolithiasis patients should be treated. But the treatment regimen to be applied should be decided after examining the age, performance condition, general condition of the patient and location of the stone carefully.

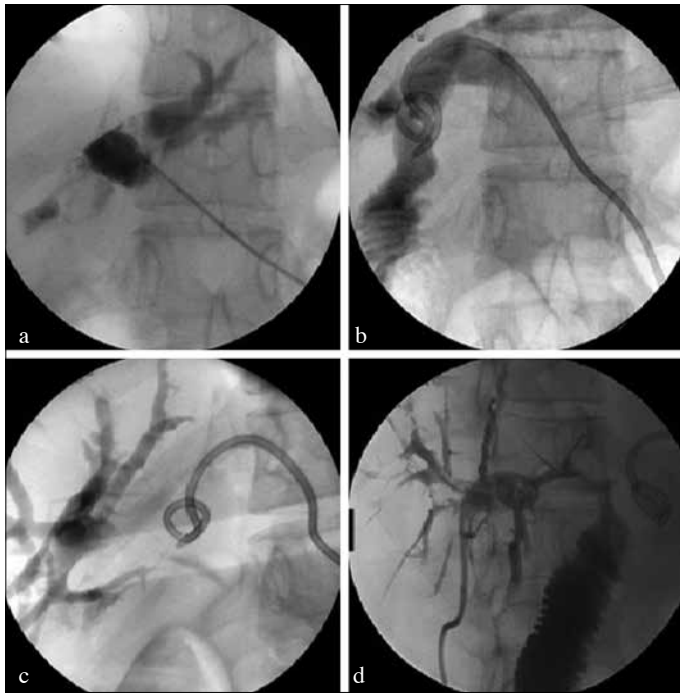

Figure 4. a-d. Pre-, and postoperative percutaneous transhepatic cholangiography (PTCH) images

Pharmacotherapy for stone dissolution is not recommended as it is not effective.<sup>[6]</sup>

While hepatectomy was the main treatment method for these patients before, it is mostly recommended for intrahepatic bile duct cancer and hepatotrophy patients together with hepatotectomy in recent years. But it is not recommended as the primary treatment method in patients who had bile duct operations.<sup>[6,7]</sup>

Feng et al.<sup>[11]</sup> asserted that hepatectomy was the best option for the disease recurrence in the treatment of type 2b hepatolithiasis patients.

But our case had type 2b hepatolithiasis and was symptomatic with recurrent pancreatitis and cholangitis attacks and gastrointestinal findings. The stones of our patient were bilobar, multiple and large. So decision for hepatectomy was quite difficult to make. Because it was not possible to completely foresee the condition of liver function remaining after the area with the stone was resected. UM-PHL was planned due to our patient's history of biliary surgery, high bilobar stone load and high morbidity.

The results of ESWL monotherapy are not completely known in hepatolithiasis patients. It is generally used to break the stones into smaller pieces together with percutaneous transhepatic cholangioscopy (PTHCS) and peroral endoscopic treatment

(POCS). Fragmentation rate acquired with ESWL depends on the type of the stone. As was reported cholesterol stones can be easily, but calcium bilirubinate stones hardly fragmented.<sup>[6,8]</sup> We didn't prefer to apply ESWL in our case since we used pneumatic lithotripter in percutaneous treatment and didn't know the stone type.

Although POCS including endoscopic sphincterotomy (EST) and endoscopic papillary balloon dilatation (EPBD) treatments is recommended for use in biliary reconstructive surgery, it is mostly recommended for patients with bleeding tendency who have stones smaller than 1 cm.<sup>[6]</sup> In the literature It has been applied generally for patients who had both cholelithiasis and hepatolithiasis and postoperative complications such as cholangitis and liver abscess were observed.<sup>[6]</sup> POCS was not applied in this case as the stone size was over 2 cm and the patient had had cholecystectomy.

Treatments such as PTHSC-guided basket lithotripsy and pushing the stones towards the jejunum were applied in the past. PTHCS treatment combined with ESWL can be more successful when the stone load is low without any significant bile duct constriction but the complete extraction of the stones should be aimed. Residual stone and recurrence rates are high in patients who had gall duct reconstruction. It can also cause complications such as bleeding, cholangitis, perforation and abscess formation. On an average 3.9-6 treatment sessions are required for complete extraction of the stones and prolonging the hospitalization duration also constitutes a problem.<sup>[9-11]</sup> PTHSC was applied 3 times in this case before and a significant degree of decrease couldn't be provided in stone load.

Frequent use of percutaneous transhepatic cholangioscopy lithotripsy (PTHCSL) is recommended in the treatment of hepatolithiasis patients. But failure was reported in 40% of the cases due to residual stones and recurrence rates because of the presence of extreme stone load and intrahepatic strictures.<sup>[12]</sup> Although UM-PHL is similar to PTHCSL, it can reach intrahepatic bile ducts more easily since the tools used are small and it can be foreseen that recurrence rates would be lower as the stones are not just broken into smaller pieces but they are also extracted.

In the literature, contrary to the stone extraction procedures performed within extrahepatic bile ducts, there is a quite low number of cases where percutaneous interventions were performed within intrahepatic bile ducts and imaging is provided with endoscopic instruments and the stones are broken with different lithotriptors (laser, electrohydraulic, pneumatic) and extracted with instruments.<sup>[2,13]</sup>

With 24 F nephroscope used in percutaneous nephrolithotomy, Sukumar et al.<sup>[13]</sup> intervened in a patient with intrahepatic gall

stones and the stones were broken with pneumatic lithotripter and extracted with grasper. No problems occurred during the patient follow-up. This case is the first case where intrahepatic gall stones were broken with pneumatic lithotripter and also the stones were extracted percutaneously through lithotomy tract. Working with percutaneous large instruments makes the complete extraction of the stones easier and may be helpful in shortening the operative times. But working through widely dilated access tracts and large-diameter endoscopes may cause the transfer of high pressurized and large amount of water to intrahepatic bile ducts and have negative results such as the delay of recovery when the drainage catheter is pulled away.

Nadler et al.<sup>[2]</sup> through an intrahepatic 14 F dilatation, inserted flexible urethrosopes, cystoscopes or semirigid urethrosopes for visualization, and also laser and electrohydraulic probes as lithotriptors in three cases. Dilatation with ERCP was required in one of the cases. The stones were not extracted completely in the other case. Fragmented stone pieces were pushed to duodenum using a basket and irrigation. Laser lithotriptors were reported to be effective in breaking intrahepatic and extrahepatic gall stones.<sup>[3,14]</sup> Even though this study is called hepatolithotomy, the operation was actually a PTCHSL procedure. But as laser lithotriptors break a small number of stones in every pulsatile stroke in patients with large stones, problems such as prolongation of the surgery, use of too much fluid due to the longevity of the operation and inability to completely extract the stones in a single session may be faced. Similarly European Association of Urology Guideline recommends PNL operation where generally pneumatic lithotriptors are used as the first option for large kidney stones (over 2 cm) rather than laser lithotripsy.<sup>[15]</sup>

Lee et al.<sup>[16]</sup> applied PTCHSL treatment in 34 patients and primarily located 8.5 F biliary drainage catheter and made 16-18 F dilatation in one or two sessions on the third day after catheterization and surgical operation was applied nearly 10-14 days later. Electrohydraulic lithotripter was used for breaking the stones and the stones were extracted using a basket and forceps and pushing them towards the duodenum. They reported 6.1% severe and 51% low-medium level of complication. Also the stone load of the patients was not mentioned in this study.

Different from the other techniques, providing access with 9.5F cystoscope inside the 10 F access sheath, intervention was made in the same session in the UM-PHL technique we applied. So losing no time for entry and dilatation, no complications occurred even though our patients had higher stone load.

In a multi-centered study, a questionnaire was formulated for hepatolithiasis patients and it was observed that 63% of the physicians preferred pharmacotherapy and minimally invasive

methods such as PTCHS, ERCP, POCS and ESWL, while 13.5% of them preferred surgical treatments such as hepatectomy, intraoperative biliary fiberoscopy, laparoscopic choledochotomy, choledochojunostomy and liver transplantation and 30.5% preferred watchful waiting. It was foreseen that minimally invasive treatment methods may be applied more in the future.<sup>[17]</sup> We think that our technique can be a method which may be typically preferred among these minimally invasive interventions.

In most of the past studies, stones were tried to be sent naturally to the intestinal system through lithotripsy. Our hepatolithiasis case is the first case in the literature where such large stones were extracted through minimal lithotomy access tract and complete stone-free state was provided.

So we think that the technique we use in percutaneous hepatolithotomy may be the ideal surgical method as for duration of surgery and stone clearance rate in patients with high stone load.

In hepatolithiasis patients with high stone load, it is a safe and successful method to eradicate the stones by performing percutaneous intervention through minimally dilated access tract regardless of the biliary surgery performed in the past and using instruments with a small diameter and pneumatic lithotripter. We think that UM-PHL procedure done by surgeons who have years of experience in percutaneous nephrolithotomy field and are skilled in percutaneous surgery would increase stone-free, and surgical success, but decrease morbidity rates.

---

**Informed Consent:** Written informed consent was obtained from patient who participated in this case.

**Peer-review:** Externally peer-reviewed.

**Author Contributions:** Concept - A.Ö., M.G.S., S.B., F.A., M.B.; Design - A.Ö., M.G.S., S.B., F.A., M.B.; Supervision - A.Ö., M.G.S., F.A., M.B.; Resources - A.Ö., M.G.S., S.B., F.A., M.B.; Materials - A.Ö., M.G.S., S.B., M.B.; Data Collection and/or Processing - A.Ö., M.G.S., M.S.Ö.; Analysis and/or Interpretation - A.Ö., M.G.S., S.B., Y.E.G., M.S.Ö., F.A., M.B.; Literature Search - A.Ö., M.G.S., Y.E.G., M.S.Ö., M.B.; Writing Manuscript - A.Ö., M.G.S.; Critical Review - A.Ö., M.G.S., F.A., M.B.

**Conflict of Interest:** No conflict of interest was declared by the authors.

**Financial Disclosure:** The authors declared that this study has received no financial support.

---

**Hasta Onamı:** Yazılı hasta onamı hastadan alınmıştır.

**Hakem Değerlendirmesi:** Dış bağımsız.

**Yazar Katkıları:** Fikir - A.Ö., M.G.S., S.B., F.A., M.B.; Tasarım - A.Ö., M.G.S., S.B., F.A., M.B.; Denetleme - A.Ö., M.G.S., F.A., M.B.; Kaynaklar - A.Ö., M.G.S., S.B., F.A., M.B.; Malzemeler - A.Ö., M.G.S., S.B., M.B.; Veri Toplanması ve/veya İşlemesi - A.Ö., M.G.S., M.S.Ö.; Analiz ve/veya Yorum - A.Ö., M.G.S., S.B., Y.E.G., M.S.Ö., F.A., M.B.; Literatür Taraması - A.Ö., M.G.S., Y.E.G., M.S.Ö., M.B.; Yazıyı Yazan - A.Ö., M.G.S.; Eleştirel İnceleme - A.Ö., M.G.S., F.A., M.B.

**Çıkar Çatışması:** Yazarlar çıkar çatışması bildirmemişlerdir.

**Finansal Destek:** Yazarlar bu çalışma için finansal destek almadıklarını beyan etmişlerdir.

## References

1. Feng X, Zheng S, Xia F, Ma K, Wang S, Bie P, Dong J. Classification and management of hepatolithiasis: A high-volume, single-center's experience. *Intractable Rare Dis Res* 2012;1:151-6. [\[CrossRef\]](#)
2. Nadler RB, Rubenstein JN, Kim SC, Weiser AC, Lohr MN, Vogelzang RL, et al. Percutaneous hepatolithotomy: the Northwestern University experience. *J Endourol* 2002;16:293-7. [\[CrossRef\]](#)
3. Healy K, Chamsuddin A, Spivey J, Martin L, Nieh P, Ogan K. Percutaneous endoscopic holmium laser lithotripsy for management of complicated biliary calculi. *JSLs* 2009;13:184-9.
4. Ozgor F, Kucuktopcu O, Ucpinar B, Sarilar O, Erbin A, Yanaral F, et al. The effects of previous open renal stone surgery types on PNL outcomes. *Can Urol Assoc J* 2016;10:E246-50. [\[CrossRef\]](#)
5. Tepeler A, Başbüyük İ, Tosun M, Armağan A. The role of ultra-mini percutaneous nephrolithotomy in the treatment of kidney stones. *Turk J Urol* 2016;42:261-6. [\[CrossRef\]](#)
6. Tazuma S, Unno M, Igarashi Y, Inui K, Uchiyama K, Kai M, et al. Evidence-based clinical practice guidelines for cholelithiasis 2016. *J Gastroenterol* 2017;52:276-300. [\[CrossRef\]](#)
7. Chen C, Huang M, Yang J, Yang C, Yeh Y, Wu H, et al. Reappraisal of percutaneous transhepatic cholangioscopic lithotomy for primary hepatolithiasis. *Surg Endosc* 2005;19:505-9. [\[CrossRef\]](#)
8. Sackmann M, Holl J, Sauter GH, Pauletzki J, von Ritter C, Paumgartner G. Extracorporeal shock wave lithotripsy for clearance of bile duct stones resistant to endoscopic extraction. *Gastrointest Endosc* 2001;53:27-32. [\[CrossRef\]](#)
9. Huang MH, Chen CH, Yang JC, Yang CC, Yeh YH, Chou DA, et al. Long-term outcome of percutaneous transhepatic cholangioscopic lithotomy for hepatolithiasis. *Am J Gastroenterol* 2003;98:2655-62. [\[CrossRef\]](#)
10. Lee SK, Seo DW, Myung SJ, Park ET, Lim BC, Kim HJ, et al. Percutaneous transhepatic cholangioscopic treatment for hepatolithiasis: an evaluation of long-term results and risk factors for recurrence. *Gastrointest Endosc* 2001;53:318-23. [\[CrossRef\]](#)
11. Miyoshi H, Inui K, Yoshino J. Technique of common bile duct and intrahepatic stone treatment with percutaneous transhepatic cholangioscopy. *Gastroenterol Endosc* 2011;53:1818-27.
12. Sakpal SV, Babel N, Chamberlain RS. Surgical Management of Hepatolithiasis. *HPB (Oxford)* 2009;11:194-202. [\[CrossRef\]](#)
13. Sukumar S, Bhat HS, Moorthy S. Nephroscope in the management of recurrent pyogenic cholangitis. *Surg Laparosc Endosc Percutan Tech* 2011;21:e319-21. [\[CrossRef\]](#)
14. Bark K, Gamblin TC, Zuckerman R, Geller DA. Operative cholecholescopic laser lithotripsy for impacted intrahepatic gallstones: a novel surgical approach. *Surg Endosc* 2009;23:221-4. [\[CrossRef\]](#)
15. Türk C, Petřík A, Sarica K, Seitz C, Skolarikos A, Straub M, et al. EAU Guidelines on Interventional Treatment for Urolithiasis. *Eur Urol* 2016;69:475-82. [\[CrossRef\]](#)
16. Lee JH, Kim HW, Kang DH, Choi CW, Park SB, Kim SH, et al. Usefulness of percutaneous transhepatic cholangioscopic lithotomy for removal of difficult common bile duct stones. *Clin Endosc* 2013;46:65-70. [\[CrossRef\]](#)
17. Tazuma S, Nakanuma Y. Clinical features of hepatolithiasis: analyses of multicenter-based surveys in Japan. *Lipids Health Dis* 2015;14:129. [\[CrossRef\]](#)