



Laparoscopic ureteral reimplantation with Boari flap for the management of long- segment ureteral defect: A case series with review of the literature

Uzun üreter segment defektlerinin tedavisinde laparoskopik yöntemle Boari flep üreter reimplantasyonu: Literatürün gözden geçirilmesiyle birlikte bir olgu serisi

Ankur Bansal, Rahul Janak Sinha, Ankur Jhanwar, Gaurav Prakash, Bimalesh Purkait, Vishwajeet Singh

Cite this article as: Bansal A, Sinha RJ, Jhanwar A, Prakash G, Purkait B, Singh V. Laparoscopic ureteral reimplantation with Boari flap for the management of long- segment ureteral defect: A case series with review of the literature. Turk J Urol 2017; 43: 313-8

ABSTRACT

Objective: The incidence of ureteral stricture is showing a rising trend due to increased use of laparoscopic and upper urinary tract endoscopic procedures. Boari flap is the preferred method of repairing long- segment ureteral defects of 8-12 cm. The procedure has undergone change from classical open (transperitoneal and retroperitoneal) method to laparoscopic surgery and recently robotic surgery. Laparoscopic approach is cosmetically appealing, less morbid and with shorter hospital stay. In this case series, we report our experience of performing laparoscopic ureteral reimplantation with Boari flap in 3 patients.

Material and methods: This prospective study was conducted between January 2011 December 2014. The patients with a long- segment ureteral defect who had undergone laparoscopic Boari flap reconstruction were included in the study. Outcome of laparoscopic ureteral reimplantation with Boari flap for the management of long segment ureteral defect was evaluated.

Results: The procedure was performed on 3 patients, and male to female ratio was 1:2. One patient had bilateral and other two patient had left ureteral stricture. The mean length of ureteral stricture was 8.6 cm (range 8.2 -9.2 cm). The mean operative time was 206 min (190 to 220 min). The average estimated blood loss was 100 mL (range 90-110 mL) and mean hospital stay was 6 days (range 5 to 7 days). The mean follow up was 19 months (range 17-22 months). None of the patients experienced any complication related to the procedure in perioperative period.

Conclusion: Laparoscopic ureteral reimplantation with Boari flap is safe, feasible and has excellent long term results. However, the procedure is technically challenging, requires extensive experience of intracorporeal suturing.

Keywords: Boari flap; laparoscopic; ureter.

ÖZ

Amaç: Laparoskopik ve üst üriner sistem endoskopik işlemlerinin sık uygulanması nedeniyle üreter darlığının insidansı artan bir eğilim sergilemektedir. Uzun (8-12 cm) üreter segmenti defektlerinin onarımında Boari flep tercih edilen bir yöntemdir. Bu işlemde klasik açık (transperitoneal ve retroperitoneal) yöntemden laparoskopik yöneme ve son zamanlarda robotik cerrahi yöneme geçilmiştir. Laparoskopik yaklaşım kozmetik açıdan uygun, daha az morbid ve daha kısa süre hastanede yatışı gerektiren bir yaklaşımdır. Bu olgu serisinde laparoskopik yöntemle Boari flep kullanarak üreter reimplantasyonu uyguladığımız üç hastayı raporlamaktayız.

Gereç ve yöntemler: Bu prospektif çalışma Ocak 2011 ile Aralık 2014 tarihleri arasında yapılmıştır. Uzun segmentli üreteral defekti olan ve laparoskopik Boari flep uygulanan hastalar çalışmaya dahil edilmiştir. Uzun segmentli üreter defektinin tedavisinde laparoskopik yöntemle yapılan Boari flep reimplantasyonunun sonuçları değerlendirilmiştir.

Bulgular: İşlem 3 hastada uygulanmıştır. Erkek/kadın hasta oranı 1:2 idi. Bir hastada çift ve diğer iki hastada sol üreter darlığı mevcuttu. Üreter darlığının ortalama uzunluğu 8,6 cm (8,2-9,2 cm), ortalama ameliyat süresi 206 dakika (190-220 dakika) idi. Ortalama tahmini kan kaybı 100 mL (90-110 mL) ve ortalama hastanede kalış süresi 6 gün (5-7 gün) idi. Ortanca izlem süresi 19 ay (17-22 ay) idi. Perioperatif dönemde hastaların hiçbirinde işleme bağlı komplikasyon gözlenmedi.

Sonuç: Laparoskopik Boari flep üreter reimplantasyonu güvenli, uygulanabilir ve mükemmel uzun dönem sonuçlara sahiptir. Ancak işlem teknik açıdan zordur ve intrakorporeal sütür atmada deneyim gerektirir.

Anahtar Kelimeler: Boari flep; laparoskopik; üreter.

King George Medical
University, Lucknow, Uttar
Pradesh, India

Submitted:
23.06.2016

Accepted:
20.09.2016

Available Online Date:
31.07.2017

Correspondence:
Ankur Bansal
E-mail:
ankurbansaldmc@gmail.com

©Copyright 2017 by Turkish
Association of Urology

Available online at
www.turkishjournalofurology.com

Introduction

The incidence of ureteral stricture is rising due to increased use of laparoscopic and upper urinary tract endoscopic procedures.^[1,2] Ureteral reimplantation with Boari flap has undergone change from classical open (transperitoneal and retroperitoneal) method to laparoscopic surgery and recently there are reports of robot-assisted laparoscopic repairs.^[3,4] With increasing skills and availability of laparoscopic instruments, there are studies on managing long- segment ureteral stricture by laparoscopic reimplantation with Boari flap. However, the reconstruction is technically challenging and needs considerable expertise of intracorporeal suturing. This procedure is indicated for management of long -segment ureteral defect (≥ 8 cm). This approach is cosmetically appealing, less morbid with shorter hospital stay.

Material and methods

This prospective study was conducted between 1st January 2011 to 31st December 2014, in the department of Urology, King George's Medical University situated in North India. Informed consent was obtained from all patients. A total of 3 patients with a long- segment ureteral defect (median, 8.6 cm; range 8.2-9.2 cm) who had undergone laparoscopic Boari flap reconstruction were included in the study. A detailed history and clinical examination was performed in all cases. Ultrasonographic examination of kidney, ureter and bladder (KUB) was done in all cases. Other imaging studies like intravenous urography (IVU) (n=3), and computed tomography urography (CTU) (n=2) were performed to delineate the site and length of ureteral stricture. In one patient with bilateral ureteral stricture had history of radical hysterectomy for cervical cancer. DTPA (diethylenetriamine-pentaacetic acid) scan was done in all cases to assess the split

renal function. Initially all patients had undergone percutaneous nephrostomy (PCN) and a nephrostogram was performed. Cystoscopy and retrograde ureterogram were performed before proceeding for reconstruction. At three months of follow up, a renal and bladder ultrasound, intravenous urography and DTPA scan were done. Resolution of hydronephrosis and unobstructed drainage were considered as successful outcome.

Surgical technique

All procedures were performed under general anaesthesia. Patient was placed in supine position with 45 degree tilt on the affected side. A 14 Fr Foley urethral catheter was inserted before the procedure. Transperitoneal approach was employed in all cases and all repair was done by a single urologist using three ports only. After creation of pneumoperitoneum, incision was made at white line of Toldt and colon was reflected medially. Ureter was identified and dissected caudally till the level of stricture. Ureter was handled meticulously with preservation of periureteral adventitia, and stenosed segment of ureter was resected. Ureteral cut end was then spatulated posteriorly at 6 O' clock position for 2.5 cms. Bladder then distended with 300 mL of normal saline (0.9%) and all adhesions were cleared. On anterolateral bladder wall, a flap was raised with the base and tip being 4 and 3 cm in width respectively. The tip of the flap was localized just proximal to the bladder neck and its base at dome. Tension-free anastomosis of spatulated ureter and bladder flap was performed with 4-0 polyglactin sutures over a 6Fr/26 cm double J stent. Anastomosis was performed over double J stent in continuous watertight fashion. Bladder was closed in a single layer with continuous sutures (Figure 1-6). A soft silastic tube drain was inserted into pelvis at the end of the procedure. Drain was removed after 48 hrs and double J stent after six weeks.

Table 1. Baseline demographic and clinical data of the patients

Parameters	Case 1	Case 2	Case 3
Age (years)	40	54	36
BMI (kg/m ²)	25.2	26.5	3.2
Sex (Male: female)	Female	Female	Male
Laterality	Left	Bilateral	Left
Ureteral defect (cm)	9.2	8.4	8.2
Interval between injury and operative intervention (months)	2	3	4
Serum creatinine (mg/dL)	1.5	1	1.1
Cause	Post-hysterectomy	Post-radical Hysterectomy	Post-colorectal surgery
Pre op PCN	PCN	Bilateral PCN	PCN

BMI: body mass index; PCN: percutaneous nephrostomy

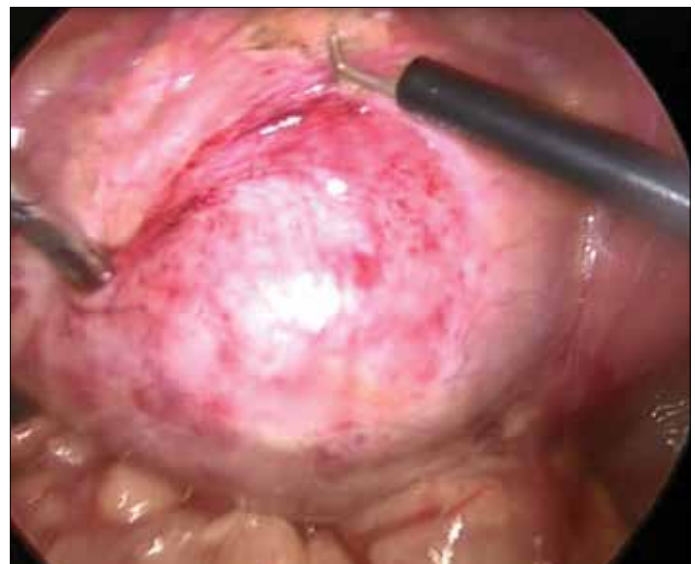

Figure 1. Preparing for Boari flap

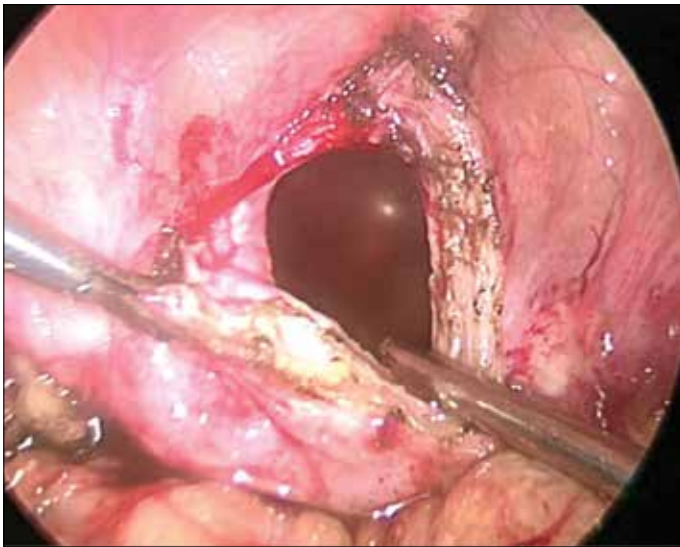


Figure 2. Elevating Boari flap

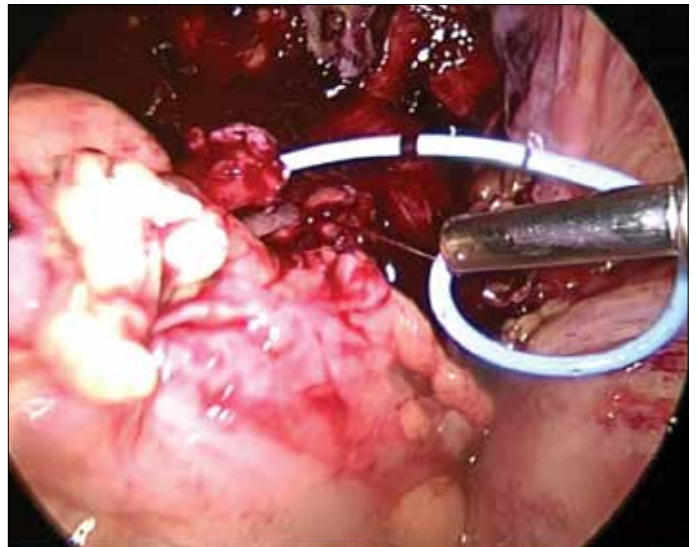

Figure 4. Antegrade placement of Double J stent

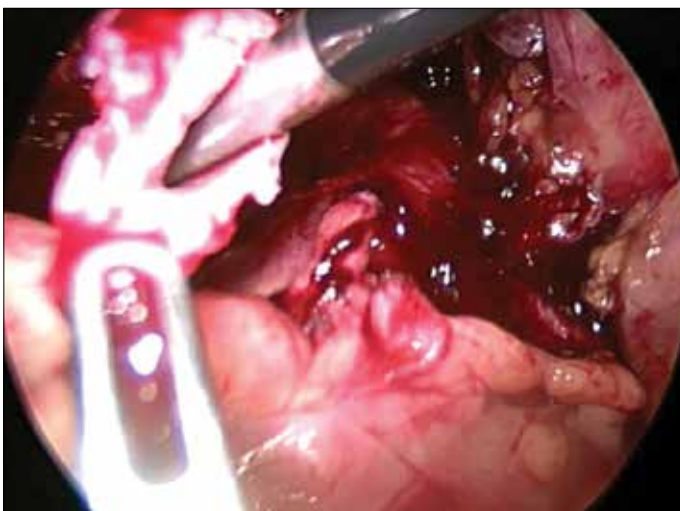

Figure 3. Spatulation of ureter

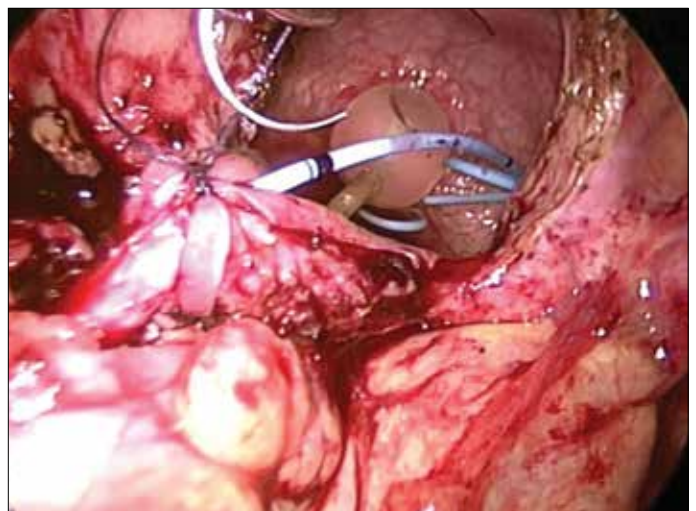


Figure 5. Spatulated ureter anastomosed end- to- end with the apex of flap and flap being tubularised over double J stent

Results

A total of 3 patients underwent ureteral reconstruction. Demographic characteristics of the patients are shown in Table 1. The median age of the patients was 43.3 years (range 36 to 54 years) with male to female ratio of 1:2. The left side involvement was predominant (R:L, 1:2). The cause for ureteral defect was hysterectomy in 2 patients (66.6%), and colorectal surgery in one patient (33.33%). The median interval between injury and repair was 3 months (2-4 months). One patient had history of radical hysterectomy for carcinoma of cervix. She developed bilateral ureteral stricture following the procedure. She underwent right sided

laparoscopic ureteroneocystostomy followed by laparoscopic ureteral reimplantation Boari flap on the contralateral side 3 months later. The median length of ureteral defect was 8.6 cm (range 8.2-9.2 cm). The median operative time was 206 min (range 190 to 220 min). The average estimated blood loss was 100 mL (range 90-110 mL) and the median hospital stay was 6 days (range 5 to 7 days). There were no intraoperative complications. Procedure was completed successfully in all three patients. None of the patients developed any postoperative complications. The median follow up was 19 months (17-22 months). Following stent removal, renal ultrasound showed resolution of hydronephrosis in all cases with unobstructed drainage pattern on DTPA scan. Perioperative data is summarised in Table 2.

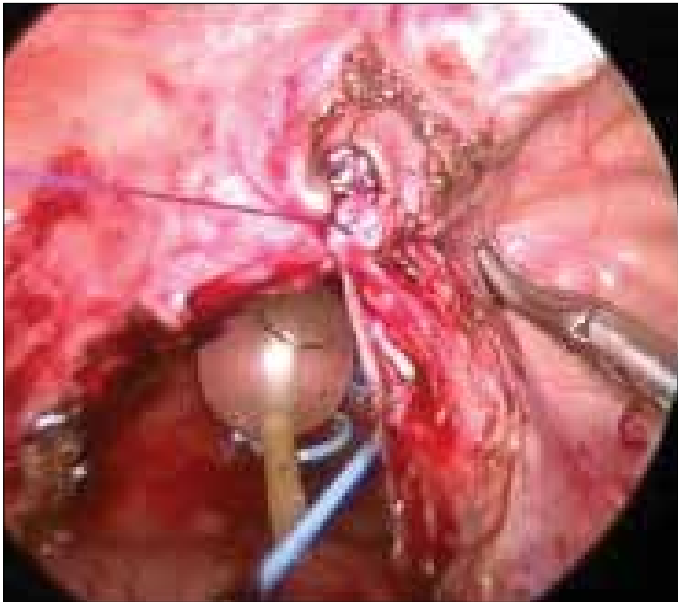


Figure 6. Closure of bladder defect with continuous vicryl suture

Table 2. Perioperative data of patients

Parameters	Case 1	Case 2	Case 3
Operative time (min)	190	220	210
Blood loss (mL)	90	110	100
Time to drain removal (hours)	48	48	48
Hospital stay (days)	6	7	5
Pain score (VAS) at POD 1	3	3	3
Analgesic requirement (Tramadol in mg)	200	400	300
Follow up (months)	18	17	22
Conversion to open	No	No	No
Post- Op US KUB	HDN resolved	HDN resolved	HDN resolved
DTPA Renal Scan	Non-Obstructive	Non-obstructive	Non-obstructive

VAS: visual analogue scale; USG KUB: ultrasound kidney, ureter, bladder; DTPA: diethylenetriaminepentaacetic acid

Table 3. Literature review: reported series of laparoscopic ureteral reimplantation with Boari flap

Authors	Cases (n)	Stricture length (cms)	Etiology	M/F	Side	OT Time (min)	Hospital stay (d)	Blood loss(ml)	F-up (mo)	Analgesic requirement
Fergany et al. ^[10]	6 pigs					140				
Fugita et al. ^[6]	3	6.6		1M 2 F	1 R 2 L	220	6.3	470	11	45 g morphine
Castillo et al. ^[9]	9	4-7	8US 1 UT			156	3	124	17.6	32 mg morphine
Modi et al. ^[11]	1					210	3	90		50 mg morphine
Rasweiler et al. ^[7]	4			2M 2 F	3 R 1 L	254	8.2	270		4.9 mg piritramide
Basiri et al. ^[12]	1		UT	M	L	406	5	300		
Nerli et al. ^[13]	1	5	H	F	L	160				
Ramalingam et al. ^[8]	3	8	POM US	1 M 2 F	3 R	320		100	6m-3yrs	
Symons et al. ^[14]	3	5.6	US	3 M	1R 2 L	307	7.3	0.8 g/dl Hb drop	5	175 mg diclofenac 150 mg tramadol
Schimpf and Wegner ^[3]	2 RALBF		US UT	1 F 1 M	R	172 224	2 5	0 200	12 4	
Allarpathi et al. ^[15]	2 RALBF		UT 1F	1 M	2R	245	2	30	6	22 mg morphine
Soares et al. ^[16]	2		H US	2F	1R 1L	120	2	140	6	
Gozen et al. ^[17]	9		US			247.4	8	283	35	

M: male; F: female; R: right; L: left; RALBF: robot-assisted laparoscopic reimplantation with Boari flap; US: ureteral stricture; UT: ureteral tumor; H: hysterectomy; min: minute; d: days; mo: months; F-up: follow up; yrs: years

Discussion

Boari described this method of ureteral reconstruction in 1894 in a canine model^[4] and in human it was first described in 1947.^[5] Open Boari flap procedures have good long-term results. However, open procedure is associated with excessive pain, longer hospital stay, and surgical scar. As the skill of the urologist is increasing in performing laparoscopic surgeries, there is a rapid transition from open to laparoscopic Boari flap reconstruction technique.

Fugita et al.^[6] in 2001, first successfully performed laparoscopic reconstruction with Boari flap in three patients with long- segment ureteral stricture and concluded that the procedure is effective and feasible (Table 3).^[3,6-17] Rassweiler et al.^[7] observed longer operative time (253 minutes vs. 220 minutes), shorter hospital stay (8 days vs.17 day) with 100% success rate in the laparoscopic group as compared with open ureteral reimplantation with Boari flap.

Ramalingam et al.^[8] performed laparoscopic ureteral reimplantation with Boari flap in 3 patients successfully with median operative time of 320 mins (range 300-320 min). Castillo et al.^[9] reported 9 cases of laparoscopic reimplantation procedure with Boari flap. In their study, median operative time was 156 mins, median hospital stay was 3 days and median length of follow- up was 17.6 months. Abraham et al.^[18] reported comparable results between early and delayed repair with Boari flap, however early repair is challenging. Schimpf and Wagner^[3] performed first robotic Boari flap procedure. The operative time was 172 minutes, with hospital stay of 2 days with 12 months of follow-up without any evidence of recurrence of stricture. Robotic surgery may make this procedure easier with better vision and dexterity during suturing. However, this approach has major limitations in terms of high cost, limited availability and inexperience of most of the surgeons worldwide. The present study is a prospective study which comprised 3 patients with median stricture length of 8.6 cm (range 8.2-9.2 cm), the median operative time of 206 min (range 190-220 min), median hospital stay of 6 days (range 5-7 days), and median follow up of 19 months (17-22 months) with 100% the success rate. These results are comparable to the literature findings. The interesting part of our study is pain scoring (VAS) done on the first postoperative day (POD1) and analgesic requirement. The median pain score was 3.33 (range 3-4) and the mean analgesic requirement was 300 mg of tramadol (200-400 mg). These findings are also comparable to the literature data. One patient had bilateral ureteral stricture developed following radical hysterectomy. In this patient laparoscopic ureteroneocystostomy was performed first on one side and then laparoscopic reconstruction with Boari flap was performed on the contralateral side after 3 months with excellent results.

Laparoscopic reimplantation with Boari flap is a safe, feasible and less morbid procedure for the management of long- segment ureteral defects. However, the reconstruction is technically challenging and require extensive intracorporeal suturing. This surgical approach provides obvious advantage to the patient in terms of cosmesis and decreased morbidity.

Ethics Committee Approval: Ethics committee approval was received for this study from the ethics committee of King George's Medical University.

Informed Consent: Written informed consent was obtained from all individuals who participated in this study.

Peer-review: Externally peer-reviewed.

Author Contributions: Concept – A.J., R.J.S., A.B.; Design – A.J., R.J.S., A.B.; Supervision – A.B., G.P., B.P., V.S.; Resources – A.J., R.J.S., A.B., V.S.; Materials – A.B., G.P., B.P., V.S.; Data Collection and/or Processing – A.J., R.J.S., A.B., G.P., B.P., V.S.; Analysis and/or Interpretation – A.J., R.J.S., A.B., G.P., B.P., V.S.; Literature Search – A.J., R.J.S., A.B., G.P., B.P., V.S.; Writing Manuscript – A.J., R.J.S., A.B., G.P., B.P., V.S.; Critical Review – A.J., R.J.S., A.B., G.P., B.P., V.S.

Conflict of Interest: No conflict of interest was declared by the authors.

Financial Disclosure: The authors declared that this study has received no financial support.

Etik Komite Onayı: Bu çalışma için etik komite onayı Kral George Tıp Üniversitesi'nden alınmıştır.

Hasta Onamı: Yazılı hasta onamı bu çalışmaya katılan tüm bireylerden alınmıştır.

Hakem Değerlendirmesi: Dış bağımsız.

Yazar Katkıları: Fikir – A.J., R.J.S., A.B.; Tasarım – A.J., R.J.S., A.B.; Denetleme – A.B., G.P., B.P., V.S.; Kaynaklar – A.J., R.J.S., A.B., V.S.; Malzemeler – A.B., G.P., B.P., V.S.; Veri Toplanması ve/veya İşlemesi – A.J., R.J.S., A.B., G.P., B.P., V.S.; Analiz ve/veya Yorum – A.J., R.J.S., A.B., G.P., B.P., V.S.; Literatür Taraması – A.J., R.J.S., A.B., G.P., B.P., V.S.; Yazıyı Yazan – A.J., R.J.S., A.B., G.P., B.P., V.S.; Eleştirel İnceleme – A.J., R.J.S., A.B., G.P., B.P., V.S.

Çıkar Çatışması: Yazarlar çıkar çatışması bildirmemişlerdir.

Finansal Destek: Yazarlar bu çalışma için finansal destek almadıklarını beyan etmişlerdir.

References

1. Grainger DA, Soderstrom RM, Schiff SF, Glickman MG, DeCherney AH, Diamond MP. Ureteral injuries at laparoscopy: Insight into diagnosis, management, and prevention. *Obstet Gynecol* 1990;75:839-43. [\[CrossRef\]](#)
2. Smith A. Management of iatrogenic ureteral strictures after urological procedures. *J Urol* 1988;140:1372-4. [\[CrossRef\]](#)
3. Schimpf MO, Wagner JR. Robot assisted laparoscopic Boari flap ureteral reimplantation. *J Endourol* 2008;22:2691-4. [\[CrossRef\]](#)
4. Casati E, Boari A. A contribution to the experimental plastic surgery of ureter. *Atti Acad Med Natl* 1894;14:149.

5. Ockerblad NF. Reimplantation of the ureter into the bladder by a flap method. *J Urol* 1947;57:845-7. [[CrossRef](#)]
6. Fugita OE, Dinlenc C, Kavoussi L. The laparoscopic Boari flap. *J Urol* 2001;166:51-3. [[CrossRef](#)]
7. Rassweiler JJ, Gozen AS, Erdogru T, Sugiono M, Teber D. Ureteral reimplantation for management of ureteral strictures: a retrospective comparison of laparoscopic and open techniques. *Eur Urol* 2007;51:512-22. [[CrossRef](#)]
8. Ramalingam M, Senthil K, Ganapathy M. Laparoscopic Boari Flap Repair: Report of 3 cases. *J Laparoendosc Adv Surg Tech A* 2008;18:271-5. [[CrossRef](#)]
9. Castillo OA, Litvak JP, Kerkebe M, Olivares R, Urena RD. Early experience with the laparoscopic boari flap at a single institution. *J Urol* 2005;173:862-5. [[CrossRef](#)]
10. Fergany A, Gill IS, Abdel-Samee A, Kaouk J, Meraney A, Sung G. Laparoscopic bladder flap ureteral reimplantation: survival porcine study. *J Urol* 2001;166:1920-3. [[CrossRef](#)]
11. Modi P, Goel R, Dodia S, Devra A. Case report: laparoscopic Boari flap. *J Endourol* 2006;20:642-5. [[CrossRef](#)]
12. Basiri A, Karami H, Mehrabi S, Javaherforooshzadeh A. Laparoscopic distal ureterectomy and Boari flap ureteroneocystostomy for a low-grade distal ureteral tumor. *Urol J* 2008;5:120-2.
13. Nerli RB, Reddy MR, Ravish IR, Amarked SS. Laparoscopic bladder (Boari) flap ureteroneocystostomy. *J Multidiscip Healthc* 2008;1:15-6.
14. Symons S, Kurien A, Desai M. Laparoscopic ureteral reimplantation: a single center experience and literature review. *J Endourol* 2009;23:269-74. [[CrossRef](#)]
15. Allaparthi S, Ramanathan R, Balaji KC. Robotic distal ureterectomy with boari flap reconstruction for distal ureteral urothelial cancers: a single institutional pilot experience. *J Laparoendosc Adv Surg Tech A* 2010;20:165-71. [[CrossRef](#)]
16. Soares RS, Abreu Jr RA, Tavora JE. Laparoscopic ureteral reimplant for ureteral stricture. *International Braz J Urol* 2010;36:38-43. [[CrossRef](#)]
17. Gözen AS, Cresswell J, Canda AE, Ganta S, Rassweiler J, Teber D. Laparoscopic ureteral reimplantation: prospective evaluation of medium-term results and current developments. *World J Urol* 2010;28:221-6. [[CrossRef](#)]
18. Abraham GP, Das K, Ramaswami K, George DP, Abraham JJ, Thachil T. Laparoscopic reconstruction of iatrogenic-induced lower ureteric strictures: Does timing of repair influence the outcome? *Indian J Urol* 2011;27:465-9. [[CrossRef](#)]