



A rare case of paratesticular leiomyoma in a child

Aydan Arslan¹ , Sila Ulus¹ , Ümit İnce² , Gonca Tekant³ , Ercan Karaarslan¹ 

Cite this article as: Arslan A, Ulus S, İnce Ü, Tekant G, Karaarslan E. A rare case of paratesticular leiomyoma in a child. Turk J Urol 2018; DOI: 10.5152/tud.2018.28813

ORCID IDs of the authors:

A.A. 0000-0002-6073-1927;
S.U. 0000-0002-9313-3165;
Ü.I. 0000-0002-6113-661X;
G.T. 0000-0002-6231-9792;
E.K. 0000-0002-4581-4273.

¹Department of Radiology,
Acıbadem Mehmet Ali Aydınlar
University School of Medicine,
Istanbul, Turkey

²Department of Pathology,
Acıbadem Mehmet Ali Aydınlar
University School of Medicine,
Istanbul, Turkey

³Department of Pediatric
Surgery, Istanbul University
Cerrahpaşa School of Medicine,
Istanbul, Turkey

Submitted:
24.09.2017

Accepted:
16.10.2017

Available Online Date:
12.09.2018

Correspondence:
Aydan Arslan
E-mail:
arslanaydan@gmail.com

©Copyright 2018 by Turkish
Association of Urology

Available online at
www.turkishjournalofurology.com

ABSTRACT

Leiomyomas are benign, slow-growing, smooth muscle tumors, which can occur at many locations in the body. The male genitourinary tract is seldom affected and scrotal leiomyomas are extremely rare. Most of the scrotal leiomyomas are localized in the testis, epididymis, spermatic cord, subcutaneous tissue, tunica albuginea, and scrotal skin and only a few of them are reported in the origin of isolated tissue without paratesticular structures in the paratesticular region. We are presenting a case of solitary paratesticular leiomyoma in a child, which is very rare in terms of lesion location and patient age, and describing the imaging features of this lesion.

Keywords: Child; Doppler ultrasonography; leiomyoma; magnetic resonance imaging; paratesticular leiomyoma.

Introduction

Leiomyomas are benign, slow-growing, smooth muscle tumors.^[1,2] Scrotal lesions can be anatomically divided into intratesticular and paratesticular pathologies. Primary paratesticular masses are rare, and they generally present as asymptomatic and painless palpable masses. The most common primary benign tumor of the paratesticular region is spermatic cord lipoma and the most common primary malignant tumor in adult and pediatric patients is rhabdomyosarcoma.^[3]

In this paper, we report a case of solitary paratesticular leiomyoma and describe the imaging features. To our knowledge few cases of paratesticular leiomyoma have been reported in the English literature so far.^[1,4-7]

Case presentation

A 13-year-old male presented to the pediatric clinic with left scrotal swelling. No local scro-

tal pain, fever or trauma history was present. Physical examination revealed a palpable mass, about 5 centimeters in diameter, on the left side of the scrotum. Serum tumor markers (beta-human chorionic gonadotropin, lactate dehydrogenase, alpha-fetoprotein) were within the normal range. Color Doppler ultrasonography (CDU) examination revealed an extratesticular, well-defined, heterogeneous, hypoechoic mass with minimal peripheral vascularity, containing hyperechogenic foci, measuring 49x39x30 millimeters in size, in the superior part of the left scrotal cavity (Figure 1). Abdominal and testicular dynamic contrast-enhanced magnetic resonance imaging (CE-MRI) was performed with a 3T scanner. A heterogeneously hypointense extratesticular mass lesion measuring 32x43x47 mm in size, on T1-weighted (T1W) and T2W images was noted in the left scrotum. Mild diffusion restriction was observed. On dynamic contrast-enhanced examination; the mass had heterogeneously increased enhancement at the early arterial phase (Figure 2).

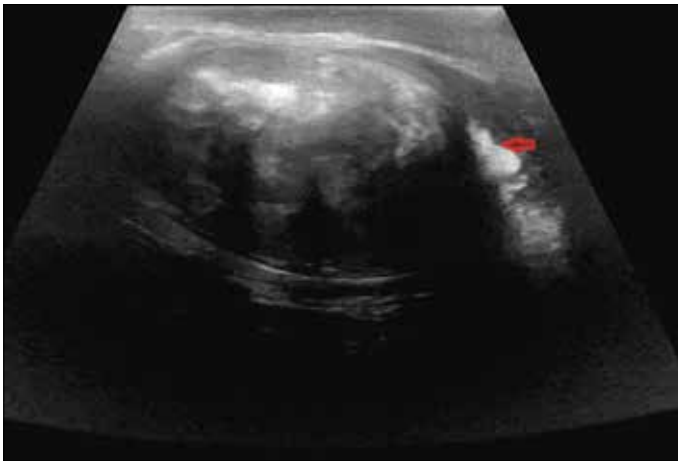


Figure 1. Color Doppler ultrasonography image shows an extratesticular, well-defined, heterogeneous, hypoechoic mass containing hyperechoic foci in the superior part of the left scrotal cavity

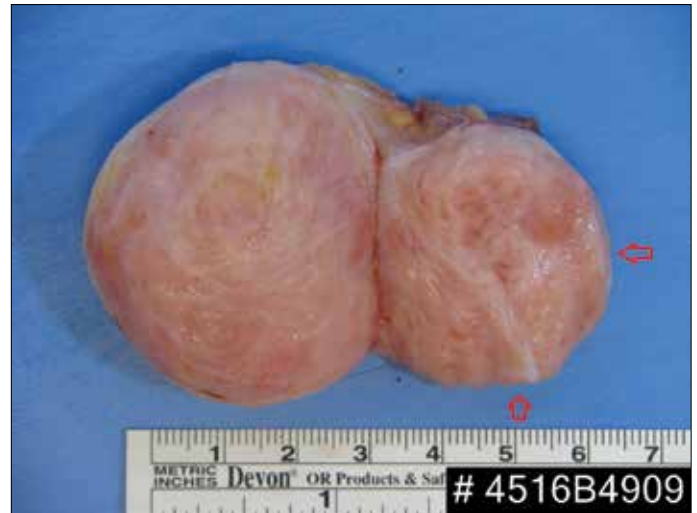

Figure 3. Gross histopathological specimen reveals a solid round mass with white fibrillar structure surface. A cordlike structure is observed on the mass

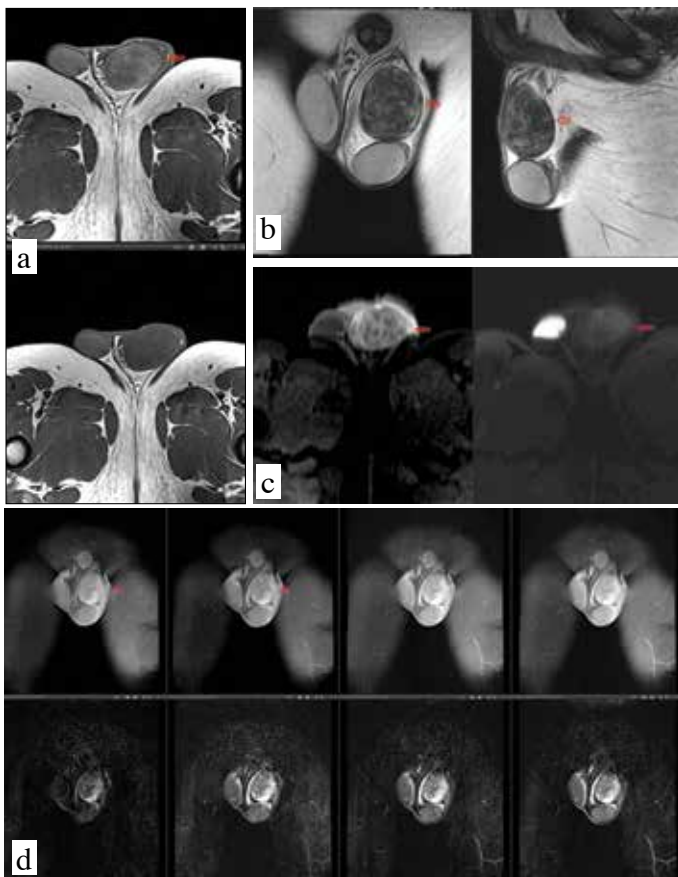


Figure 2. a-d. A heterogeneously hypointense extratesticular mass lesion in the left scrotum is seen on axial (a) and coronal-sagittal (b) T1 and T2-W images in testicular MRI. Mild diffusion restriction was observed (c). Heterogeneously increased contrast enhancement at the early arterial phase is seen on dynamic contrast-enhanced examination (d)

The testis and epididymis were inferiorly displaced due to the expansile effect of the lesion. Plexus pampiniformis was displaced medially. No significant invasion was seen in the surrounding tissues. Spermatic cord and caput epididymis were compressed by the lesion and the left spermatic cord was slightly wider. On surgical exploration; the mass appeared discrete from the testicle and epididymis as in radiological imaging. It was seen that the mass was encapsulated with a stiff elastic structure. There was no invasion of the left testicular vein or cord structures. Total excision of the mass was accomplished with no harm to the testis and epididymis. Any postoperative complication did not develop. After excision, the tumor tissue was sent to the department of pathology for intraoperative frozen section. On frozen section examination; benign mesenchymal tumor with no evidence of malignancy was observed, and the left testis was replaced into the scrotum. Gross histopathological examination of the specimen revealed a solid round mass with a white fibrillar surface weighing 40 gr, and measuring 5x4.3x4 cm in size. A cordlike structure, measuring 3x1.5 cm was observed on the mass (Figure 3). Microscopically, smooth muscle spindle cells arranged within fibrous and hyalinized connective tissue were seen. Nuclear pleomorphism, invasion of the surrounding tissue, necrosis, cellular atypia, or mitoses were not visualized. The mass lesion was positively stained for smooth muscle actin (SMA), caldesmon, and desmin, and negatively for S-100 using immunohistochemical staining methods. Ki-67 proliferation index was 5%. Histopathological and immunohistochemical examinations of the lesion were typical for a leiomyoma. Written informed consent was obtained from the patient who participated in this study.

Discussion

Leiomyomas are benign encapsulated tumors that originate from mesenchymal cells. Scrotal leiomyomas are extremely rare and most of them are localized in the testis, epididymis, spermatic cord, subcutaneous tissue, tunica albuginea, and scrotal skin.^[2,4] Only a few cases are reported in the paratesticular region, namely in the region from where isolated tissue originated, as in our case.^[1,4-7] These tumors may arise from the tunica dartos, and the superficial subcutaneous smooth muscle of the scrotum.^[6] Paratesticular leiomyoma usually presents as a non-tender scrotal mass, and sometimes with local scrotal pain. Leiomyoma presents rarely in the prepubertal population, with incidence peaking between the fourth and fifth decades. To the best of our knowledge, our case is one of the two youngest patients reported in the English literature.^[8] On scrotal CDU we can get information about the localization, structure (the cystic or solid), and vascularization of the lesion, but its sonographic (US) appearance is nonspecific and variable. MRI can reveal the presence of invasion (if any) to the surrounding structures, and internal features of the lesion better than US. Differential diagnosis can easily be made in some lesions, such as cysts and lipomas based on signal characteristics of the lesions in T1 and T2-W sequences.

To exclude malignant tumors, confirmation with intraoperative frozen section after excision of the mass lesion can be performed. Thus, radical orchiectomy for benign lesions in a child with fertility expectancy in the future can be avoided. Total excision of the mass is an appropriate treatment. Leiomyomas are usually well-demarcated masses with white or grey capsule. Microscopically, the tumor is seen to consist of smooth muscle spindle cells arranged in interlacing bundles with varying admixtures of fibrous and hyalinized connective tissue.^[3] In immunohistochemical examination; positive staining for SMA, caldesmon and desmin is important to confirm the diagnosis of leiomyoma. S-100 negativity is necessary to exclude neurofibroma and schwannoma. Low mitotic activity (Ki67 proliferation index was 5 in our case) is also compatible with leiomyoma. The differential diagnosis of solid lesions in that region includes leiomyoma, leiomyosarcoma, rhabdomyoma, rhabdomyosarcoma, fibroma, neurofibroma, schwannoma, and adenomatoid tumor.

In conclusion, paratesticular leiomyomas are rare benign tumors, which present similarly as testicular tumors. They should be

considered in the differential diagnosis of paratesticular solid masses to provide a possibility of treatment with testicular preservation, especially in young men. Imaging can be useful in the evaluation of the invasion to the adjacent structures or the inner structure of the lesion.

Informed Consent: Written informed consent was obtained from patients' parents who participated in this study.

Peer-review: Externally peer-reviewed.

Author Contributions: Concept - A.A.; Design - A.A., S.U.; Supervision - A.A., E.K.; Resources - A.A., E.K.; Materials - A.A., S.U., Ü.İ., G.T.; Data Collection and/or Processing - A.A.; Analysis and/or Interpretation - A.A., S.U., Ü.İ., G.T., E.K.; Literature Search - A.A., E.K.; Writing Manuscript - A.A., S.U., E.K.; Critical Review - A.A., S.U., Ü.İ., G.T., E.K.; Other - A.A., E.K.

Conflict of Interest: Authors have no conflicts of interest to declare.

Financial Disclosure: The authors have declared that they didn't receive any financial support for this study.

References

- Ortega-Hrepich C, Vanderlinden E, Bourgain C, Devroey P, Tournaye H. Paratesticular leiomyoma in an azoospermic patient and-successful testicular sperm extraction (TESE) for intracytoplasmic sperm injection (ICSI) with an ongoing pregnancy. *Facts Views Vis Obgyn* 2012;4:213-5.
- Bremmer F, Kessel FJ, Behnes CL, Trojan L, Heinrich E. Leiomyoma of the tunica albuginea, a case report of a rare tumour of the testis and review of the literature. *Diagn Pathol* 2012;9:140. [\[CrossRef\]](#)
- Akbar SA, Sayyed TA, Jafri SZ, Hasteh F, Neill JS. Multimodality imaging of paratesticular neoplasms and their rare mimics. *Radiographics* 2003;23:1461-76. [\[CrossRef\]](#)
- Rana S, Sharma P, Singh P, Satarkar RN. Leiomyoma of Scrotum: a Rare Case Report. *Iran J Pathol* 2015; 10:243-7.
- Alasmar A, Alkaabna A, Aljader K, Alsaaydah N, Waqfi O. Bilateral Synchronous Paratesticular Leiomyoma: A Case Report. *JRMS* 2014;21:60-3. [\[CrossRef\]](#)
- Giriyani S, Kanchana RH, Paragannavar V. Paratesticular Leiomyoma-A Rare Case Report. *International Journal of Science and Research (IJSR)* 2017;6:445-7. [\[CrossRef\]](#)
- Gorunova L, Bjerkehagen B, Heim S. Paratesticular leiomyoma with a der(14)t(12;14)(q15;q24). *Cancer Genet* 2011;204:465-8. [\[CrossRef\]](#)
- Ozden O, Orhan D, Karnak I. Epididymal leiomyoma: an unusual intrascrotal tumor in a child. *J Pediatr Surg* 2009;44:e5-7.