









# Post-chemotherapy robot-assisted retroperitoneal lymph node dissection in non-seminomatous germ cell tumor of testis: Feasibility and outcomes of initial cases

Ekrem İslamoğlu , Çağatay Özsoy , Hakan Anıl , Yasin Aktaş , Mutlu Ateş , Murat Savaş 

**Cite this article as:** İslamoğlu E, Özsoy Ç, Anıl H, Aktaş Y, Ateş M, Savaş M. Post-chemotherapy robot-assisted retroperitoneal lymph node dissection in non-seminomatous germ cell tumor of testis: Feasibility and outcomes of initial cases. Turk J Urol 2018. DOI: 10.5152/tud.2018.99390

## ABSTRACT

**Objective:** To report our initial experience and short-term results in post-chemotherapy robot-assisted retroperitoneal lymph node dissection (RA-RPLND) for advanced testicular cancer.

**Material and methods:** We analyzed prospectively collected data of 5 patients who underwent post-chemotherapy RA-RPLND between August 2017 and May 2018. All patients had a diagnosis of non-seminomatous germ cell tumor (NSGCT) of testis and received three or four cycles of BEP chemotherapy for their clinical stage IIC disease before the surgery. Perioperative parameters (operation time, estimated blood loss and intraoperative complications) and postoperative findings (change in hematocrit, duration of hospitalization and postoperative complications) were noted. Pathological outcomes and postoperative radiological imaging in the 3<sup>rd</sup> month were investigated.

**Results:** RA-RPLND was completed successfully in all patients, and none of them required conversion to open surgery or early intervention. The median operation time was 309 minutes (range, 275-360), and median estimated blood loss was 180 mL (range, 150-210). One patient required postoperative transfusion of 1U red blood cells. The histologic examination of the specimens revealed necrosis in 3, and mature teratoma in 2 patients. The median hospitalization time after surgery was 2 days. During a median follow-up of 10 months (range 7-12), there were no retroperitoneal recurrences or distant metastasis in radiological imaging. No major complication (Clavien  $\geq$ 3) or death occurred. The only minor complication was transfusion of red blood cells in one patient (Clavien 2) and the overall complication rate was 20 percent.

**Conclusion:** Post-chemotherapy RA-RPLND appears to be a feasible and oncologically safe procedure with acceptable operative morbidity. However, this technique should be applied in centers highly experienced in robotic surgery, considering that RPLND is a surgery with fatal complications.

**Keywords:** Post-chemotherapy; retroperitoneal lymph node dissection; robot-assisted.

### ORCID IDs of the authors:

E.İ. 0000-0003-0693-0666;  
Ç.Ö. 0000-0002-2124-865X;  
H.A. 0000-0002-6333-0213;  
Y.A. 0000-0001-5255-3780;  
M.A. 0000-0003-3951-4271;  
M.S. 0000-0002-3068-4699

Department of Urology,  
University of Health Sciences,  
Antalya Training and Research  
Hospital, Antalya, Turkey

**Submitted:**  
24.09.2018

**Accepted:**  
02.11.2018

**Available Online Date:**  
20.12.2018

**Corresponding Author:**  
Ekrem İslamoğlu  
E-mail:  
meislamoglu@gmail.com

©Copyright 2018 by Turkish  
Association of Urology

Available online at  
www.turkishjournalofurology.com

## Introduction

The survival rates of metastatic testicular cancer patients have significantly improved after the usage of cisplatin-based chemotherapeutic regimens. Because these multiagent regimens provide a complete response rate of 60-80% in patients with metastatic disease, residual masses can remain in the retroperitoneal lymph node template.<sup>[1]</sup> For non-seminomatous germ cell tumors (NSGCT) excision of residual mass after chemotherapy is mandatory in all patients with a retroperitoneal tumor over 1 cm in the short axis at radiologic imaging.<sup>[2,3]</sup> Following first-line bleomycin-etoposide-cisplatin (BEP)

chemotherapy, resected specimens of residual masses contain viable cancer in 6-10%, mature teratoma in 50%, and necrotic-fibrotic tissue in 40% of the cases.<sup>[4]</sup> But the inability to predict reliably the presence of necrotic-fibrotic tissue and the risk of a malignant transformation of a mature teratoma to sarcoma emphasizes the necessity of retroperitoneal lymph node dissection (RPLND).

The RPLND surgery is being performed for almost a century and since its first description, the surgical techniques have evolved from a full, bilateral, suprahilar dissection to a unilateral, nerve-sparing template in selected pa-

tients with equivalent long-term results.<sup>[5-7]</sup> In order to reduce the morbidity of RPLND, laparoscopic approach has gained popularity since its introduction and authors have shown that this technique is superior in terms of morbidity and complication rates with the same oncological results when compared with open surgery.<sup>[8,9]</sup> But the steep learning curve and technical challenges in laparoscopy have limited the widespread adoption of this surgical procedure.

Robot-assisted RPLND (RA-RPLND) has the potential to overcome the technical challenges in laparoscopy and shorten the learning curve. Davol et al described the RA-RPLND procedure initially in 2006 and small series from different institutions were reported over a period of ten years.<sup>[10-13]</sup> But most of the patients have undergone RA-RPLND for clinical stage I-IIA NSGCT in these series.

In this study, we reported our initial experience and short-term results in post-chemotherapy RA-RPLND performed for advanced testicular cancer.

## Material and methods

After the approval of the Ethics Committee of Antalya Training and Research Hospital (Date: 27.09.2018 and no.18/3), we analyzed the prospectively collected data of 5 patients who underwent post-chemotherapy RA-RPLND between August 2017 and May 2018. Written informed consent was obtained from patients who participated in this study. All patients had a diagnosis of NSGCT of testis and received three or four cycles of BEP chemotherapy for their clinical stage IIC disease before the surgery. None of the patients had received salvage chemotherapy and every patient had a residual mass with normal tumor markers.

All RA-RPLNDs were performed by a single surgeon who had advanced robotic surgery skills as well as open and laparoscopic RPLND. All procedures were performed using the da Vinci Xi robotic system via transperitoneal approach with the patients placed in lateral decubitus position. An 8 mm camera port was placed just superior to the umbilicus, the remaining three robotic 8 mm ports and a 12-mm assistant port were placed as shown in Figure 1. Left (n=2) and right-sided (n=2) modified template nerve-sparing RA-RPLNDs, and bilateral full dissection (n=1) were performed in respective number of patients. For right-sided modified template; the gonadal vein, right common iliac lymph nodes (LNs), paracaval, precaval, retrocaval, interaortocaval and preaortic LNs were removed to the level of inferior mesenteric artery. For left-sided modified template; the gonadal vein, left common iliac lymph nodes (LNs), interaortocaval, paraaortic, preaortic and retroaortic LNs were removed to the level of inferior mesenteric artery. For bilateral full dissection; all LNs between the ureters from the renal hilus to the inferior mesenteric artery, the ipsilateral iliac LNs and gonadal vein were removed.

Patients' clinical data and the size of tumor in radiological imaging were noted. Perioperative parameters were recorded such as operation time, estimated blood loss and intraoperative complications. Operation time was defined as skin to skin time in minutes and includes the docking and undocking time. Postoperative parameters including hematocrit change, length of hospital stay and postoperative complications were noted. In order to classify the complications, the Clavien-Dindo system was used.<sup>[14]</sup> Pathological outcomes and postoperative radiological imaging in the 3<sup>rd</sup> month were investigated.

## Statistical analysis

Basic and descriptive statistical analysis have been used in this study and all data were expressed as mean, median (minimum, maximum) for numerical variables; as frequencies and percentages for categorical variables. Statistical analysis was made using IBM Statistical Package for the Social Sciences Statistics for Windows, Version 22.0 (IBM SPSS Statistics Corp., Armonk, NY, USA).

## Results

Patients' demographic and clinical data were listed in Table 1. RA-RPLND was completed successfully in all patients, and none of them required conversion to open surgery or early intervention. The median operation time was 309 minutes (range, 275-

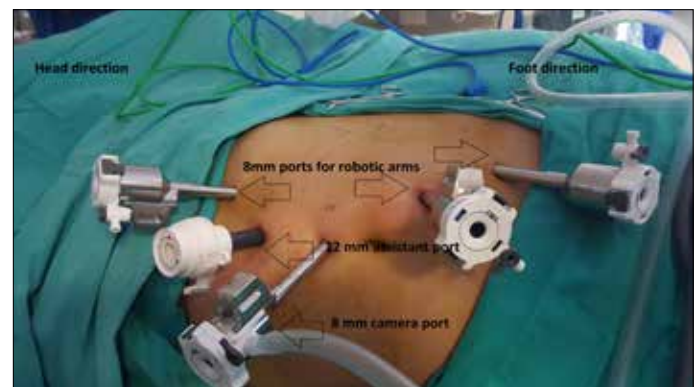


Figure 1. Image showing patient in a left lateral decubitus position and port locations

Table 1. Patients' demographic and clinical data

Patient No.	Age (yr)	Testicular cancer site	Post chemotherapy tumor dimensions (mm)
Patient 1	26	Left	42×33
Patient 2	38	Left	26×24
Patient 3	42	Left	90×45
Patient 4	20	Right	28×16
Patient 5	28	Right	32×18

yr: years; mm: millimeters

**Table 2. Operative and postoperative data of the patients**

Patient No.	Template	Op. time (min)	EBL (mL)	Complication	Final histology	Hosp. stay (days)
Patient 1	Left	280	150	None	Mature teratoma	2
Patient 2	Left	275	160	None	Mature teratoma	3
Patient 3	Bilateral	360	210	RBC transfusion	Necrosis	3
Patient 4	Right	310	180	None	Necrosis	2
Patient 5	Right	320	200	None	Necrosis	2

op: operation; min: minutes; mL: milliliters; hosp: hospital; EBL: estimated blood loss

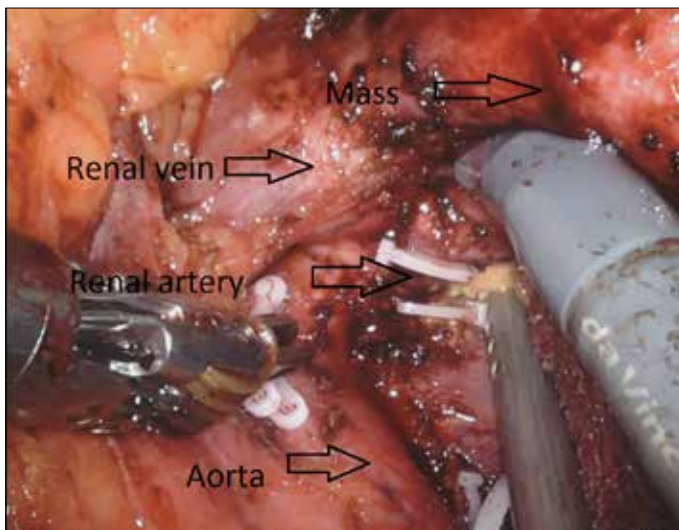


Figure 2. Image showing the retroperitoneal mass that covered renal hilum

360), and the median estimated blood loss was 180 mL (range, 150-210). One patient required postoperative transfusion of 1U of red blood cells. The histologic examination of the specimens revealed necrosis in 3, and mature teratoma in 2 patients. Operative data were listed in Table 2. The median length of hospital stay after surgery was 2 days. During a median follow-up of 10 months (range 7-12), there were no retroperitoneal recurrences or distant metastasis in radiological imaging.

No major complication (Clavien  $\geq 3$ ) or death occurred. The only minor complication was transfusion of red blood cells in one patient (Clavien 2) and the overall complication rate was 20 percent. In Case 3, nephrectomy was essential due to the mass covering the renal hilum (Figure 2) and this decision was taken before the surgery. All the patients had a normal antegrade ejaculation in the 3<sup>rd</sup> month.

## Discussion

Post-chemotherapy RPLND can be more difficult than primary RPLND because fibrosis often obliterates the natural tissue

planes. Hence, it is normal to expect a higher complication rate during post-chemotherapy RPLND than primary lymphadenectomy. The Indiana group stated their complication rate as 20.7% and mortality rate as 0.8% for open RPLNDs performed in 603 patients after chemotherapy.<sup>[15]</sup> These results were poorer when compared with their own primary RPLND series with 478 patients.<sup>[16]</sup> Other studies have reported their complication rates up to 35% with open RPLNDs performed after chemotherapy.<sup>[17,18]</sup> Laparoscopic RPLND in the post-chemotherapy settings was first reported by Rassweiler et al. but the high rate of conversion to open surgery has led the authors not to recommend this procedure.<sup>[19]</sup> Later, other series reported better results for laparoscopic lymphadenectomy but they reported that although that was a technically feasible surgery, it was yet difficult.<sup>[20,21]</sup>

Robotic systems have the potential to overcome the technical challenges of pure laparoscopy and to facilitate the procedure. The first RA-RPLND and following 3 studies reported their experience in primary RA-RPLND.<sup>[10-13]</sup> But in only a few studies the outcomes of RA-RPLND performed in the post-chemotherapy settings.<sup>[22-25]</sup> Although these studies had small number of patients and short-term follow-up periods, they reported acceptable surgical and oncological outcomes. Our results were in concordance with these studies in terms of oncological results. In these 4 studies the authors reported minor (Clavien  $\leq 2$ ) and major (Clavien  $\geq 3$ ) complications in 18, and 10% of the cases respectively. Although bleomycin-related pulmonary complications have been frequently stated in the open RPLND series; chylous ascites and postoperative ileus were the most common minor complications while vascular injuries constituted most of the major complications in RA-RPLND series. In our series, rate of complications was 20% which was similar to the robotic series. We didn't observe any wound or pulmonary complications and none of the patients required conversion to open surgery due to vascular or visceral injury. We have not seen chylous ascites in our patients which might be explained by the extensive use of clips instead of coagulation. Overall, these results, combined with favorable oncological results and high rate of antegrade ejaculation, support the safety of RA-RPLND when performed by experienced robotic surgeons.

There is still a controversy about what should be the extent of post-chemotherapy RPLND. Incomplete dissection can result in retroperitoneal recurrences and increased burden of chemotherapy.<sup>[26]</sup> Published data indicate that a limited dissection using a modified template provides favorable results if patients exhibit a well-defined lesion of  $\leq 5$  cm in diameter corresponding to the primary landing site of the tumor-bearing testis. But concerning the surgery for high-volume lesions, there is a common approach that these patients should be treated by a full bilateral RPLND independent of the site.<sup>[7]</sup> In our study, we have complied with these principles and we have observed no relapses in the retroperitoneum or distant metastasis during 10 months follow-up.

We performed all RA-RPLNDs in the lateral decubitus position. Although this position was adequate for unilateral template dissections, we found it difficult to access the contralateral lymph nodes for cases requiring bilateral full dissection. In the latest studies the authors reported that they were able to perform both unilateral and bilateral lymphadenectomy safely and effectively in the supine position.<sup>[27,28]</sup> So, we may change our patients' positioning to the supine approach to overcome the limitations, especially inherent to bilateral dissection.

Our study has some limitations. First of all, this is a small series of patients and we reported only short-term oncological results thus no conclusions can be made about the equivalency of RA-RPLND and open or laparoscopic RPLND in terms of safety, and reliability. Secondly, this study is limited by the nature of being a retrospective review although all patients' operative data were collected prospectively.

In conclusion, post-chemotherapy RA-RPLND appears to be a feasible and oncologically safe procedure with acceptable operative morbidity. However, this technique should be applied in centers highly experienced in robotic surgery, considering that RPLND is a surgery with fatal complications. Also, larger series with longer follow-up are essential to fully understand the therapeutic efficacy and safety of RA-RPLND.

**Ethics Committee Approval:** Ethics committee approval was received for this study from the ethics committee of Antalya Training and Research Hospital (Date:27.09.2018 and no.18/3).

**Informed Consent:** Written informed consent was obtained from patients who participated in this study.

**Peer-review:** Externally peer-reviewed.

**Author Contributions:** Concept – E.İ., Ç.Ö.; Design – E.İ., Ç.Ö., H.A., Y.A.; Supervision – E.İ., M.S.; Resources – E.İ., M.A., M.S.; Materials – Ç.Ö., H.A., Y.A.; Data Collection and/or Processing – Ç.Ö., H.A., Y.A.; Analysis and/or Interpretation – E.İ., M.A., M.S.; Literature Search – E.İ., Ç.Ö., H.A., Y.A.; Writing Manuscript – E.İ.; Critical Review – M.A., M.S.

**Conflict of Interest:** The authors have no conflicts of interest to declare.

**Financial Disclosure:** The authors have declared that they did not receive any financial support for this study.

## References

1. Williams SD, Birch R, Einhorn LH, Irwin L, Greco FA, Loehrer PJ. Treatment of disseminated germ-cell tumors with cisplatin, bleomycin, and either vinblastine or etoposide. *N Engl J Med* 1987;316:1435-40. [\[CrossRef\]](#)
2. Hendry WF, Norman AR, Dearnaley DP, Fisher C, Nicholls J, Huddart RA, et al. Metastatic nonseminomatous germ cell tumors of the testis: results of elective and salvage surgery for patients with residual retroperitoneal masses. *Cancer* 2002;94:1668-76. [\[CrossRef\]](#)
3. Sheinfeld J. The role of adjunctive postchemotherapy surgery for nonseminomatous germ-cell tumors: current concepts and controversies. *Semin Urol Oncol* 2002;20:262-71. [\[CrossRef\]](#)
4. Carver BS, Serio AM, Bajorin D, Motzer RJ, Stasi J, Bosl GJ, et al. Improved clinical outcome in recent years for men with metastatic nonseminomatous germ cell tumors. *J Clin Oncol* 2007;25:5603-8. [\[CrossRef\]](#)
5. Hinman F. The radical operation for teratoma testis. *Surgery Gynecology & Obstetrics* 1919;28:495-508.
6. Heidenreich A, Pfister D, Witthuhn R, Thüer D, Albers P. Post-chemotherapy retroperitoneal lymph node dissection in advanced testicular cancer: radical or modified template resection. *Eur Urol* 2009;55:217-26. [\[CrossRef\]](#)
7. Beck SD, Foster RS, Bihle R, Donohue, JP, Einhorn LH. Is full bilateral retroperitoneal lymph node dissection always necessary for postchemotherapy residual tumor? *Cancer* 2007;110:1235-40.
8. Janetschek G, Peschel R, Hobisch A, Bartsch G. Laparoscopic retroperitoneal lymph node dissection. *J Endourol* 2001;15:449-55. [\[CrossRef\]](#)
9. Steiner H, Peschel R, Janetschek G, Hörtl L, Berger AP, Bartsch G, et al. Long-term results of laparoscopic retroperitoneal lymph node dissection: a single-center 10-year experience. *Urology* 2004;63:550-5. [\[CrossRef\]](#)
10. Davol P, Sumfest J, Rukstalis D. Robotic-assisted laparoscopic retroperitoneal lymph node dissection. *Urology* 2006;67:199. [\[CrossRef\]](#)
11. Cost NG, DaJusta DG, Granberg CF, Cooksey RM, Laborde CE, Wickiser JE, et al. Robot-assisted laparoscopic retroperitoneal lymph node dissection in an adolescent population. *J Endourol* 2012;26:635-40. [\[CrossRef\]](#)
12. Dogra PN, Singh P, Saini AK, Regmi KS, Singh BG, Nayak B. Robot assisted laparoscopic retroperitoneal lymph node dissection in testicular tumor. *Urol Ann* 2013;5:223-6. [\[CrossRef\]](#)
13. Williams SB, Lau CS, Josephson DY. Initial series of robot-assisted laparoscopic retroperitoneal lymph node dissection for clinical stage I nonseminomatous germ cell testicular cancer. *Eur Urol* 2011;60:1299-302. [\[CrossRef\]](#)
14. Clavien PA, Barkun J, de Oliveira ML, Vauthey JN, Dindo D, Schulick RD, et al. The Clavien-Dindo classification of surgical complications: five-year experience. *Ann Surg* 2009;250:187-96. [\[CrossRef\]](#)

15. Baniel J, Foster RS, Rowland RG, Bihrlé R, Donohue JP. Testis cancer: complications of post-chemotherapy retroperitoneal lymph node dissection. *J Urol* 1995;153:976-80. [\[CrossRef\]](#)
16. Wahle GR, Foster RS, Bihrlé R, Rowland RG, Bennett RM, Donohue JP. Nerve sparing retroperitoneal lymphadenectomy after primary chemotherapy for metastatic testicular carcinoma. *J Urol* 1994;152:428-30. [\[CrossRef\]](#)
17. Hendry WF, A'Hern RP, Hetherington JW, Peckham MJ, Dearnaley DP, Horwich A. Para-aortic lymphadenectomy after chemotherapy for metastatic non-seminomatous germ cell tumours: prognostic value and therapeutic benefit. *Br J Urol* 1993;71:208-13. [\[CrossRef\]](#)
18. Skinner DG, Melamub A, Lieskovsky G. Complications of thoracoabdominal retroperitoneal lymph node dissection. *J Urol* 1982;127:1107-10. [\[CrossRef\]](#)
19. Rassweiler JJ, Seemann O, Henkel TO, Stock C, Frede T, Alken P. Laparoscopic retroperitoneal lymph node dissection for nonseminomatous germ cell tumors: indications and limitations. *J Urol* 1996;156:1108-13. [\[CrossRef\]](#)
20. Palese MA, Su LM, Kavoussi LR. Laparoscopic retroperitoneal lymph node dissection after chemotherapy. *Urology* 2002;60:130-4. [\[CrossRef\]](#)
21. Maldonado-Valadez R, Schilling D, Anastasiadis AG, Sturm W, Stenzl A, Corvin S. Post-chemotherapy laparoscopic retroperitoneal lymph-node dissection in testis cancer patients. *J Endourol* 2007;21:1501-4. [\[CrossRef\]](#)
22. Dudderidge T, Pandian S, Nott D. Technique and outcomes for robotic assisted post-chemotherapy retroperitoneal lymph node dissection in stage 2 nonseminomatous germ cell tumour. *BJU Int* 2012;110:97.
23. Cheney SM, Andrews PE, Leibovich BC, Castle EP. Robot-assisted retroperitoneal lymph node dissection: technique and initial case series of 18 patients. *BJU Int* 2015;115:114-20. [\[CrossRef\]](#)
24. Kamel MH, Littlejohn N, Cox M, Eltahawy EA, Davis R. Post-chemotherapy robotic retroperitoneal lymph node dissection: institutional experience. *J Endourol* 2016;30:510-9. [\[CrossRef\]](#)
25. Singh A, Chatterjee S, Bansal P, Bansal A, Rawal S. Robot-assisted retroperitoneal lymph node dissection: Feasibility and outcome in postchemotherapy residual mass in testicular cancer. *Indian J Urol* 2017;33:304-9. [\[CrossRef\]](#)
26. Baniel J, Foster RS, Gonin R, Messesmer JE, Donohue JP, Einhorn LH. Late relapse of testicular cancer. *J Clin Oncol* 1995;13:1170-6. [\[CrossRef\]](#)
27. Pearce SM, Golan S, Gorin MA, Luckenbaugh AN, Williams SB, Ward JF, et al. Safety and early oncologic effectiveness of primary robotic retroperitoneal lymph node dissection for nonseminomatous germ cell testicular cancer. *Eur Urol* 2017;71:476-82. [\[CrossRef\]](#)
28. Stepanian S, Patel M, Porter J. Robot-assisted laparoscopic retroperitoneal lymph node dissection for testicular cancer: evolution of the technique. *Eur Urol* 2016;70:661-7. [\[CrossRef\]](#)